



Efficacy of Black Mulberry Mouthwash for Prevention of Chemotherapy-Induced Oral Mucositis: A Double-Blind Randomized Clinical Trial

Anahita Ghorbani¹, Zahra Ghasemzadeh², Seyed Mohammad Mehdi Ghaffari Hamedani³, Jafar Akbari⁴, Mahmood Moosazadeh⁵, Fatemeh Mirzaee⁶, Maryam Zamanzadeh⁷, Somayeh Shahani^{6,8*}

1. Department of Oral and Maxillofacial Medicine, Dental Research Center, Faculty of Dentistry, Mazandaran University of Medical Sciences, Sari, Iran
2. Department of Restorative Dentistry and Endodontics, School of Dentistry, North Khorasan University of Medical Sciences, Bojnord, Iran.
3. Department of Surgery, Faculty of Medicine, Mazandaran University of Medical Sciences, Sari, Iran
4. Department of Pharmaceutics, Faculty of Pharmacy, Mazandaran University of Medical Sciences, Sari, Iran
5. Gastrointestinal Cancer Research Center, Non-communicable Diseases Institute, Mazandaran University of Medical Sciences, Sari, Iran
6. Medicinal Plants Research Center, Institute of Herbal Medicines and Metabolic Disorders, Mazandaran University of Medical Sciences, Sari, Iran
7. Department of Oral and Maxillofacial Pathology, Dental Research Center, Faculty of Dentistry, Mazandaran University of Medical Sciences, Sari, Iran
8. Department of Pharmacognosy and Biotechnology, Faculty of Pharmacy, Mazandaran University of Medical Sciences, Sari, Iran

Article Info

Article type:
Original Article

Article History:

Received: 09 Feb 2024
Accepted: 29 Jul 2024
Published: 07 Mar 2025

* Corresponding author:

Department of Pharmacognosy and Biotechnology, Faculty of Pharmacy, Mazandaran University of Medical Sciences, Sari, Iran

E-mail: so.shahani@yahoo.com

ABSTRACT

Objectives: Oral mucositis is a common side effect of cancer chemotherapy. Traditionally, black mulberry or *Morus nigra* L. (*M. nigra*) fruit is used for treatment of oral inflammatory conditions. The aim of the present study was to evaluate the efficacy of black mulberry mouthwash for prevention of oral mucositis caused by 5-fluorouracil.

Materials and Methods: This double-blind clinical trial was performed on 62 patients with colon adenocarcinoma undergoing chemotherapy with 5-fluorouracil. The patients were randomly divided into two groups (n=31) to receive 10mL of 1% black mulberry juice (BMJ) or the placebo mouthwash, 3 times a day for 2 weeks. The patients were followed up for 7 and 14 days after the treatment onset to record the degree of mucositis according to the World Health Organization (WHO) criteria. Spectrophotometric assays were conducted for quantitative analysis of the bioactive compounds in the composition of BMJ. Data were analyzed with the Chi-square and Fisher's exact tests ($\alpha=0.05$).

Results: The severity of oral mucositis was slightly, but not significantly, lower in the follow-up sessions in the BMJ mouthwash group ($P>0.05$). The total anthocyanin content of the BMJ was calculated to be 506.5 ± 3.51 and 476.2 ± 7.99 mg cyanidin 3-glucoside equivalent per 100g of dried juice, before and after the sterilization process, respectively.

Conclusion: The present results showed that the BMJ mouthwash can be effective as an adjunct treatment to reduce the incidence and severity of mucositis in patients undergoing chemotherapy. Anthocyanins appear to be mainly involved in the observed effect.

Keywords: Morus; Mouthwashes; Mucositis; Adenocarcinoma; Fluorouracil

- **Cite this article as:** Ghorbani A, Ghasemzade Z, Ghaffari Hamedani SMM, Akbari J, Moosazadeh M, Mirzaee F, et al. Efficacy of Black Mulberry Mouthwash for Prevention of Chemotherapy-Induced Oral Mucositis: A Double-Blind Randomized Clinical Trial. *Front Dent.* 2025;22:10. <https://doi.org/10.18502/ffd.v22i10.18214>

INTRODUCTION

Oral mucositis commonly occurs in patients undergoing chemotherapy, especially those receiving a 5-fluorouracil-based treatment although patient-related factors such as poor oral hygiene, microbial infections, and impaired salivary function are also involved in this process [1]. Oral complications of chemotherapy especially mucositis (inflammation and ulceration of the oral mucosa) usually appear 7 to 10 days after the initiation of therapy [2]. The most common side effects of mucositis include severe pain, local and systemic infection, oropharyngeal disorders, and mouth bleeding that adversely affect the patient's quality of life. These manifestations may increase the hospitalization period and treatment costs [3]. The current clinical management of oral mucositis focuses primarily on palliative care strategies, which include pain management, nutritional support, and control of infection and bleeding [3]. A number of local and systemic agents have been investigated to prevent or decrease chemotherapy-induced oral mucositis such as cryotherapy, laser therapy, chlorhexidine, amifostine, hematological growth factors, pentoxifylline, glutamine, and sucralfate [1]. However, there is no generally accepted treatment for oral mucositis [4]. Considering the importance of this complication, it is necessary to find new remedies for its management. In recent years, medicinal plants have been considered for prevention and treatment of mucositis [5].

Morus nigra L. (*M. nigra*) from the Moraceae family, known as the black mulberry, is a flowering plant distributed throughout the Mediterranean countries, Asia, Europe, South America, and Africa [6]. This plant originates in Iran [7]. The fruit is used not only for its nutritional value and special taste, but also for various therapeutic purposes in folk and traditional medicine. The fruits are consumed fresh or as processed products such as juice, marmalade, and beverages [8]. The *Morus* species are traditionally used for enhancement of wound healing and resolution of inflammatory conditions [9,10].

According to the Turkish traditional medicine, *M. nigra* is effective for healing of oral ulcers and the fruit molasses are used for treatment of oral mucositis [11]. In the Chinese medicine, the mulberry fruit is used for prevention of inflammatory diseases such as arthritis [12] and cardiovascular disorders [13]. The traditional use of *M. nigra* by Iranians for resolution of pain and oral mucosal inflammation has also been well documented [14]. Previous studies demonstrated the optimal anti-oxidative [15], anti-inflammatory [7], antimicrobial [16] and wound healing [17] properties of *M. nigra*. Various bioactive compounds mainly anthocyanins and flavonoids have been isolated from the fruits of this plant [9].

Due to the possible efficacy of *M. nigra* for enhancement of wound healing and resolution of oral inflammatory conditions in traditional medicine, this study aimed to investigate the efficacy of black mulberry juice (BMJ) for prevention of oral mucositis in patients with colon adenocarcinoma undergoing chemotherapy with 5-fluorouracil.

MATERIALS AND METHODS

Plant material:

Black mulberry fruits were collected from Kan district, Tehran, Iran. A voucher specimen (E1-14-221) was deposited at the herbarium of the Faculty of Pharmacy, Mazandaran University of Medical Sciences, Sari, Iran. The fruits juice was prepared by filtering the crushed fruits, and dried by a freeze-dryer (Zirbus, Germany). The BMJ was standardized based on total anthocyanin content, as the major active compound according to a previous study [15]. An ultrasonic probe sonicator was used for sterilization of the fruit juice. Ultrasound-based sterilization is one of the suitable techniques for processing of fruit and vegetable juices, with minimal effect on key compounds of the sample compared to thermal techniques [18,19].

Quantitative analysis:

Determination of the total anthocyanin content:

The total anthocyanin content was assessed using the pH differential spectroscopic method

[20] and expressed as milligrams of cyanidin 3-O-glucoside equivalent per 100g of the sample.

Total phenolic and flavonoid contents:

The total phenolic content of the BMJ was measured using the Folin-Ciocalteu method, while the total flavonoid content was determined by the aluminum chloride assay [21,22]. Calibration curves were drawn using a range of gallic acid and quercetin concentrations (6.25-200µg/mL).

Mouthwash preparation:

The mouthwash was prepared by dissolving the dried BMJ (1% w/v) in a suitable solvent system containing 6% (v/v) glycerin, 8% (v/v) ethanol, and 84.7% (v/v) water, which was preserved with 0.2% (w/v) methyl paraben and 0.1% (w/v) sodium benzoate. The physical stability of the prepared products at three temperatures (4°C, 25°C, and 40°C) during a two-week period was investigated. The mouthwashes were evaluated for possible microbial contamination based on the United States Pharmacopeia [23].

Trial design:

This randomized double-blind clinical trial was conducted on cancer patients with stage 3 or 4 colon adenocarcinoma undergoing chemotherapy with 5-fluorouracil regimen every 3 weeks, 2 days in a row in each cycle, referring to Imam-Khomeini Hospital and Tooba Dental Clinic in Sari, Iran. The procedures conducted on human participants in this study adhered to the guidelines of the Declaration of Helsinki and were approved by the Ethics Committee of Mazandaran University of Medical Sciences, Sari, Iran (approval code IR. MAZUMS.REC.96.2979). The trial protocol was registered in the Iranian Registry of Clinical Trials (registration ID: IRCT2017070234857N1). All patients signed informed consent forms prior to their enrollment.

Eligibility criteria:

The inclusion criteria were complete consciousness, oral mucosal health, no autoimmune disease, no intake of narcotics or alcohol, no cigarette smoking, and no use of other mouthwashes during the study. The exclusion criterion was no or poor adherence to the correct use of mouthwash. Before the study onset, the patients were briefed about the correct use of mouthwash.

Sample size:

The sample size was calculated according to the results of a previous study by Ashktorab et al [24]. In the aforementioned study, the incidence of mucositis in the intervention and placebo groups was 15% and 50%, respectively. Considering these values, a confidence interval of 95%, a power of 80%, the two-tailed hypothesis test, using the comparison formula between two ratios, and using G-Power software, the sample size was determined to be 54 patients (27 patients in the intervention group and 27 patients in the placebo group), which was increased to 66 patients after accounting for 20% attrition.

Randomization and blinding:

The patients were randomly divided into two groups (n=31): The intervention group receiving 1% BMJ mouthwash and the placebo group receiving saline. Randomization was performed using a table of random numbers. The mouthwashes were coded A (BMJ) and B (saline), and the clinician and patients were not aware of their contents.

Interventions and outcomes:

All the patients were instructed to gargle 10 mL of the mouthwash 3 times a day (after breakfast, after lunch, and before sleep after tooth brushing), starting from the first day of chemotherapy until 14 days after chemotherapy. The patients were instructed not to use any other mouthwash during the treatment. The oral mucosal status of the patients in the first day of chemotherapy, and at the end of the first and second weeks after the onset of chemotherapy was evaluated by a clinician through observation and interview, and recorded in a questionnaire [24]. Clinical examination for evaluation of oral mucositis was performed based on the index provided by the World Health Organization (WHO). Accordingly, the results were reported in five categories (0 = no mucositis, 1 = erythema, no wound, no blush, no pain, no sensitivity, 2 = erythema, blush, wound, somehow able to eat solid food, 3 = ulcer but fluid diet required, 4 = no possibility of feeding).

Statistical analysis:

Data analyses were performed using SPSS version 25 (SPSS Inc., IL, USA). All data were

expressed as percentage (%) and median (Q1-Q3). The Chi-square and Fisher’s exact tests were used to compare the groups regarding gender, smoking status, educational level, frequency of oral mucositis based on grade, and incidence of oral mucositis. The median age was compared between the groups by the Mann-Whitney test. The significance level was set at $P < 0.05$.

RESULTS

Participant flow:

During the study, four patients declined to continue. Therefore, 62 patients were included in this study and were divided into

the intervention and placebo groups. Figure 1 shows the CONSORT flow-diagram of patient selection and allocation.

Statistical analysis was performed on 62 patients, 31 in the intervention group and 31 in the placebo group. In the intervention group, there were 16 (51.6%) females and 15 (48.4%) males, and in the placebo group, there were 17 (54.8%) females and 14 (45.2%) males. Overall, 53.2% of the patients were females and 46.8% were males. The two groups had no significant differences in terms of age, smoking, or educational level. Demographic characteristics of the patients are presented in Table 1.

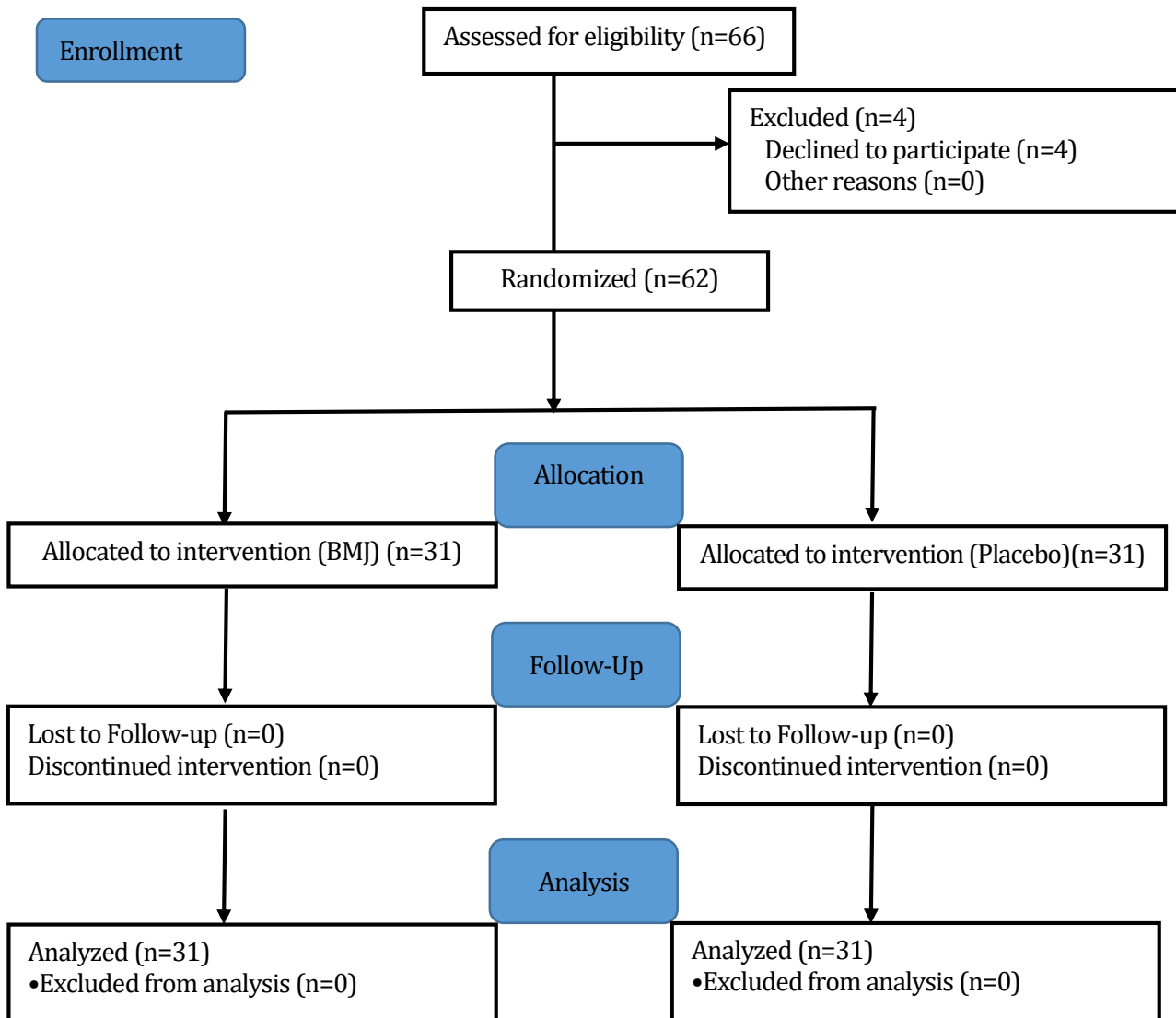


Fig. 1. CONSORT flow-diagram of the study

Table 1. Demographic information of cancer patients in the black mulberry juice (BMJ) and placebo groups

Variable	BMJ	Placebo	P value ^b
Sex			0.799
Male	15(48.4)	14(45.2)	
Female	16(51.6)	17(54.8)	
Age (yrs.)^a	53(42-61)	56(44-63)	0.473
Smoking			0.641
Yes	3(9.7)	2(6.5)	
No	28(90.3)	29(93.5)	
Education level			1.000
Illiterate	9(29.0)	9(29.0)	
Literate	22(71.0)	22(71.0)	

^aThe age data is expressed as median (Q1-Q3) and the others are presented as n (%). ^b The P value for age data is based on Mann-Whitney test and the other P values are based on Chi-square test.

Harms:

No side effects were reported after using the mouthwash.

Evaluation of oral mucositis:

Based on initial examination (before the treatment onset), the severity of oral mucositis was zero.

Assessment of oral mucositis based on the WHO criteria was performed at the end of each week from the onset of treatment in both groups. During the 2 weeks of treatment with the BMJ mouthwash, the grade of oral mucositis was lower in the BMJ group, but it was not statistically significant compared to the placebo group ($P > 0.05$). Based on Table 2, the decrease in the severity of mucositis was evident in both groups during the study period.

Table 2. Comparison of the oral mucositis grade in black mulberry juice (BMJ) and placebo groups during the first and second follow-ups^a

Grade	Day 7		Day 14	
	BMJ	Placebo	BMJ	Placebo
0	13(41.9)	9(29.0)	20(64.5)	13(41.9)
1	10(32.3)	8(25.8)	9(29.0)	9(29.0)
2	7(22.6)	11(35.5)	2(6.45)	8(25.8)
3	1(3.2)	3(9.7)	0	1(3.2)
P value^b	0.497		0.085	

^a All data is presented as n (%). ^b P value-Fisher's exact test

No significant difference was found in the incidence of oral mucositis between the BMJ and placebo groups in the first or second follow-ups ($P > 0.05$, Table 3).

Table 3. Comparison of the incidence of mucositis in black mulberry juice (BMJ) and placebo groups during the first and second follow-ups^a

Day	BMJ	Placebo	P value ^b
7	18 (58.1)	22 (71)	0.288
14	11 (35.45)	18 (58)	0.075

^a All data is presented as n (%) which referred to the patients with no evidence of oral mucositis. ^b Chi-square test

Quantitative analysis:

The total content of anthocyanin in the BMJ was measured before and after the sterilization process which changed from 506.5 ± 3.51 mg to 476.2 ± 7.99 mg cyanidin 3-glucoside equivalent/100g dried juice.

The total phenol content was calculated to be 19.24 ± 0.16 mg gallic acid ($y = 0.009x + 0.0888$, $R^2 = 0.9997$) equivalent per 1 g of dried juice. The total flavonoid content was calculated to be 3.45 ± 0.72 mg quercetin ($y = 0.0049x + 0.054$, $R^2 = 0.9989$) equivalent per 1g of dried juice.

DISCUSSION

In recent years, natural resources especially medicinal plants with anti-inflammatory and wound healing properties have been considered for prevention or reducing the symptoms of radiation-induced oral mucositis, and previous studies have shown the beneficial effects of these resources on amelioration of radiation-induced oral mucositis [25,5]. Black mulberry is native to Iran, and is one of the valuable plant species that grows in the Mediterranean countries [26]. Black mulberry fruit is known for its pleasant taste, and nutritional and medicinal values [8]. The present study showed that the BMJ mouthwash may be effective as an adjuvant treatment to reduce the incidence and severity of oral mucositis in patients with colon adenocarcinoma under chemotherapy with 5-fluorouracil, although according to the statistical analysis performed in this

study, its effectiveness was not significant compared to saline.

Recently, several studies evaluated the therapeutic effect of *M. nigra* on mucositis in patients undergoing chemotherapy [27,28]. The optimal effectiveness of black mulberry syrup for prevention of oral mucositis in cancer patients undergoing stem cell transplantation was reported by Harman et al [27]. Based on the WHO scoring system for assessment of oral mucositis, they reported that the severity of mucositis significantly decreased at 14 and 21 days after chemotherapy in patients who gargled the syrup, but there was no significant difference in the severity of oral mucositis between the test and control groups during the first week after chemotherapy [27]. A similar observation was reported by Doğan et al, [28] who investigated the effectiveness of black mulberry molasses for prevention of oral mucositis in cancer patients undergoing radiotherapy. They reported that none of the patients experienced oral mucositis in the first week of treatment. Gargling the black mulberry molasses during radiotherapy resulted in a reduction in the incidence and severity of oral mucositis in the intervention group [28]. A recent study evaluated the therapeutic potential of *M. nigra* for gastrointestinal mucositis induced by 5-fluorouracil in an animal model. Oral administration of the fruit extract to rats reduced the inflammation and mucosal degeneration of the intestines [29]. It has been shown that the protective effects of medicinal plants against radiation-induced oral mucositis are mainly related to their anti-inflammatory, antioxidant, antimicrobial, and analgesic effects [5].

Akkol et al. [17] reported that the *M. nigra* fruits possess notable wound healing properties in incision and excision wound models; moreover, the fruit extract showed strong radical scavenging and ferric ion reducing antioxidant activity in 2,2-diphenyl-1-picrylhydrazyl and ferric reducing antioxidant power assays [15]. The antinociceptive and anti-inflammatory activities of black mulberry fruits have been

investigated as well. Chen et al. [7] reported that the inhibitory activities of the mulberry fruit on xylene-induced ear edema and carrageenan-induced paw edema in mice were mainly related to the scavenge or inhibition of the pro-inflammatory cytokines such as interleukin1 β , tumor necrosis factor- α , and interferon- γ in the serum of mice [7].

The painful lesions of oral mucositis are often colonized by microbial agents in the third stage and compromise nutrition and oral hygiene and increase the risk of local and systemic infections [3]. Previously, the antibacterial activity of the fruit extract of *M. nigra* was evaluated against three inflammatory pain-causing bacteria namely *Escherichia coli*, *Pseudomonas aeruginosa*, and *Staphylococcus aureus*, and the flavonoid-rich extract strongly inhibited all three strains [30].

It should be noted that gargling saline is the common basic oral care protocol which can relieve some of the symptoms of oral mucositis especially pain in patients undergoing chemotherapy [31,32]. In this regard, in the present study, the placebo group received saline, which resulted in some degrees of improvement.

In the present study, spectrophotometric analysis was performed for measurement of the anthocyanin content of the BMJ. The total anthocyanin content of the juice after the sterilization process was measured to be 476.2 ± 7.99 mg cyanidin 3-glucoside equivalent per 100 g dried juice. Similar to the present result, it has been reported that sonication has only minor effects on the anthocyanin content of blackberries [33]. According to Tomas et al, [34] the anthocyanin content of the black mulberry fruit was 444 ± 43 mg cyanidin 3-glucoside equivalent per 100g dried juice as determined by the pH differential method. In previous studies, the main anthocyanin of black mulberry was reported to be cyanidin-3-glucoside [34,35]. It has been suggested that this compound may be beneficial for prevention of inflammatory diseases. Pergola et al. [36] showed the inhibition of nitric oxide biosynthesis by cyanidin-3-O-glucoside as the main anthocyanin compound in blackberry.

Morais et al. [37] mentioned that phenolic compounds especially anthocyanins have potential anti-inflammatory effects exerted mainly through down-regulation of transcription factor NF κ B signaling pathway. In agreement with these findings, it is highly probable that *M. nigra* fruit juice promotes the resolution of oral mucositis in cancer patients by prevention of inflammatory processes due to its phenolic compounds especially anthocyanins.

CONCLUSION

In the present study, the mouthwash containing BMJ decreased the incidence and severity of mucositis in patients undergoing chemotherapy with 5-fluorouracil, although it was not significant compared to the saline group. Presence of phenolic compounds especially anthocyanins in black mulberry fruit can be responsible for the observed effect due to their anti-inflammatory and antioxidant potential. It seems that products derived from the black mulberry fruit may be helpful for prevention and treatment of oral mucositis.

ACKNOWLEDGMENTS

This study was financially supported by Mazandaran University of Medical Sciences, Sari, Iran (grant No.2979).

CONFLICT OF INTEREST STATEMENT

None declared.

REFERENCES

1. Saadeh CE. Chemotherapy-and radiotherapy-induced oral mucositis: Review of preventive strategies and treatment. *Pharmacotherapy*. 2005 Apr;25(4):540-54.
2. Naidu MUR, Ramana GV, Rani PU, Suman A, Roy P. Chemotherapy-induced and/or radiation therapy-induced oral mucositis-complicating the treatment of cancer. *Neoplasia*. 2004 Sep;6(5):423-31.
3. Rajesh V Lalla STS, Duoglas E peterson. Management of oral mucositis in patients with cancer. *Dent Clin North Am*. 2008 Jan;52(1):61-8.
4. Lionel D, Christophe L, Marc A, Jean-Luc C. Oral mucositis induced by anticancer treatments: physiopathology and treatments. *Ther Clin Risk Manag*. 2006 Jun;2(2):159-68.

5. Nagi R, Patil DJ, Rakesh N, Jain S, Sahu S. Natural agents in the management of oral mucositis in cancer patients-systematic review. *J Oral Biol Craniofac Res*. 2018 Sep;8(3):245-54.
6. Okatan V, Polat M, Askin MA. Some physico-chemical characteristics of Black mulberry (*Morus nigra* L.) in Bitlis. *Sci Papers Ser B Hort*. 2016;60:27-30.
7. Chen H, Pu J, Liu D, Yu W, Shao Y, Yang G, et al. Anti-inflammatory and antinociceptive properties of flavonoids from the fruits of black mulberry (*Morus nigra* L.). *PloS one*. 2016 Apr;11(4):e0153080.
8. Darias-Martín J, Lobo-Rodrigo G, Hernández-Cordero J, Díaz-Díaz E, Díaz-Romero C. Alcoholic beverages obtained from black mulberry. *Food Sci Biotechnol*. 2003 Jun;41(2):173-6.
9. Hussain F, Rana Z, Shafique H, Malik A, Hussain Z. Phytopharmacological potential of different species of *Morus alba* and their bioactive phytochemicals: A review. *Asian Pac J Trop Biomed*. 2017 Oct;7(10):950-6.
10. Rodrigues EL, Marcelino G, Silva GT, Figueiredo PS, Garcez WS, Corsino J, et al. Nutraceutical and medicinal potential of the *Morus* species in metabolic dysfunctions. *Int J Mol Sci*. 2019 Jan;20(2):301.
11. Zhang Q-Y, Wang F-X, Jia K-K, Kong L-D. Natural product interventions for chemotherapy and radiotherapy-induced side effects. *Front Pharmacol*. 2018 Nov;9:1253.
12. Mandal A. Nutraceutical and Medicinal Property of Mulberry Fruits: A Review on Its Pharmacological Potential. *Preprints*. 2020; 2020040105.
13. Huang HP, Ou TT, Wang CJ. Mulberry (*sang shèn zǐ*) and its bioactive compounds, the chemoprevention effects and molecular mechanisms in vitro and in vivo. *J Tradit Complement Med*. 2013 Jan;3(1):7-15.
14. Eslami Farouji A, Khodayari H. Ethnomedicinal plants of Farouj district, North Khorasan province, Iran. *J Herb Med*. 2016;7(1):21-36.
15. Kim I, Lee J. Variations in anthocyanin profiles and antioxidant activity of 12 genotypes of mulberry (*Morus* spp.) fruits and their changes during processing. *Antioxidants*. 2020 Mar;9(3):242.
16. Zhou R, Li D, Kou Q, Jiao Z, Ning Z. Evaluation of anti-inflammatory, antimicrobial and wound healing activity of *Morus nigra*. *S Afr J Bot*. 2019 Aug;124:540-5.
17. Akkol EK, Süntar I, Keleş H, Sezik E, Gürler G. Bioassay-guided isolation and

- characterization of wound healer compounds from *Morus nigra* L.(Moraceae). *Rec Nat Prod*. 2015 Oct;9(4):123-7.
18. Khandpur P, Gogate PR. Evaluation of ultrasound based sterilization approaches in terms of shelf life and quality parameters of fruit and vegetable juices. *Ultrason Sonochem*. 2016 Mar;29:337-53.
 19. Tiwari B, O'donnell C, Cullen P. Effect of non thermal processing technologies on the anthocyanin content of fruit juices. *Trends Food Sci Technol*. 2009 Apr; 20(3-4):137-45.
 20. Lee J, Durst RW, Wrolstad RE. Determination of total monomeric anthocyanin pigment content of fruit juices, beverages, natural colorants, and wines by the pH differential method: collaborative study. *J AOAC Int*. 2005 Sep;88(5):1269-78.
 21. Makkar HPS, Blummel M, Borowy NK, Becker K. Gravimetric determination of tannins and their correlations with chemical and protein precipitation methods. *J Sci Food Agric*. 1993;61(2):161-5.
 22. Sembiring EN, Elya B, Sauriasari R. Phytochemical screening, total flavonoid and total phenolic content and antioxidant activity of different parts of *Caesalpinia bonduc* (L.) Roxb. *Pharmacogn*. 2018;10(1): 123-7.
 23. Chmhete PN, Machona O, Mangoyi R. Preparation of an antibacterial herbal mouthwash Containing extract of *Erythrina Abyssinica*. *Global J Res Dent Sci*. 2021 Nov;1(3):67-72.
 24. Ashktorab T, Yazdani Z, Mojab F, Majd HA, Madani H. Preventive effects of an oral rinse peppermint essence on chemotherapy-induced oral mucositis. *Koomesh*. 2010 Sep;12(1):8-13.
 25. Kong M, Hwang DS, Yoon SW, Kim J. The effect of clove-based herbal mouthwash on radiation-induced oral mucositis in patients with head and neck cancer: a single-blind randomized preliminary study. *Onco Targets Ther*. 2016 Jul 22;9:4533-8.
 26. Kamiloglu S, Serali O, Unal N, Capanoglu E. Antioxidant activity and polyphenol composition of black mulberry (*Morus nigra* L.) products. *J Berry Res*. 2013 Jan;3(1):41-51.
 27. Harman M, Ovayolu N, Ovayolu O. The effect of three different solutions on preventing oral mucositis in cancer patients undergoing stem cell transplantation: a non-randomized controlled trial: A Turkish study-non-randomized trial. *J Pak Med Assoc*. 2019;69(6):811-6.
 28. Doğan MD, Can G, Meral R. Effectiveness of black mulberry molasses in prevention of radiotherapy-induced oral mucositis: a randomized controlled study in head and neck cancer patients. *J Altern Complement Med*. 2017 Dec;23(12):971-9.
 29. Yiğitaslan S, Özkaraman A, Açıkğöz A, Alparslan GB, Toprak Ç, Göger F, et al. Therapeutic potential of *Morus nigra* on 5-fluorouracil-induced gastrointestinal mucositis in rats. *Osmangazi Tıp Dergisi*. 2020 Mar;24(4):363-72.
 30. Chen H, Yu W, Chen G, Meng S, Xiang Z, He N. Antinociceptive and antibacterial properties of anthocyanins and flavonols from fruits of black and non-black mulberries. *Molecules*. 2017 Dec;23(1):4.
 31. Naibaho EN, Dharmajaya R, Harahap IA. Effectiveness of oral care using normal saline and baking soda towards pain and comfort in mucositis patients undergoing chemotherapy. *Indian J Public Health Res Dev*. 2020 Oct;11(10):222-8.
 32. Hashemi A, Bahrololoumi Z, Khaksar Y, Saffarzadeh N, Neamatzade H, Foroughi E. Mouth-rinses for the prevention of chemotherapy induced oral mucositis in children: a systematic review. *Iran J Ped Hematol Oncol*. 2015;5(2):106-12.
 33. Weber F, Larsen LR. Influence of fruit juice processing on anthocyanin stability. *Food Res Int*. 2017 Oct;100(Pt 3):354-365.
 34. Tomas M, Toydemir G, Boyacioglu D, Hall R, Beekwilder J, Capanoglu E. The effects of juice processing on black mulberry antioxidants. *Food chem*. 2015 Nov;186:277-84.
 35. Hassimotto N, Genovese M, Lajolo F. Identification and characterisation of anthocyanins from wild mulberry (*Morus nigra* L.) growing in Brazil. *Food Sci Technol Int*. 2007 Feb;13(1):17-25.
 36. Pergola C, Rossi A, Dugo P, Cuzzocrea S, Sautebin L. Inhibition of nitric oxide biosynthesis by anthocyanin fraction of blackberry extract. *Nitric oxide*. 2006 Aug;15(1):30-9.
 37. Morais CA, de Rosso VV, Estadella D, Pisani LP. Anthocyanins as inflammatory modulators and the role of the gut microbiota. *J Nutr Biochem*. 2016 Jul; 33:1-7.