

# Comparison of Implant Stability Using Resonance Frequency Analysis: Osteotome versus Conventional Drilling

Rokhsareh Sadeghi<sup>1</sup>, Amir Reza Rokn<sup>2</sup>✉, Asghar Miremadi<sup>3</sup>

<sup>1</sup>Assistant Professor, Department of Periodontics, Faculty of Dentistry, Shahed University, Tehran, Iran

<sup>2</sup>Professor, Dental Implant Research Center, Dentistry Research Institute, Tehran University of Medical Sciences, Tehran, Iran; Department of Periodontics, Faculty of Dentistry, Tehran University of Medical Sciences, Tehran, Iran

<sup>3</sup>Associate Professor, Department of Periodontics, School of Dentistry, Tehran University of Medical Sciences, Tehran, Iran

## Abstract:

**Objectives:** Implant primary stability is one of the important factors in achieving implant success. The osteotome technique may improve primary stability in patients with poor bone quality. The aim of this study was to compare implant stability using two different techniques namely osteotome versus conventional drilling in the posterior maxilla.

**Materials and Methods:** In this controlled randomized clinical trial, 54 dental implants were placed in 32 patients; 29 implants were placed in the osteotome group and 25 in the conventional drilling group. Implant stability was assessed at four time intervals namely at baseline, one, two and three months after implant placement using resonance frequency analysis (RFA).

**Results:** Primary stability based on implant stability quotient (ISQ) units was  $71.4 \pm 7$  for the osteotome group and  $67.4 \pm 10$  for the control group. There was no statistically significant difference between the two groups in implant stability at any of the measurement times. In each group, changes in implant stability from baseline to one month and also from two months to three months post-operatively were not significant but from one month to two months after implant placement, implant stability showed a significant increase in both groups.

**Conclusion:** The results of this study revealed that in both techniques, good implant stability was achieved and osteotome technique did not have any advantage compared to conventional drilling in this regard.

**Keywords:** Dental Implants; Bone; Maxilla; Osteotomy

*Journal of Dentistry, Tehran University of Medical Sciences, Tehran, Iran (2015; Vol. 12, No. 9)*

✉ Corresponding author:

AR. Rokn, Dental Implant Research Center, Dentistry Research Institute, Tehran University of Medical Sciences, Tehran, Iran; Department of Periodontics, Faculty of Dentistry, Tehran University of Medical Sciences, Tehran, Iran

arrokn@yahoo.com

Received: 21 January 2015

Accepted: 27 May 2015

## INTRODUCTION

Dental implants are increasingly used since they have a high success rate in replacement of missing teeth. Primary stability has been identified as a fundamental criterion to achieve osseointegration [1,2] and may be obtained by macro-retention or friction of the implant within its prepared site [3]. Primary stability depends on the bone quantity, implant macro and micro-design and surgical technique [4,5].

According to Lekholm and Zarb (1985), bone quality falls into one of four categories: I, II, III and IV [6]. When the bone in the implant site is soft and trabecular (type IV), it is often difficult to obtain good anchorage and primary stability [6-8]. Local improvement of bone quality has been reviewed in the literature [9,10]. It has been suggested that the osteotome technique, which was introduced by Summers [11-14] could increase primary stability of dental

implants in poor quality bone. Posterior maxilla with mostly types III and IV bone quality is best suited for trabecular compaction with the osteotome technique [15]. By this technique, type IV bone can be changed into type III or II, and type III can be compacted to type II [15]. This implant site preparation method involves the use of a special set of hand instruments that compress trabecular bone laterally and apically, instead of removing bone [15]. Several studies have been compared to the osteotome technique with other methods of implant bed preparation in achieving primary stability. Some studies have demonstrated that the osteotome technique resulted in lower or similar implant stability, when compared to conventional drilling or undersize preparation [4,16-18], some others have shown better results with the osteotome technique [19-21]. Nkneke et al, in 2002 showed an increase in bone-implant contact in their histologic and histomorphometric animal study, but the stability of implants placed in this condensed bone was not reported [10]. The results of the available studies are conflicting and also the number of clinical

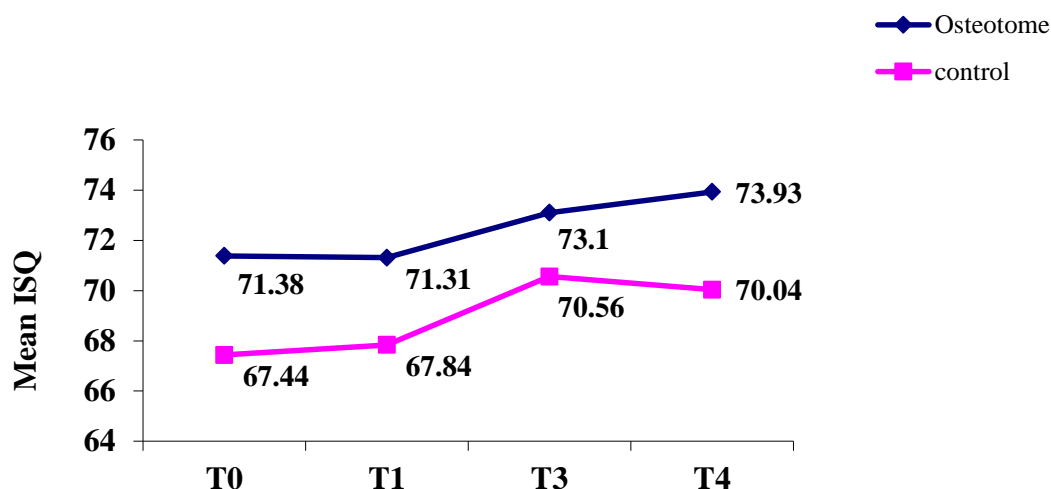
studies is limited. Therefore, the aim of the present clinical study was to compare two surgical techniques for implant bed preparation in achieving implant stability in the posterior maxilla namely the osteotome and conventional drilling. Resonance frequency analysis was used to evaluate implant stability at the time of placement and also during the healing phase.

## MATERIALS AND METHODS

The study group of this randomized controlled clinical trial consisted of 32 patients (16 women and 16 men) with an age range of 30-66 years (mean age of  $52.85 \pm 8.89$  years) seeking implant therapy at the Departments of Implantology, Faculty of Dentistry, Shahed University and Tehran University of Medical Sciences, Iran. The sample size of this study was determined based on the data obtained from the study by Buchter et al, [4], considering 95% confidence interval and 80% power of study. Subjects with the following criteria were included in this study: (I) Posterior maxillary missing tooth/teeth and (II) Minimum of 10mm ridge height and 6mm width.

**Table 1.** Information about patients and implants

Variables	Osteotome	Control
<b>Gender</b>		
Female	10(52.6%)	6(46.2%)
Male	9(47.4%)	7(53.8%)
<b>Age</b>		
Mean( $\pm$ SD)	52.3( $\pm$ 8.77)	53.4( $\pm$ 8.89)
Range	30-65	42-66
<b>Implant site</b>		
First premolar	4(13.8%)	7(28.0%)
Second premolar	9(31%)	8(32.0%)
First molar	10(34.5%)	5(20.0%)
Second molar	6(20.7%)	5(20.0%)
<b>Implant width</b>		
4.1 mm	18(62.1%)	21(84%)
4.8 mm	11(37.9%)	4(16%)
<b>Implant length</b>		
10	16(55.2%)	13(52%)
12	13(44.8%)	12(48%)



**Diagram 1.** Implant stability changes from insertion (T0) to three months post-surgery (T3)

The exclusion criteria were: (I) Systemic diseases that affect host healing responses, (II) Heavy smoking (more than 10 cigarettes per day), (III) Need for bone grafting and sinus lifting and (IV) Poor oral hygiene.

This study was approved by the Ethics Committee of Shahed University and registered at [www.IRCT.ir](http://www.IRCT.ir) (IRCT201405 27462 1N2). The treatment protocol was explained to all patients and written informed consents were obtained from them.

The patients, who had the criteria to participate in the study, were randomly enrolled in two groups: the osteotome or test group and the conventional drilling or control group. Random allocation sequence was generated by RAS (Random Allocation Software). Patients were allocated to osteotome or conventional drilling groups by a person not involved in the main research.

A simple random list contained case and control subjects with a unique identification code prepared by a statistician.

A total of 54 Straumann tissue level SLA ITI dental implants (Institut Straumann AG, Waldenburg, Switzerland) with a length of 10 or 12mm and diameter of 4.1 or 4.8mm were placed in 32 patients.

The osteotome group consisted of 29 implants placed in 19 patients and the control group included 25 implants in 13 patients. All surgeries were performed under local anesthesia. After appropriate incision was made, full-thickness buccal and palatal mucoperiosteal flaps were reflected. In the control group, implant site preparation was performed by round, pilot and spiral drills to reach the final diameter according to the manufacturer's standard protocol (Institut Straumann AG, Waldenburg, Switzerland).

In the test group, implant beds were prepared first by round drills, 2.2mm diameter pilot drill, and then by a series of osteotomes with increasing diameters until the final width and depth were obtained (Osteotome kit, Straumann, Waldenburg, Switzerland).

Bone quality was assessed based on the surgeon's perception of bone resistance during drilling and implant placement. Implants were placed in a non-submerged or one-stage manner then soft tissues were closed using figure C (single) sutures. Post-surgical instructions consisted of amoxicillin (500mg tid for one week), acetaminophen (500mg qid) and chlorhexidine digluconate mouthwash (0.12% twice daily for two weeks).

No provisional prosthesis was used during the observation period. Implant stability was measured at the time of implant placement and at one, two, and three months after the operation, using RFA method. For this purpose, Osstell mentor device (Integration Diagnostics AB, Savadale, Sweden) was used. The scale of measurement was ISQ with a value from 1 to 100. A smart peg for Straumann implant (type 4) was screwed into implants and ISQ was measured from three different directions of mesiobuccal, distobuccal and palatal at each observation time point. A mean ISQ value was calculated for each measurement time.

#### Statistical analysis:

The SPSS statistical software program (SPSS Inc., Chicago, IL, USA) was used for statistical analysis. The implant was considered as a statistical unit. The normal distribution of data was assessed using the Kolmogorov-Smirnov test. Descriptive statistics were reported for implant size, location, and ISQ. For comparison of stability between test and control groups, independent samples t-test and ANCOVA were performed. Differences between observation time points in each group were evaluated using repeated measures ANOVA and LSD post hoc test. P values <0.05 were considered significant.

## RESULTS

A total of 54 implants were placed in 32 patients, 29 implants in the test or osteotome group (10 females and nine males) with a mean age of  $52.3 \pm 8.77$  years and 25 implants in the control or conventional drilling group (six females and seven males) with a mean age of  $53.4 \pm 8.89$  years. There was no statistically significant difference between the two groups for gender ( $P=0.719$ ) or age ( $P=0.568$ ) (Table 1). Table 1 shows the location, length and width of implants in both groups. The results of chi-square test revealed no significant differences between the two groups when comparing the mentioned parameters.

All implants healed uneventfully and early implant failures did not occur during the three months of follow up. The mean ISQ values for both groups are presented in Table 2. The RFA measurements showed a mean ISQ of 71.38 at implant placement in the osteotome group and 67.44 in the control group. Although implant stability was higher during all measurement times for the test group compared to the control group, no significant differences were seen in the ISQ values between the two groups at the time of implant placement and at one, two and three months post-operatively (Table 2). Variation in ISQ with time for each group is

Table 2. The mean ISQ values of the two groups at each time point

Variable	Group	N	Mean	Std. Deviation	Minimum	Maximum	P-value
ISQ0	Osteotome	29	71.38	7.028	58	87	.090*
	Control	25	67.44	9.696	42	82	
ISQ1	Osteotome	29	71.31	6.240	58	87	.292#
	Control	25	67.84	7.116	51	77	
ISQ2	Osteotome	29	73.10	5.576	62	85	.373#
	Control	25	70.56	6.131	59	78	
ISQ3	Osteotome	29	73.93	6.369	62	88	.069#
	Control	25	70.04	5.891	59	80	

\* P-value based on independent t-test

# P-value based on ANCOVA adjusted for ISQ0

shown in Diagram 1. Changes in ISQ were significant in each group over time (repeated measures ANOVA,  $P=0.049$  for the osteotome and  $P=0.037$  for the control group).

The mean ISQ in the test group from T<sub>0</sub> (time of insertion) to T<sub>1</sub> (one month post-insertion) showed no statistically significant difference (LSD post hoc test,  $P > 0.05$ ).

The mean ISQ values increased from T<sub>1</sub> to T<sub>2</sub> (two months post-insertion). This increase was statistically significant ( $P=0.021$ ). Also, changes in ISQ from T<sub>1</sub> to T<sub>3</sub> (three months post insertion) were significant ( $P=0.005$ ). There was no significant change in ISQ values from T<sub>2</sub> to T<sub>3</sub> ( $P > 0.05$ ).

In the control group, there was no significant difference between ISQ values of T<sub>0</sub> and T<sub>1</sub>, or between T<sub>2</sub> and T<sub>3</sub> ( $P > 0.05$ ), but changes from T<sub>1</sub> to T<sub>2</sub> and T<sub>1</sub> to T<sub>3</sub> were statistically significant ( $P=0.001$  and  $P=0.02$ , respectively).

## DISCUSSION

Differences in jaw bone anatomy and structure can explain some of the variations in healing time and success rates of implant therapy [22]. The maxillary posterior region has the lowest bone density [22] and can result in lower primary stability and consequently higher failure rates [23]. The bone condensing technique has been introduced to increase bone density and primary stability in poor-quality bone [11-13]. In the present study, implant stability was compared in two methods of implant bed preparation namely the osteotome technique and conventional drilling technique. The RFA method with the Osstell equipment was used for implant stability measurement. This non-invasive method has been useful for monitoring implant osseointegration during the healing period and also determining the loading time of implants [5, 24].

The results of our study demonstrated that there were no statistically significant differences in the mean ISQ values between the two study groups during the observation period. This result is in line with those of Fanusca et al, in

2007 [18] and Buchter et al, in 2005 [4]. Buchter et al, in 2005 found a lower implant stability in osteotome group compared to conventional drilling when performing removal torque testing but found no significant difference between the two groups when compared via RFA [4]. They concluded that lower implant stability in osteotome technique could be the result of micro-fracture in peri-implant bone [4]. It seems like bone micro-damages can directly stimulate osteoclastic activity [25]. Also, an association between bone micro damage, cell apoptosis and osteoclastic bone resorption has been shown [26].

Moreover, trabecular network fracture during osteotome application seems to decrease anchorage potential of the trabecular bone; in other words, implant threads will be surrounded by fractured bone trabeculae in these situations [16].

Two clinical studies compared implant stability between osteotome and conventional drilling [19, 20].

Shayesteh et al, in 2013 demonstrated higher primary stability in osteotome group but no difference was noted after three months [20]. In this research, implants were placed in the anterior segment of the maxilla [20] but this region has mostly types II and III bone quality [27]. In a study by Markovic et al, in 2011, implants were placed in the posterior region of the upper jaw and they found higher implant stability in osteotome group both at the time of implant placement and during the whole observation period of six weeks [19].

Factors such as implant design and geometry, quality of bone, and research design may influence ISQ values and study results. For example, Fanusca et al, in 2007 used iliac crest bone from fresh frozen human cadavers, which seems to have similar bone quality to the posterior maxilla, but did not find any difference between the two methods [18]. In our study, only implants placed in the posterior maxilla were included because in this region of the jaw, class III and IV bone qualities are often present [27].

Bone density was determined clinically only by tactile sense when penetrating the bone with a drill. In the premolar area, it was sometimes difficult to distinguish between types II and III by tactile sense. Thus, there is a possibility that in some areas the bone quality varied. This is more probable in the single tooth or two teeth edentulous spans [27]. The use of computed tomography (CT) scan is suggested to determine bone density more precisely for future studies. The mean primary stability based on ISQ values was  $71.4 \pm 7$  (ranging from 58 to 87) for the osteotome group and  $67.4 \pm 10$  (ranging from 42 to 82) for the conventional drilling group. Based on a study by Nedir et al, in 2004 on Straumann SLA implants ISQ  $\geq 47$  was proposed as reliable implant stability, except previous ISQ values, were markedly higher [28]. Our three-month results presented favorable implant stability without any early failure. Of course follow up after loading is required to determine long-term results.

During the osseointegration phase up to three months, the ISQ values showed slight variations. From the installation time ( $T_0$ ) to one month, the mean ISQ values did not show significant changes in any group, but from the first month to the second month ( $T_1$  to  $T_2$ ) and also  $T_1$  to  $T_3$ , ISQ values increased significantly in both groups. These results are in line with a number of other clinical studies that have shown an increase in implant stability from three-four weeks to 12 weeks post-implant placement [19,29,30]. After an implant is placed into its prepared bed, primary stability is purely achieved by mechanical engagement of the implant into the bony site [31].

During the healing phase, bone remodeling takes place adjacent to the implant surface and the mechanical stability gives its place to biological or secondary stability [3, 32]. Thus, the process of contact osteogenesis after two-four weeks [3, 33] and maturation of bone into lamellar bone provide secondary stability, which can explain the increase in ISQ values after one

month of implant placement [28,30,34,35]. From the second month to the third month, changes in ISQ values were not significant. Han et al. showed a steady state in ISQ values during this time interval [30]. It has been concluded that in this type of implants if primary stability is favorable, the implant can be restored after two months. This is in agreement with the results of Cochran et al [36]. They showed that under certain conditions, implants with SLA surface could be loaded six weeks after placement with high success and survival rates [36].

## CONCLUSION

Within the limits of the current study, it is concluded that the osteotome technique does not lead to higher implant stability compared to conventional drilling. On the other hand, tapping the osteotome using a mallet is not comfortable for patients. Therefore, it is recommended to use an osteotome only in cases that in addition to having poor bone quality require closed sinus lift or ridge expansion.

## REFERENCES

- 1- Brånemark PI, Hansson BO, Adell R, Breine U, Lindström J, Hallén O, et al. Osseointegrated implants in the treatment of the edentulous jaw. Experience from a 10-year period. *Scand J Plast Reconstr Surg Suppl.* 1977;16:1-132.
- 2- Adell R, Lekholm U, Rockler B, Brånemark PI. A 15-year study of osseointegrated implants in the treatment of the edentulous jaw. *Int J Oral Surg.* 1981 Dec;10(6):387-416.
- 3- Abrahamsson I, Berglundh T, Linder E, Lang NP, Lindhe J. Early bone formation adjacent to rough and turned endosseous implant surfaces. An experimental study in the dog. *Clin Oral Implants Res.* 2004 Aug;15(4):381-92.
- 4- Büchter A, Kleinheinz J, Wiesmann HP, Kersken J, Nienkemper M, Weyhrother Hv, et al. Biological and biomechanical evaluation

- of bone remodeling and implant stability after using an osteotome technique. *Clin Oral Implants Res.* 2005 Feb;16(1):1-8.
- 5- Meredith N. Assessment of implant stability as a prognostic determinant. *Int J Prosthodont.* 1998 Sep-Oct;11(5):491-501.
- 6- Lekholm U, Zarb GA. Patient selection and preparation. In Branemark PI, Zarb GA, Albrektsson T (eds.). *Tissue integrated prostheses: Osseointegration in clinical dentistry.* Chicago: Quintessence, 1985: 199-209
- 7- Adell R, Eriksson B, Lekholm U, Brånemark PI, Jemt T. Long-term follow-up study of osseointegrated implants in the treatment of totally edentulous jaws. *Int J Oral Maxillofac Implants.* 1990 Winter;5 (4):347-59.
- 8- Jemt T. Failures and complications in 391 consecutively inserted fixed prostheses supported by Branemark implants in edentulous jaws: a study of treatment from the time of prosthesis placement to the first annual checkup. *Int J Oral Maxillofac Implants.* 1990 Dec;6(3):270-6.
- 9- Lundgren D, Lundgren AK, Sennerby L. The effect of mechanical intervention on jaw bone density. *Clin Oral Implants Res.* 1995 Mar;6(1):54-9.
- 10- Nkenke E, Kloss F, Wiltfang J, Schultze-Mosgau S, Radespiel-Tröger M, Loos K, et al. Histomorphometric and fluorescence microscopic analysis of bone remodeling after installation of implants using an osteotome technique. *Clin Oral Implants Res.* 2002 Dec;13(6):595-602.
- 11- Summers RB. A new concept in maxillary implant surgery: The osteotome technique. *Compendium.* 1994 Feb;15(2):152, 154-6.
- 12- Summers RB. The osteotome technique: Part 2--The ridge expansion osteotomy (REO) procedure. *Compendium.* 1994 Apr;15(4):422, 424, 426.
- 13- Summers RB. The osteotome technique: Part 3--Less invasive methods of elevating the sinus floor. *Compendium.* 1994 Jun;15(6):698, 700, 702-4.
- 14- Summers RB. The osteotome technique: Part 4--Future site development. *Compend Contin Educ Dent.* 1995 Nov;16(11):1090, 1092.
- 15- Hahn J. Clinical uses of osteotomes. *J Oral Implantol.* 1999;25(1):23-9.
- 16- Cehreli MC, Kökat AM, Comert A, Akkocaoğlu M, Tekdemir I, Akça K. Implant stability and bone density: assessment of correlation in fresh cadavers using conventional and osteotome implant sockets. *Clin Oral Implants Res.* 2009 Oct;20(10):1163-9.
- 17- Ahn SJ, Leesungbok R, Lee SW, Heo YK, Kang KL. Differences in implant stability associated with various methods of preparation of the implant bed: an in vitro study. *J Prosthet Dent.* 2012 Jun;107 (6):366-72.
- 18- Fanuscu MI, Chang TL, Akça K. Effect of surgical techniques on primary implant stability and peri-implant bone. *J Oral Maxillofac Surg.* 2007 Dec;65(12):2487-91.
- 19- Marković A, Calasan D, Colić S, Stojčević L, Janjić B, Mišić T. Implant stability in posterior maxilla: bone-condensing versus bone-drilling: a clinical study. *Oral Surg Oral Med Oral Pathol Oral Radiol Endod.* 2011 Nov;112(5):557-63.
- 20- Shayesteh YS, Khojasteh A, Siadat H, Monzavi A, Bassir SH, Hossaini M, et al. A comparative study of crestal bone loss and implant stability between osteotome and conventional implant insertion techniques: a randomized controlled clinical trial study. *Clin Implant Dent Relat Res.* 2013 Jun 1;15(3):350-7.
- 21- Nóbrega AR, Norton A, Silva JA, Silva JP, Branco FM, Anitua E. Osteotome versus conventional drilling technique for implant site preparation: a comparative study in the rabbit. *Int J Periodontics Restorative Dent.* 2012 Jun;32(3):e109-15.
- 22- Devlin H, Horner K, Ledgerton D. A comparison of maxillary and mandibular bone mineral densities. *J Prosthet Dent.* 1998 Mar;79(3): 323-7.
- 23- Martinez H, Davarpanah M, Missika P, Celletti R, Lazzara R. Optimal implant stability

- zation in low density bone. Clin Oral Implants Res. 2001 Oct;12(5):423-32.
- 24- Sennerby L, Meredith N. Resonance Frequency Analysis: Measuring Implant Stability and Osseointegration. Compend Contin Educ Dent. 1998 May;19(5):493-8, 500, 502.
- 25- Mori S, Harruff R, Burr DB. Microcracks in articular calcified cartilage of human femoral heads. Arch Pathol Lab Med. 1993 Feb;117(2):196-8.
- 26- Verborgt O, Gibson GJ, Schaffler MB. Loss of osteocyte integrity in association with microdamage and bone remodeling after fatigue in vivo. J Bone Miner Res. 2000 Jan;15(1):60-7.
- 27- Misch CE. Bone Density: A key determinant for treatment plan. In: Misch CE. Contemporary Implant Dentistry. Missouri: Mosby Elsevier; 2008:130-146
- 28- Nedir R, Bischof M, Szmukler-Moncler S, Bernard JP, Samson J. Predicting osseointegration by means of implant primary stability. Clin Oral Implants Res. 2004 Oct;15(5):520-8.
- 29- Rokn A, Ghahroudi AR, Mesgarzadeh A, Miremadi A, Yaghoobi S. Evaluation of stability changes in tapered and parallel wall implants: a human clinical trial. J Dent (Tehran). 2011 Fall;8(4):186-200.
- 30- Han J, Lulic M, Lang NP. Factors influencing resonance frequency analysis assessed by Osstell™ mentor during implant tissue integration: II. Implant surface modifications and implant diameter. Clin Oral Implants Res. 2010 Jun;21(6):605-11.
- 31- Cochran DL, Schenk RK, Lussi A, Higginbottom FL, Buser D. Bone response to unloaded and loaded titanium implants with a sandblasted and acid-etched surface: a histometric study in the canine mandible. J Biomed Mater Res. 1998 Apr;40(1):1-11.
- 32- Javed F, Romanos GE. The role of primary stability for successful immediate loading of dental implants. A literature review. J Dent. 2010 Aug;38(8):612-20.
- 33- Cornelini R, Cangini F, Covani U, Barone A, Buser D. Immediate restoration of single-tooth implants in mandibular molar sites: a 12-month preliminary report. Int J Oral Maxillofac Implants. 2004 Nov-Dec;19(6):855-60.
- 34- Karl M, Graef F, Heckmann S, Krafft T. Parameters of resonance frequency measurement values: a retrospective study of 385 ITI dental implants. Clin Oral Implants Res. 2008 Feb;19(2):214-8.
- 35- Huwiler MA, Pjetursson BE, Bosshardt DD, Salvi GE, Lang NP. Resonance frequency analysis in relation to jawbone characteristics and during early healing of implant installation. Clin Oral Implants Res. 2007 Jun;18(3):275-80.
- 36- Cochran DL, Buser D, ten Bruggenkate CM, Weingart D, Taylor TM, Bernard JP, et al. The use of reduced healing times on ITI implants with a sandblasted and acid-etched (SLA) surface: early results from clinical trials on ITI SLA implants. Clin Oral Implants Res. 2002 Apr;13(2):144-53.