

Horizontal Dental Changes during First Stage of Treatment Using the MBT Technique

T. Hosseinzadeh-Nik^{1,2✉}, AM. Farrokhzadeh³, B. Golestan⁴

¹Associate Professor, Department of Orthodontics, Faculty of Dentistry, Medical Sciences/Tehran University, Tehran, Iran

²Associate Professor, Dental Research Center, Medical Sciences/Tehran University, Tehran, Iran

³Dentist, Private Practice

⁴Assistant Professor, Department of Epidemiology and Biostatistics, School of Public Health and Institute of Public Health Research, Medical Sciences/Tehran University, Tehran, Iran

Abstract:

Objective: The purpose of this study was to evaluate the dental movements of the labial segment and the canines during leveling and alignment using pre-adjusted appliances and light forces with the MBT technique. The effect of lacebacks on the horizontal movement of the first molars was also assessed.

Materials and Methods: Fourteen patients with a mean age of 14.08 years were selected for this before-after clinical study. Dental casts were prepared for each subject at the onset of the study followed by banding and bonding using preadjusted brackets. A lateral cephalogram was taken with the appliances in place (T0). All patients underwent extraction of the four first premolars and treatment started using the MBT technique. A second set of casts and another cephalogram was obtained after 8 weeks (T1).

Results: All contact point displacements decreased between T1 and T2 with the mean (SD) of -7.65 (4.16) mm in the upper arch; -7.07(3.28) mm in the lower arch. Retroclination was observed in the maxillary and mandibular incisors with the mean value of -0.021 (1.696) mm and -0.021 (1.515) mm during the study period respectively. The lower first molars showed 0.0207 (0.9657) mm displacement and the upper first molars showed 0.665 (1.296) mm mesial movement in the horizontal plane. The upper and lower canines moved distally and were uprighted, respectively. A significant increase was found in the mandibular intercanine width (P= 0.004).

Conclusion: The results of this study are in favor of using preadjusted brackets for orthodontic treatment. In premolar-extraction, cases receiving preadjusted edgewise appliances; the lower labial segment does not procline during the leveling stage.

Key Words: Dental changes; Lace backs; Pre-adjusted edgewise appliance; Straight wire

✉ Corresponding author:
T. Hosseinzadeh-Nik, Department of Orthodontics, Faculty of Dentistry, Tehran University of Medical Sciences, Tehran, Iran.
hossein@tums.ac.ir

Received: 13 May 2006
Accepted: 13 September 2006

Journal of Dentistry, Tehran University of Medical Sciences, Tehran, Iran (2007; Vol: 4, No.1)

INTRODUCTION

Fixed appliance therapy is one of the most widely used treatment modalities in orthodontic practice. Appropriate placement of brackets followed by engagement with rectangular arch wires, confers adequate torque and tip to the tooth. This allows correct inclination and angulation so that the finished treatment meets

Andrews' "six keys of normal occlusion" [1]. Preadjusted brackets combine first, second and third order coordinations in a single bracket. Andrews introduced the first generation of Straight Wire Appliances (SWA) [2]. In recent years, various prescriptions have been proposed by several investigators, leading to the development of different preadjusted

orthodontic bracket systems such as Andrews, Roth and MBT. The Roth prescription proposed by Roth has become very popular among orthodontists [3, 4]. It has been stated that the tip integrated into incisor and canine brackets may increase the tendency of the labial segments to slant forward, especially in the maxilla where the bracket tip is greater. The canine has been reported to have the greatest amount of forward movement due to its greater tip value. This can result in proclination of the incisors, ultimately affecting long-time stability [5].

Laceback ligatures, first introduced by McLaughlin and Bennett, are 0.009 or 0.010-inch soft stainless steel figure-eight wires, tied from the most distally banded molar to the canine bracket. They are usually used to control anchorage during leveling and aligning and have several advantages such as prevention of forward tipping of the lower labial segment, distalization of canines without tipping and protection from masticatory forces for light aligning arch wires across extraction spaces. These ligatures along with pre-adjusted edge-wise appliances are favored by many practitioners through out the world [5-11].

Robinson [12] in an unpublished study reported distal movement of incisors treated with lacebacks as opposed to their proclination in non-laceback treated cases. First molars also demonstrated mesial and forward movements when treated with and without lacebacks, respectively. A significant difference was observed between the laceback and non-laceback treated cases.

Usmani et al [13] assessed the effectiveness of canine lacebacks on the proclination of upper incisors and found a mean incisor retroclination of 0.5 mm. They did not find a significant difference in the mesial movement of the upper first molars between patients treated with and without lacebacks.

Irvine et al [14] detected retroclination of lower incisors regardless of the use of lace-

back. The difference between the two treatment methods was not significant. In contrast, the mesial movement of the lower first molars was significantly greater in laceback as compared to non-laceback-treated cases. Labial segment crowding and arch length both decreased despite the utilization of lacebacks.

Sueri et al [15] applied the MBT technique with extraction of the first premolars to study the effectiveness of laceback ligatures on maxillary canine retraction. Canine distalization was successfully achieved with laceback ligatures. Canine and molar movements were significantly smaller in laceback cases. Force characterization and arch wire size were suggested to be responsible for the difference(s) between the two treatment procedures.

The purpose of this study was to evaluate the dental movements of the labial segment and the canines during leveling and aligning using pre-adjusted appliances and light forces with the MBT technique. The effect of lacebacks on the horizontal movement of the first molars was also assessed.

MATERIALS AND METHODS

Fourteen patients, 10 females and 4 males, with a mean age of 14 years and 1 month (range, 11 to 21 years) were selected for this before-after clinical study. All participants had either Class I or mild Class II skeletal relationships with crowding. The treatment plan for the subjects included fixed orthodontic therapy and the extraction of four first premolars.

Dental casts were prepared for each patient at the onset of the study followed by banding and bonding using preadjusted brackets with a slot dimension of 0.022 inch placed according Bennet and McLaughlin [9]. Banding and direct bracket bonding was performed by different operators. With the appliances in place, a pretreatment cephalogram (T0) with a 10% magnification was obtained for all subjects. An L-shaped 19×25-inch stainless steel wire was inserted into the upper and

lower right molar tubes during radiographic exposure. This wire served as an identification marker for measuring both linear and angular tooth displacements. Such markers were not necessary for the anterior teeth because they are completely visible on the cephalogram and superimposing structures are minimal in this region. At this stage, the premolars were extracted and treatment started with MBT appliances. Lacebacks were tied from the molars to the canines using 0.010 steel ligature wires. A preformed superelastic 0.016-inch Nickel Titanium arch wire (Orthoform I, 3M, Monrovia, CA) was inserted and engaged in the brackets with elastomeric modules. In order to prevent flaring or protrusion of the incisors, bendbacks were placed immediately distal to the molar tubes. The arch wire remained in place for 8 weeks without any other auxiliaries like headgears, palatal bars or elastics. The patients returned every 2 weeks for retying or replacing the lacebacks. Any accidental bracket loosening was managed within 48 hours of the event. After the 8-week period, the arch wires were removed and a second set of impressions were taken. The L-shaped markers were reinserted prior to obtaining the second (T1) cephalogram, using the same x-ray machine. Treatment of the patients continued thereafter according to the MBT technique. The second molars were banded as necessary.

The following measurements were made on each of the casts using digital calipers with an accuracy of 0.01 millimeter:

- Contact point displacement of the six anterior teeth.
- Inter canine width, measured from the canine cusp tips.
- Intermolar width, measured from the distobuccal cusp of the first molars.
- Space closure, measured from the canine cusp tip to the distobuccal cusp tip of the first molar on the same side.

All cephalograms were traced based on Pancherz analysis by dropping a line plumb from

Sella to the occlusal plane [16]. This line and the intersecting point served as references for horizontal measurements (Fig. 1). The upper first molars (UM) and incisors (UI) and the lower first molars (LM) and incisors (LI) were evaluated. The palatal and mandibular planes were used as reference lines for the evaluation of vertical changes in the upper and lower teeth, respectively. Lines were drawn from the incisal edge perpendicular to these planes. Perpendicular lines were also drawn from the tip of the L-shaped wires to their corresponding reference planes.

Any changes in tooth inclination and angulation occurring during the study period were recorded in reference to the SN, palatal and mandibular planes.

Tracings of T0 and T1 were superimposed to calculate changes in the recorded points. Linear measurements were performed with a 0.5mm graduated steel ruler. Forward displacements and distal movements were recorded as positive and negative values, respectively. Angular measurements were carried out using a protractor with an accuracy of 1°. Statistical analysis was performed using the Wilcoxon signed rank test.

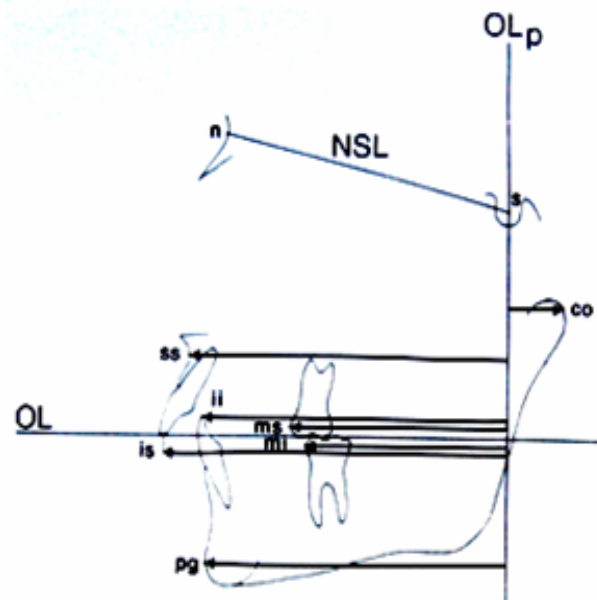


Fig. 1: Measuring points used in Pancherz analysis.

RESULTS

Assessment of casts revealed that All contact point displacements decreased at the end of the study period with the mean (SD) value of -7.65 (4.16) in the upper and -7.07 (3.28) in the lower arches. The greatest amount of displacement was found between the lateral incisors and canines in both arches. The least amount was observed between the central incisors in both jaws.

Inter canine width (mean, 2.25mm) increased significantly in the lower, but not the upper arch (P= 0.004). The changes in the maxillary and mandibular intermolar widths were not significant. The distance between the first molar and canine decreased in the upper and lower arches with the mean value of 3.39 (0.94) and -2.60 (0.61) respectively. Radiographic findings are shown in Table I.

The only significant horizontal change was the mesial movement of the upper molars. The lower molars almost retained their positions throughout the study. A non-significant retroclination was observed in the upper and lower incisors at the end of the 8-week period. The canines were both distalized and remained upright.

Table I: Mean (SD) of dentoskeletal changes for upper/lower arches.

	Variable	Changes	P-value
Horizontal (mm)	Upper Molar	0.665 (1.296)	0.03*
	Upper Incisor	-0.021 (1.696)	0.83
	Lower Molar	0.0207 (0.9657)	0.9
	Lower Incisor	-0.021 (1.5152)	1
Angular (°)	UM-PP	1.49 (4.93)	0.2
	UC-PP	-4.36 (7.99)	0.04*
	U1-SN	-0.14 (2.60)	0.83
	LM-MP	0.04 (4.32)	0.92
	LC-MP	-5.06 (5.16)	0.01*
	IMPA	1.16 (3.34)	0.29
	U1-Apog	-0.07 (0.95)	0.21

* represent significant difference

DISCUSSION

All contact point displacements decreased at the end of the study period with the mean, (SD) of -7.65 (4.16) in the upper and -7.07 (3.28) in the lower arch. Retroclination of the upper, -0.021 (1.696), and lower incisors, -0.021 (1.5152), was observed between T0 and T1. The lower first molars showed 0.0207 (0.9657)mm movement in the horizontal plane. A mesial movement of 0.665(1.296) mm was seen in the upper first molars with respect to the same plane. The upper and lower canines were distalized and uprighted, with the mean value of -4.36 (7.99) and -5.06 (5.16) respectively. A significant increase (mean, 2.25mm) in the inter canine width was found in the lower arch (P= 0.004).

Numerous attempts have been made to increase the efficiency and predictability of orthodontic mechanotherapy [2]. Orthodontists usually apply intermediate forces, which may lead to an unpredictable tooth movement due to many biomechanical factors. Edgewise and Begg systems have undergone slight biomechanical changes in the past 30 years which has led to the development of the "Straight-wire technique". This technique claims to be the treatment of choice when preadjusted appliances and preformed arch wires are indicated. Some authors have shown that pre-adjusted edgewise appliances can cause proclination of the labial segment leading to a compromised anchorage during the initial stages of treatment [2-4]. Conversely, in the present study the lower incisors retroclined slightly during the leveling phase, -0.021 (1.696) and -0.021 (1.515) in the upper and lower arch respectively. The use of flexible arch wires has been reported to enhance these dental changes [17]. Usmani et al [13] found a mean incisor retroclination of 0.5 mm in cases treated with laceback. Irvine et al [14] in a randomized clinical controlled trial studied the effectiveness of lace back ligatures and indicated that lower incisors retroclined

regardless of the use of lacebacks. A significant difference was not observed between the laceback and non-laceback-treated patients. The laceback cases revealed a 0.09 mm greater retroclination compared to the non-laceback subjects, which was not statistically significant. It can be concluded that passive laceback ligatures do not affect the antero-posterior position of the lower labial segment [13]. Therefore, the effectiveness of lacebacks as an adjunct to the straight wire technique is questionable and requires further investigation. In the current study, the changes in intercanine widths were different between the upper and lower arches. Despite the use of tapered preformed arch wires, the intercanine width of the lower arch increased at the end of the study period. This may be due to simultaneous distal displacement of both lower canines situating them in a wider portion of the arch. Similar increase following distalization of upper canines was also expected but did not occur. A possible explanation for this difference could be that the upper canines are relatively more malpositioned than their lower counterparts at the beginning of treatment. In addition, the upper canines face more space deficiency because of their later emergence. The amount of mesial movement of the molars was different between the two arches. The lower molars essentially maintained their position but the upper molars moved mesially. This has also been reported by other investigators, and is especially important when strict control of anchorage becomes an important issue [14,15]. It seems necessary to control anchorage from the beginning of treatment when employing the MBT technique.

CONCLUSIONS

Within the limitations of this study, the following conclusions can be drawn during the first stage of treatment with preadjusted brackets using the MBT technique:

- A significant mesial drift may occur in the

upper first molars, whereas the lower first molars remain in their original position.

- Distalization and uprighting of the canines can occur which may be due to the use of lacebacks.
- A considerable increase may be observed in the intercanine width.
- Reinforcement of anchorage in the upper arch is recommended during this phase.

ACKNOWLEDGMENT

Authors wish to thank the Dental Research Center, Tehran University of Medical Sciences for supporting this research. Authors also would like to express their gratitude to Dr. Faramarz Mojtahedzadeh for his assistance.

REFERENCES

- 1- Andrews LF. The six keys to normal occlusion. *Am J Orthod* 1972 Sep;62(3):296-309.
- 2- Andrews LF. The straight-wire appliance. Explained and compared. *J Clin Orthod* 1976 Mar;10(3):174-95.
- 3- Roth RH. Five year clinical evaluation of the Andrews straight-wire appliance. *J Clin Orthod* 1976 Nov;10(11):836-50.
- 4- Roth RH. The straight-wire appliance 17 years later. *J Clin Orthod* 1987 Sep;21(9):632-42.
- 5- McLaughlin RP, Bennett JC. The transition from standard edgewise to preadjusted appliance systems. *J Clin Orthod* 1989 Mar;23(3):142-53.
- 6- McLaughlin RP, Bennett JC, Trevisi HJ. *Systemized Orthodontic Treatment Mechanics*. Edinburgh: Mosby; 2001:101-2.
- 7- Bennett JC, McLaughlin RP. Management of deep overbite with a preadjusted appliance system. *J Clin Orthod*. 1990 Nov;24(11):684-96.
- 8- Bennett JC, McLaughlin RP. Controlled space closure with a preadjusted appliance system. *J Clin Orthod*. 1990 Apr;24(4):251-60.
- 9- McLaughlin RP, Bennett JC. Bracket placement with the preadjusted appliance. *J Clin Orthod* 1995 May;29(5):302-11.
- 10- Bennett JC, McLaughlin RP. Overjet reduction with a preadjusted appliance system. *J Clin Orthod*

1992 May;26(5):293-309.

11- McLaughlin RP, Bennett JC. Finishing and detailing with a preadjusted appliance system. *J Clin Orthod* 1991 Apr;25(4):251-64.

12- Robinson SN. An Evaluation of the Changes in Lower Incisor Position during the Initial Stages of Clinical Treatment Using a Preadjusted Edgewise Appliance [master's thesis]. University of London, London, UK; 1989.

13- Usmani T, O'Brien KD, Worthington HV, Derwent S, Fox D, Harrison S, Sandler PJ, Mandall NA. A randomized clinical trial to compare the effectiveness of canine lacebacks with reference to canine tip. *J Orthod* 2002 Dec;29(4): 281-6

14- Irvine R, Power S, McDonald F. The effectiveness of laceback ligatures: a randomized controlled clinical trial. *J Orthod* 2004 Dec;31(4): 303-11.

15- Sueri MY, Turk T. Effectiveness of laceback ligatures on maxillary canine retraction. *Angle Orthod* 2006 Nov;76(6):1010-4.

16- Pancherz H. The mechanism of Class II correction in Herbst appliance treatment. A cephalometric investigation. *Am J Orthod* 1982 Aug;82(2):104-13.

17- Evans TJ, Jones ML, Newcombe RG. Clinical comparison and performance perspective of three aligning arch wires. *Am J Orthod Dentofacial Orthop* 1998 Jul;114(1):32-9.