

Evaluation of Morphology and Anatomical Measurement of Nasopalatine Canal Using Cone Beam Computed Tomography

Mehrdad Panjnoush ¹, Hamideh Norouzi ², Yasaman Kheirandish ³✉, Ahmad Reza Shamshiri ⁴, Niloufar Mofidi ⁵

¹ Assistant Professor, Head of the Department of Oral and Maxillofacial Radiology, School of Dentistry, Tehran University of Medical Sciences, Tehran, Iran

² Dentist, Tehran, Iran

³ Assistant Professor, Department of Oral and Maxillofacial Radiology, School of Dentistry, Tehran University of Medical Sciences, Tehran, Iran

⁴ Assistant Professor, Department of Community Oral Health, Dental Research Center, Dentistry Research Institute, School of Dentistry, Tehran University of Medical Sciences, Tehran, Iran

⁵ Assistant Professor, Department of Oral and Maxillofacial Radiology, School of Dentistry, Kurdistan University of Medical Sciences, Sanandaj, Iran

Abstract

Objectives: Precise radiographic assessment of the nasopalatine canal is required to prevent implant failure. The purpose of the current study was to determine the three dimensional (3D) morphology, as well as the dimensions of the nasopalatine canal using cone beam computed tomography (CBCT).

Materials and Methods: In this descriptive cross-sectional study, maxillary CBCT images from 300 patients (150 men, 150 women) were retrospectively evaluated. Sagittal and coronal views were reviewed to determine the nasopalatine canal morphology and dimensions. The difference in canal dimensions between men and women was evaluated using the Student's t-test while the difference in canal morphology between the two sexes was assessed using Chi-square test.

Results: A total of 199 (66.3%) patients had type A canal (cylindrical without a branch), 69 (23%) had type B canal (a canal with a branch in the upper part), and 32 (10.7 %) had type C canal (a canal with a branch in the middle part). Incisive foramen diameter was 4.7 ± 1.1 mm on the sagittal section. Alveolar bone width in the anterior part of the canal was 12.3 ± 1.7 mm in the upper one third, 10.7 ± 1.7 mm in the middle one third, and 9.8 ± 1.4 mm in the lower one third. The angle of canal with palate was $109.5 \pm 5.7^\circ$. On the coronal sections, canal length was 14.1 ± 3.0 mm, incisive foramen diameter was 4.6 ± 1.0 mm, and canal diameter in the nasal floor was 5.1 ± 1.0 mm.

Conclusions: Significant differences in canal morphology were observed among the patients and CBCT was useful in determining nasopalatine canal morphology and its dimensions before implant placement.

Keywords: Anatomy; Cone-Beam Computed Tomography; Dental Implants; Maxilla

Journal of Dentistry, Tehran University of Medical Sciences, Tehran, Iran (2016; Vol. 13, No. 4)

✉Corresponding author:

Y. Kheirandish, Department of Oral and Maxillofacial Radiology, School of Dentistry, Tehran University of Medical Sciences, Tehran, Iran

kheirandish@sina.tums.ac.ir

Received: 20 February 2015

Accepted: 11 June 2016

INTRODUCTION

Nasopalatine canal usually lies in the palatal midline behind the maxillary central incisors. Recently, aesthetic issues have become very important in dental treatment plans and implant surgery and as far as patients are concerned, aesthetics play a more important role than implant function [1].

Failure in implantology may cause challenging situations that require implant removal and tissue augmentation [2]. Implant contact with neurovascular tissue could result in the loss of

osseointegration or development of sensory disorders. Considering these complications, nasopalatine canal morphology and dimensions should be evaluated carefully before dental implant placement [3].

In order to minimize complications following implant placement in the incisor area, three-dimensional (3D) configuration of nasopalatine canal, its position in relation to the surrounding structures, alveolar bone morphology, and incisors' morphological changes in the alveolar bone should be evaluated carefully [4]. In

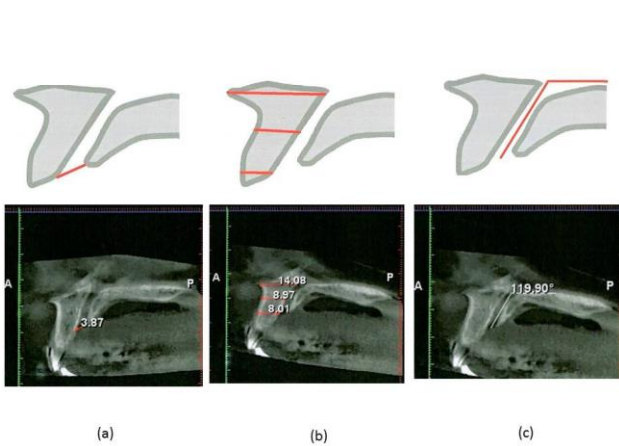


Fig. 1: Measurement of incisive foramen diameter (a), buccal bone anterior to nasopalatine canal (b) and nasopalatine canal angle with palatal bone (c) in sagittal section

addition, when selecting the implant site, important anatomical structures such as nasopalatine canal, incisive and mental foramina, inferior alveolar canal, nasal fossa, and maxillary sinuses should be considered.

Conventional radiographic techniques such as panoramic and intraoral X-rays do not provide any information about buccolingual width of the alveolar bone, anatomical structures' condition, or the 3D structure of the selected implant site [5]. In addition, modern implant systems depend on advanced imaging modalities, which are helpful in both diagnosing and treatment planning fields. Radiographic evaluation before surgery determines bone quality and quantity in the selected area and is a useful guide for selecting the proper site, number, size, and angle of implants [6].

Implants might be placed in soft tissues, including neurovascular bundle of the nasopalatine canal, which may lead to loss of osseointegration. In order to avoid these complications, an accurate evaluation of the nasopalatine canal and its surrounding bone is necessary, and the distance between the implant site and the adjacent anatomical landmarks should be measured precisely [7].

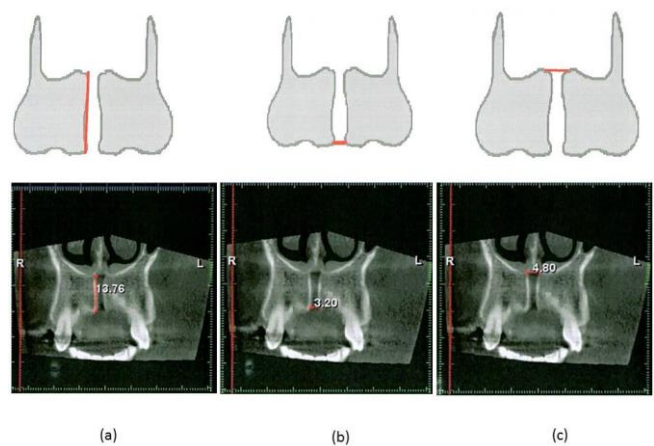


Fig. 2: Measurement of nasopalatine canal length (a), incisive foramen diameter (b) and width in nasal floor area (c) in coronal section

Cone beam computed tomography (CBCT) is recommended for 3D visualization of various structures, which are difficult to detect on panoramic and intra-oral views [4]. On the other hand, there are no obvious differences between linear measurements on CBCT and direct measurements of maxillofacial structures, which is the gold standard [8].

The purpose of this study was to determine the three dimensional morphology and dimensions of nasopalatine canal using CBCT in patients referred to an oral and maxillofacial radiology center.

MATERIALS AND METHODS

In this descriptive cross sectional study, CBCT scans from 300 consecutive patients (150 men, 150 women) referred to an oral and maxillofacial radiology center were selected and evaluated. Patients suffering from periodontal diseases and bone loss were excluded from the study. Poor quality CBCT images and those with technical problems were also excluded.

The CBCT images were obtained using standard exposure parameters and patient positioning protocols (field of view= 8×8cm, resolution= 0.16mm, 80-84kvp, 10-12mA) with a CBCT unit

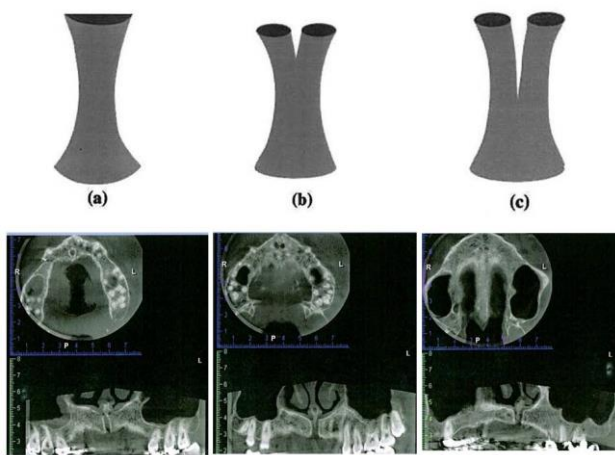


Fig. 3: Nasopalatine canal classification according to morphology: (a) cylindrical canal without any branches (b), a canal with a branch in the upper part and (c) a canal with a branch in the middle part

(Planmeca, Helsinki, Finland). Romexis version 2.9.1 software (Planmeca, Helsinki, Finland) was used to reformat the scans in order to visualize the 3D structure of the canals. This software enables detailed dimensional measurements of canal dimensions. All images were observed and evaluated by an expert radiologist.

Incisive foramen dimensions, alveolar bone width in the anterior region of the canal (upper, middle, and lower thirds), and the angle between the canal and palate were measured on sagittal CBCT cross-sections (Fig. 1). In addition, nasopalatine canal length, incisive foramen diameter, and canal diameter in the floor of the nasal fossa were measured on the coronal cross sections (Fig. 2). Finally, the canal morphology was classified based on the evaluation of different views (Fig. 3) [9].

Statistical analysis: We used SPSS software version 18 (SPSS Inc., IL, USA) for statistical analysis. The mean and standard deviation of the diameter of incisive foramen in the sagittal plane, alveolar bone width anterior to the canal (upper, middle, and lower thirds), the angle between the canal and palate, nasopalatine canal length, incisive foramen diameter in the coronal plane,

and the canal diameter in the floor of nasal fossa on CBCT scans were reported based on the patients' sex and dentition status. In addition, the frequency of the types of nasopalatine canal morphology was determined according to patient sex. Quantitative variables related to canal in men and women and dentulous and edentulous patients were evaluated using Student's t-test. To assess the prevalence of different canal types in men and women, Chi-square test was applied. In addition, the relationship between the quantitative variables and the patients' age was assessed using Pearson's correlation coefficient. A P-value of ≤ 0.05 was considered statistically significant.

RESULTS

The mean age of patients was 43.17 ± 11.00 years (range 16-68 years). The mean age of males was 43.61 ± 12.06 years and that of females was 42.72 ± 9.86 years. There were 263 (87.7%) dentulous and 37 (12.3%) edentulous patients. One hundred thirty-two men (88%) were dentulous and 18 (12%) were edentulous, while 131 (87.3%) women were dentulous and 19 (12.7%) were edentulous. One hundred

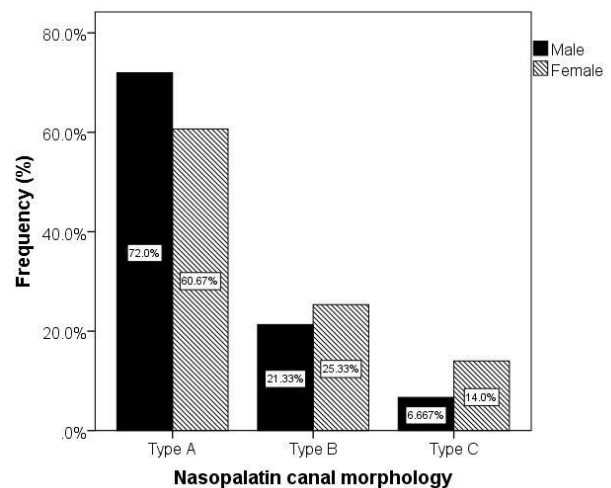


Fig. 4: Nasopalatine canal morphology and its variation in males and females

Table 1: Mean and standard deviation of measurements related to nasopalatine canal according to patients' gender

	Total (n=300)	Males (n=150)	Females (n=150)	Mean of differences (SE)	P-value
Incisive foramen sagittal diameter	4.70±1.11	4.92±1.25	4.49±0.9	0.43 (0.13)	0.001
Alveolar bone width anterior to canal in upper one third	12.32±1.74	12.8±1.7	11.9±1.7	0.88 (0.19)	< 0.001
Alveolar bone width anterior to canal in middle one third	10.65±1.68	10.5±2.0	10.8±1.2	0.27 (0.19)	0.16
Alveolar bone width anterior to canal in lower one third	9.78±1.44	9.5±1.7	10/0±1.1	0.50 (0.16)	0.003
Nasopalatine canal angle with palate	109.51±5.70	109.3±5.6	109.7±5.8	0.44 (0.66)	0.5
Nasopalatine canal length	14.09±3.03	14.4±3.0	13.8±3.0	0.60 (0.35)	0.09
Incisive foramen coronal diameter	4.57±0.99	4.5±1.0	4.6±1.0	0.09 (0.11)	0.41
Canal diameter in nasal fossa floor	5.08±0.96	5.0±1.0	5.2±0.9	0.21 (0.11)	0.06

ninety-nine patients (66.3%) had type A canal morphology (cylindrical without a branch), 69 (23%) had type B canal morphology (a canal with a branch in the upper part), and 32 (10.7%) had type C canal (a canal with a branch in the middle part). Nasopalatine canal morphology and its variations in men and women are shown in Figure 4. There was a statistically significant difference in nasopalatine canal type between males and females ($P=0.05$).

Type A canal was seen more frequently in men while types B and C were more prevalent in women. In addition, the means and standard deviations of incisive foramen sagittal and coronal diameters, alveolar bone width anterior to the canal in the upper, middle, and lower thirds, nasopalatine canal angulation with palatal bone, nasopalatine canal length and its diameter in the nasal fossa floor according to the patients' sex and dentition condition are reported in Tables 1 and 2, respectively.

We did not detect any statistically significant relationships between the incisive foramen sagittal diameter and age ($r=0.02$, $P=0.77$), alveolar bone width anterior to the canal in the upper third and age ($r=-0.004$, $P=0.95$), alveolar bone width anterior to the canal in the middle third and age ($r=-0.09$, $P=0.12$), nasopalatine canal angle with palatal bone and age ($r=0.02$, $P=0.80$), nasopalatine canal length and age ($r=-0.04$, $P=0.45$), incisive foramen coronal diameter and age ($r=-0.05$, $P=0.42$), or canal diameter in the nasal fossa floor and age ($r=-0.08$, $P=0.19$).

However, there was a weak, statistically significant inverse relationship between age and alveolar bone width anterior to the canal in the lower third ($r=-0.14$, $P=0.02$) such that alveolar bone width anterior to the canal in the lower third decreased with aging. Generally, there was no significant relationship with age ($P>0.05$).

DISCUSSION

Development of CBCT has brought great changes in dentistry. While the patients are exposed to a slightly higher radiation dose with this modality, it provides detailed quantitative and qualitative information that are not otherwise available via conventional methods and this makes the increased radiation dose justifiable. Nevertheless, future studies to evaluate the effects of this technique on improved diagnostic accuracy and development of treatment plans are necessary as patients should not be subjected to increased radiation if this imaging modality does not improve diagnostic accuracy. Cone beam computed tomography dose is three to seven times higher than that of conventional radiography and it is more time consuming. However, due to the advantages of CBCT in implant fields, it is strongly recommended. The risks and benefits of each imaging modality should be considered carefully, particularly in the youth, as any additional exposure leads to unfavorable effects on growing tissues [10]. In a study by Farman [11], ALARA (as low as reasonably achievable) principle was the

Table 2: mean and standard deviation of measurements related to nasopalatine canal according to teeth situation

	Total (n=300)	Dentulous (n=263)	Edentulous (n=37)	Mean of differences (SE)	P-value
Incisive foramen sagittal diameter	4.70±1.11	4.62 ± 1.09	5.24 ± 1.04	0.62 (0.19)	0.001
Alveolar bone width anterior to canal in upper one third	12.32±1.74	12.43±1.79	11.54±1.04	0.89 (0.30)	<0.001
Alveolar bone width anterior to canal in middle one third	10.65±1.68	10.76±1.72	9.92±1.18	0.84 (0.29)	<0.001
Alveolar bone width anterior to canal in lower one third	9.78±1.44	9.97±1.41	8.46±0.76	1.51 (0.24)	<0.001
Nasopalatine canal angle with palate	109.51±5.70	109.57±5.78	109.04±5.15	0.54 (1.00)	0.59
Nasopalatine canal length	14.09±3.03	14.07±3.05	14.22±2.91	0.15 (0.53)	0.77
Incisive foramen coronal diameter	4.57±0.99	4.58±0.99	4.51±0.97	0.08 (0.17)	0.65
Canal diameter in nasal fossa floor	5.08±0.96	5.1±0.95	4.92±1.03	0.18 (0.17)	0.27

fundamental criterion in choosing CBCT and other diagnostic radiographic modalities. It is necessary to define principles for CBCT in this regard. It should be noted that CBCT radiation dose has decreased significantly without any considerable effects on the image quality.

Due to the close anatomical relation between the nasopalatine canal and the maxillary central incisor roots, precise radiographic evaluation of the canal before implant placement is of utmost importance. However, only few studies have been conducted on variations in canal anatomy, morphology and dimensions [3].

Various surgical techniques are performed to avoid nasopalatine canal perforation during implant insertion [12-14]. Three dimensional methods such as computed tomography can be used for evaluation of the anterior segment of the maxilla and canal morphology [15]. According to the classification for nasopalatine canal morphology in three groups of A to C [9], type A nasopalatine canal morphology was the most frequent type in our study. Bornstein et al, [16] evaluated the dimensions and anatomical features of nasopalatine canal and its corresponding alveolar buccal plate using CBCT and found type A canal morphology in 45% of the patients. Similarly, in a study by Song et al, [17] type A nasopalatine canal morphology was seen in 42.9% of the subjects. It is notable that they found four separate canals in some samples. We found type A canal morphology in 66.6% of the patients, type B in 23.1%, and type C in

10.4%, which was similar to the findings of other studies [9,16,17,18]. In the current study, patient sex had a significant effect on canal morphology as type A canal was more common in men and types B and C were more common in women. However, in a study by Thakur et al, [18] there was no significant relationship between patient sex and canal morphology. This was probably due to racial differences and their smaller sample size (n=100) compared to our study.

In our study, canal length was 14.1±3.0mm on the coronal section. In the study by Song et al, [17] the mean canal length was 11.5mm, while it was 10.99mm in the study by Bornstein et al [16]. A study by Mraiwa et al, [3] found the mean canal length to be 8.1mm. The effect of sex on nasopalatine canal length was not significant in our study while it was significant in the studies by Thakur et al, [18] and Bornstein et al [16]. Different methods of canal length measurement might be responsible for these contradictory results, as we used coronal sections in our study while they measured canal length on sagittal sections [16,18].

Our results showed that incisive foramen sagittal diameter and alveolar bone width anterior to the canal in the upper and lower thirds were significantly different between men and women. But there were no significant differences in alveolar bone width anterior to the canal in the middle third, canal angulation with palate, canal length, incisive foramen coronal diameter, and canal diameter in the floor of the nasal fossa

between men and women. There were significant differences in incisive foramen sagittal diameter and alveolar bone width anterior to the canal in the upper, middle and lower thirds between dentulous and edentulous patients; while, there were no significant differences in canal angulation with horizontal plane, canal length, incisive foramen coronal diameter and canal diameter in the floor of nasal fossa between these two groups. In evaluations on semi-edentulous and edentulous patients with a mean age of 55 years using spiral computed tomography, age, patient sex, and dentition status did not have any significant effects on nasopalatine canal or its corresponding buccal bone [3,18]. The authors related these results to the small sample size. In the study by Bornstein et al, [16] men had a longer nasopalatine canal and age had a significant inverse effect on canal length such that older patients had shorter canals. Similar results have been reported in other studies, which obtained computed tomography scans before implant placement [19-21]. Mardinger et al, [21] also showed that nasopalatine canal dimensions increased with aging. In a study by Liang et al, [22] anatomical variations of nasopalatine canal were evaluated and they reported that canal diameter increased with age in men. On the sagittal view, due to bone loss around incisive foramen, foramen location is more vertical in the nasal fossa of edentulous patients compared to that of dentulous patients. The results from the current study showed that the sagittal diameter of the incisive foramen in edentulous patients was significantly greater than that of the dentulous patients (5.24mm compared to 4.62mm). Bony changes around the incisive canal in the oral cavity are due to tooth loss and it seems that these bony changes modify canal dimensions within the incisive canal. After the loss of the anterior teeth, alveolar bone resorbs primarily from the labial side because the labial cortex of incisors is narrow. Therefore, the location of the alveolar bone cortex in the anterior region changes in the

palatal side. On the other hand, incisive canal shows minimal changes in horizontal direction after anterior tooth loss. This can be the result of significantly lower alveolar bone width in the anterior region of edentulous maxilla compared to dentulous maxilla [4,19]. In the current study, no significant relation was detected between age and nasopalatine canal dimensions except that with aging, alveolar bone width anterior to the canal in the lower third decreased significantly. The differences observed between the results of different studies might have been due to differences in mean patient age or the difference in the distribution of edentulous or dentulous patients. Our results showed a considerable variability in nasopalatine canal morphology among patients, and that CBCT was a valuable imaging modality for determining canal morphology and dimensions before implant placement. It seems that evaluation of canal location and its dimensional properties using CBCT could provide detailed information, which can be used in clinical situations. The observer's performance, reference point selection, mouse sensitivity, and software capabilities in this technique can all affect the accuracy of length measurements. In addition, in order to obtain a proper image, radiologist's skills, appropriate imaging technique, correct patient positioning, and proper exposure settings should be taken into consideration. These factors were not considered in this study as evaluations were performed retrospectively on existed digital files.

REFERENCES

- 1- Teughels W, Merheb J, Quirynen M. Critical horizontal dimensions of interproximal and buccal bone around implants for optimal aesthetic outcomes: a systematic review. *Clin Oral Implants Res.* 2009 Sep; 20(s4):134-45.
- 2- Buser D, Martin W, Belser UC. Optimizing esthetics for implant restorations in the anterior maxilla: anatomic and surgical considerations. *Int J Oral Maxillofac Implants.* 2004 Nov;19(7):43-61.

- 3- Mraiwa N, Jacobs R, Van Cleynenbreugel J, Sanderink G, Schutyser F, Suetens P, et al. The nasopalatine canal revisited using 2D and 3D CT imaging. *Dentomaxillofac Radiol.* 2004 Nov;33(6):396-402.
- 4- Asaumi R, Kawai T, Sato I, Yoshida S, Yosue T. Three-dimensional observation of the incisive canal and the surrounding bone using cone-beam computed tomography. *Oral Radiol.* 2010 Jun;26(1):20-8.
- 5- Tyndall DA, Brooks SL. Selection criteria for dental implant site imaging: a position paper of the American Academy of Oral and Maxillofacial radiology. *Oral Surg Oral Med Oral Pathol Oral Radiol Endod.* 2000 May;89(5):630-7.
- 6- Bou Serhal C, Jacobs R, Persoons M, Hermans R, van Steenberghe D. The accuracy of spiral tomography to assess bone quantity for the preoperative planning of implants in the posterior maxilla. *Clin Oral Implants Res.* 2000 Jun;11(3):242-7.
- 7- Loubele M, Guerrero ME, Jacobs R, Suetens P, van Steenberghe D. A comparison of jaw dimensional and quality assessments of bone characteristics with cone-beam CT, spiral tomography, and multi-slice spiral CT. *Int J Oral Maxillofac Implants.* 2007 May-Jun;22(3):446-54.
- 8- Chatriyanuyoke P, Lu CI, Suzuki Y, Lozada JL, Rungcharassaeng K, Kan JY, et al. Nasopalatine canal position relative to the maxillary central incisors: a cone beam computed tomography assessment. *J Oral Implantol.* 2012 Dec;38(6):713-7.
- 9- Gupta J, Ali SP. Cone beam computed tomography in oral implants. *Natl J Maxillofac Surg.* 2013 Jan;4(1):2-6.
- 10- Ludlow JB, Davies-Ludlow LE, Brooks SL. Dosimetry of two extraoral direct digital imaging devices: NewTom cone beam CT and Orthophos Plus DS panoramic unit. *Dentomaxillofac Radiol.* 2003 Jul;32(4):229-34.
- 11- Farman AG. ALARA still applies. *Oral Surg Oral Med Oral Pathol Oral Radiol Endod.* 2005 Oct;100(4):395-7.
- 12- Artzi Z, Nemcovsky CE, Bitlitum I, Segal P. Displacement of the incisive foramen in conjunction with implant placement in the anterior maxilla without jeopardizing vitality of nasopalatine nerve and vessels: a novel surgical approach. *Clin Oral Implants Res.* 2000 Oct;11(5):505-10.
- 13- Rosenquist JB, Nyström E. Occlusion of the incisal canal with bone chips. A procedure to facilitate insertion of implants in the anterior maxilla. *Int J Oral Maxillofac Surg.* 1992 Aug;21(4):210-1.
- 14- Scher EL. Use of the incisive canal as a recipient site for root form implants: preliminary clinical reports. *Implant Dent.* 1994 Spring;3(1):38-41.
- 15- Peñarrocha M, Carrillo C, Uribe R, García B. The nasopalatine canal as an anatomic buttress for implant placement in the severely atrophic maxilla: a pilot study. *Int J Oral Maxillofac Implants.* 2009 Sep-Oct;24(5):936-42.
- 16- Bornstein MM, Balsiger R, Sendi P, von Arx T. Morphology of the nasopalatine canal and dental implant surgery: a radiographic analysis of 100 consecutive patients using limited cone-beam computed tomography. *Clin Oral Implants Res.* 2011 Mar;22(3):295-301.
- 17- Song WC, Jo DI, Lee JY, Kim JN, Hur MS, Hu KS, et al. Microanatomy of the incisive canal using three-dimensional reconstruction of microCT images: an ex vivo study. *Oral Surg Oral Med Oral Pathol Oral Radiol Endod.* 2009 Oct;108(4):583-90.
- 18- Thakur AR, Burde K, Guttal K, Naikmasur VG. Anatomy and morphology of the nasopalatine canal using cone-beam computed tomography. *Imaging Sci Dent.* 2013 Dec;43(4):273-81.
- 19- Jia X, Hu W, Meng H. Relationship of central incisor implant placement to the ridge configuration anterior to the nasopalatine canal in dentate and partially edentulous individuals: a comparative study. *Peer J.* 2015 Nov;3:e1315.
- 20- Fernández-Alonso A, Suárez-Quintanilla JA, Muínelo-Lorenzo J, Varela-Mallou J, Smyth Chamosa E, Suárez-Cunqueiro MM. Critical anatomic region of nasopalatine canal based on tridimensional analysis: cone beam computed tomography. *Sci Rep.* 2015 Aug;5:12568.
- 21- Mardinger O, Namani-Sadan N, Chaushu G, Schwartz-Arad D. Morphologic changes of the

nasopalatine canal related to dental implantation: a radiologic study in different degrees of absorbed maxillae. *J Periodontol.* 2008 Sep;79(9):1659-62.
22- Liang X, Jacobs R, Martens W, Hu Y,

Adriaensens P, Quirynen M, et al. Macro- and micro-anatomical, histological and computed tomography scan characterization of the nasopalatine canal. *J Clin Periodontol.* 2009 Jul;36(7):598-603.