

Accuracy of Linear Measurements Using Cone Beam Computed Tomography in Comparison with Clinical Measurements

Amir Reza Rohn¹, Kazem Hashemi^{2✉}, Solmaz Akbari³, Mohammad Javad Kharazifard⁴, Hamidreza Barikani⁵, Mehrdad Panjnoosh⁶

¹ Professor, Dental Implant Research Center, Dentistry Research Institute, Tehran University of Medical Sciences, Tehran, Iran; Department of Periodontics, School of Dentistry, Tehran University of Medical Sciences, Tehran, Iran

² Postdoc Student, Dental Implant Research Center, Dentistry Research Institute, Tehran University of Medical Sciences, Tehran, Iran

³ Assistant Professor, Dental Implant Research Center, Dentistry Research Institute, Tehran University of Medical Sciences, Tehran, Iran; Department of Periodontics, School of Dentistry, Tehran University of Medical Sciences, Tehran, Iran

⁴ Epidemiologist, Dental Research Center, Dentistry Research Institute, Tehran University of Medical Sciences, Tehran, Iran

⁵ Researcher, Dental Implant Research Center, Dentistry Research Institute, Tehran University of Medical Sciences, Tehran, Iran

⁶ Assistant Professor, Head of Department of Oral and Maxillofacial Radiology, School of Dentistry, Tehran University of Medical Sciences, Tehran, Iran

Abstract

Objectives: This study sought to evaluate the accuracy and errors of linear measurements of mesiodistal dimensions of Kennedy Class III edentulous space using cone beam computed tomography (CBCT) in comparison with clinical measurements.

Materials and Methods: Nineteen Kennedy Class III dental arches were evaluated. An impression was made of each dental arch and poured with dental stone. The distance was measured on dental cast using a digital Vernier caliper with an accuracy of 0.1mm and on CBCT scans. Finally, the linear mesiodistal measurements were compared and the accuracy of CBCT technique was evaluated by calculating absolute value of errors, intra-class correlation coefficient and simple linear regression model.

Results: In comparison with the cast method, estimation of size on CBCT scans had an error of -8.46% (underestimation) to 5.21% (overestimation). In 26.5% of the cases, an accepted error of $\pm 1\%$ was found. The absolute value of errors was found to be in the range of 0.21-8.46mm with an average value of 2.86 ± 2.30 mm.

Conclusions: Although the measurements revealed statistically significant differences, this does not indicate a lower accuracy for the CBCT technique. In fact, CBCT can provide some information as a paraclinical tool and the clinician can combine these data with clinical data and achieve greater accuracy. Undoubtedly, calibration of data collected by clinical and paraclinical techniques and the clinician's expertise in use of CBCT software programs can increase the accuracy of implant placement.

Keywords: Cone-Beam Computed Tomography; Dental Arch; Dimensional Measurement Accuracy

Journal of Dentistry, Tehran University of Medical Sciences, Tehran, Iran (2016; Vol. 13, No. 5)

✉ Corresponding author:
K. Hashemi, Dental Implant
Research Center, Dental School
Tehran University of Medical
Sciences, Tehran, Iran

kazemhashemi45@gmail.com

Received: 2 February 2016

Accepted: 26 June 2016

INTRODUCTION

Adjunct techniques are necessary to evaluate the quality and quantity of bone so that a proper treatment plan can be offered for implant placement [1,2]. Panoramic X-ray units have an inherent distortion, which is influenced by some factors; for example, a change in the patient's head position results in measurement errors [3]. Apart from distortion, magnification of panoramic radiographs may result in a change in treatment plan [4,5]. On the other hand, computed tomography (CT) has lower accuracy

compared to cone beam computed tomography (CBCT) [3,6]; CBCT images have characteristics such as accuracy and clarity [7]. The first CBCT scanners were introduced almost three decades ago [8]; CBCT was first introduced in 1982 for angiography procedures [9]. Its first application in dentistry occurred in 2000 in Loma Linda University [10]. Evaluation of alveolar bone is very important for dental implant treatment planning [1-3]. The CT scan technique has been reported to be the best preoperative technique for evaluation of three-dimensional morphology and

measurements [1-3]. Many studies have reported that panoramic radiography is a reliable technique for evaluation of bone height [11,12]. To achieve optimal functional and esthetic results, dental implant should be placed accurately in the desired area [13]. Existing technologies such as CBCT, in conjunction with virtual three-dimensional reconstruction of implant placement and fabrication of surgical templates with stereolithography are used in both treatment planning and implant placement. However, the accuracy of CBCT technique is unknown [13] and even with the use of this system, errors of 1.5mm and 1mm have been reported in horizontal and vertical dimensions [14,15]. Errors of 0.65–1.78mm have been reported for the CBCT technique. The advantages of CBCT include high resolution, lower cost, lower radiation dose, rapid scanning, easy handling and availability in comparison with the CT technique [16,17]. Different CBCT machines have differences in their exposure parameters including voltage, tube current, exposure, field of view and extent of gantry rotation around the patient's head, resulting in differences in absorbed radiation dose and the quality of images produced [18,19].

The aim of the present study was to evaluate the accuracy of mesiodistal linear measurements made using CBCT technique in the edentulous space in rehabilitation treatments using dental implants.

MATERIALS AND METHODS

The samples consisted of 18 patients and 19 casts with Kennedy Class III edentulous space with at least two lost teeth; two edentulous areas were evaluated in one patient and the respective casts. The sample size was determined based on a pilot study with five samples. The patients were selected among those referring to the Department of Implantology, School of Dentistry, Tehran University of Medical Sciences. This study was approved by the Ethics Committee of Tehran

University of Medical Sciences (Code number: 14701).

An impression was taken from the edentulous area using polyether impression material due to its high accuracy and low volumetric change. The impressions were poured with dental stone due to its high resistance and low volumetric change, according to manufacturer's instructions. Then, the patients were referred to the Department of Radiology to take CBCT scans of the edentulous area. The CBCT scans were taken using a volumetric tomography machine (Promax 3D; Planmeca, Helsinki, Finland). An important consideration is the fact that evaluation of the edentulous space of one lost tooth from a clinical and practical point of view and its relationship with the accuracy of CBCT might not be statistically significant due to the short span of the edentulous space or in other words due to the small width of the tooth lost; therefore, the space created by the loss of two teeth was evaluated in the present study. Age and sex are not important in such evaluations and measurements because the aim of such studies is to measure the linear distance between two teeth using two different techniques and compare the obtained results. The buccolingual or buccopalatal center of the stone cast was determined by the clinician using welding wire with proper flexion properties. The wire was adapted to the buccolingual center and measured with a digital Vernier caliper with an accuracy of 0.1mm. It was straight in some cases and curved in some others. On the other hand, the same distance was measured on CBCT scans by a radiologist using the relevant software program with 0.1mm accuracy. Since no similar study was available, a pilot study was carried out on five samples to calculate the sample size. The mean and standard deviation of linear measurements made on CBCT scans and by the clinical technique were calculated. The mean difference in measurements made on the cast and on CBCT scans in the pilot study was 1.7mm with a

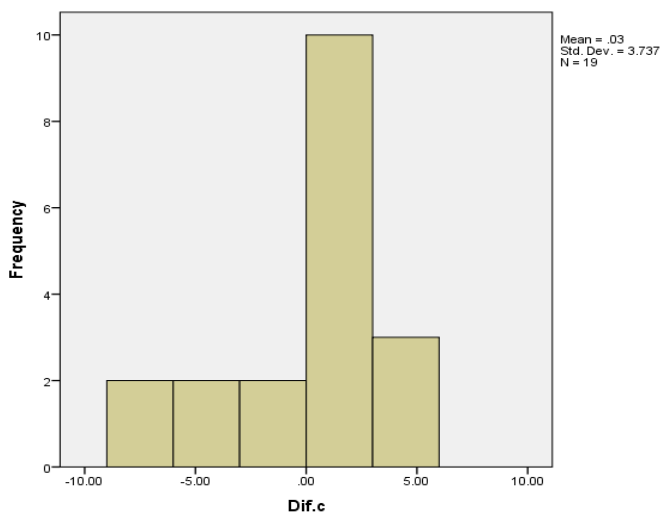


Fig. 1: The histogram of the differences between CBCT and cast measurements of curved lines (Dif.c)

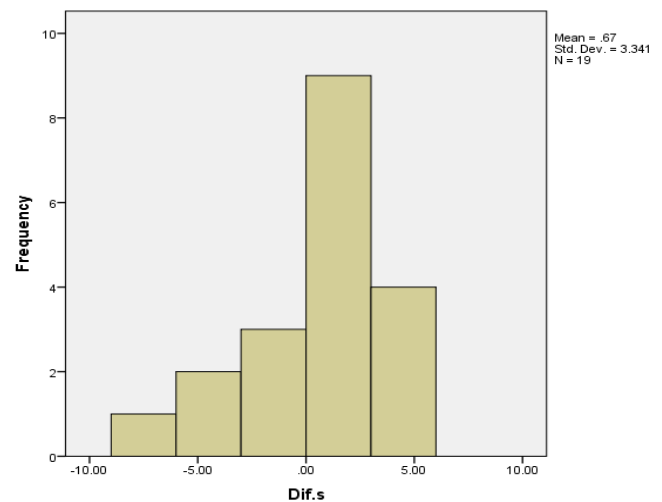


Fig. 2: The histogram of the differences between CBCT and cast measurements of straight lines (Dif.s)

variance of approximately 1mm. Therefore, at a confidence interval of 0.99 and test power of 0.99, the number of samples was found to be 10.

Statistical analysis:

Crude value of error was obtained from the difference between the values measured on CBCT scans and dental casts. Also, absolute crude value was considered as absolute value of error. Intraclass correlation coefficient and simple linear regression model were used to determine the mean of measurements and estimate the true values from data obtained by the CBCT method, respectively.

RESULTS

The samples consisted of 19 casts; of which, 12 casts (63.2%) were maxillary and seven casts (36.8%) were mandibular. Of all the casts, eight casts (42.1%) had edentulous spaces of two teeth, seven casts (36.8%) had edentulous spaces of three teeth, three casts (15.8%) had edentulous spaces of four teeth and one cast (5.3%) had an edentulous space of five teeth. In comparison with the cast method, estimation of size using CBCT method had an error of -8.46% (underestimation) to 5.21% (overestimation). For

26.5 % of cases, an accepted error of $\pm 1\%$ was found. Also, in straight (versus curved) cases, an error range of -8.29% (underestimation) to 5.21% (overestimation) was observed.

Furthermore, an accepted error of $\pm 1\%$ was observed for 15.9% of cases. In this study, the absolute value of errors was found to be in the range of 0.21-8.46mm with an average value of 2.86 ± 2.30 mm. Also, the value of error was 3.74 ± 0.03 mm for curved cases. In the straight cases, an absolute error range of 0.34 to 8.29mm with an average of 2.64 ± 2.07 mm was obtained (Figs. 1 and 2). The intraclass correlation coefficient value was 0.804 and 0.730, respectively for the agreement between CBCT measurements and the values for straight and curved cases. These findings showed higher agreement between CBCT measurements and values measured on dental casts for straight cases ($P < 0.001$).

A linear regression equation of size on cast = size on CBCT scan $\times 0.74 + 5.76$ ($R^2 = 0.53$) was obtained for the best estimation of true size from the size measured on CBCT scans ($P < 0.001$).

DISCUSSION

In the present study, the accuracy of measuring

the mesiodistal distance of edentulous spaces by CBCT technique was evaluated. Space management and force distribution on implants and decreasing the cantilever length are important major issues in treatment planning for dental implants. At present, CBCT is considered as a paraclinical tool to increase the accuracy and decrease the length of clinical procedures by eliminating the need for bone mapping, leading to a better treatment plan. A large number of studies have been carried out on the accuracy and validity of the measurements of vertical dimension and thickness of bone [1,5,20]. To the best of our knowledge, no data were brought up in relation to the accuracy of CBCT for mesiodistal or horizontal dimensional measurements. The majority of measurements relate to orthodontic landmarks, i.e. the majority of studies have used full CBCT or ortho-facial systems and conventional dental radiography has been used less frequently.

Undoubtedly, in such studies, it is advisable to use anthropometric characteristics. The advantage of the present study was that it allowed an indirect anthropometric assessment. As explained in the "results" section, there were significant differences in measurements made between the two techniques, which were consistent with the results of some previous studies [1,5,20]. What is important in the accuracy of linear measurements in implant treatments, as shown in previous studies [1,5,20], is that the differences between CBCT measurements or other radiographic techniques such as CT and clinical measurements might be statistically significant but clinically and practically acceptable, which means they might not be clinically important [1,5]. Therefore, calibration method of such studies is very important. Lascala et al. [20] carried out a study on 13 measurements in eight skulls; an important finding was the fact that actual measurements were greater than CBCT measurements, with significant differences. Such results were

expected because NewTom 9000 CBCT unit was used, which is specifically used for dentomaxillofacial imaging. In studies on horizontal distances, the extent of the area is very important and small or medium-sized areas exhibit differences from larger areas. An important consideration in such studies is lack of sensitivity to detect small differences in accuracy. In fact, statistical criteria affect the evaluations, and even the results achieved by different CBCT units might be different due to differences in software and hardware capabilities [6,20]. Another important consideration in studies on the accuracy of CBCT is the method error, which reflects the limitations of CBCT and the software programs used. In three-dimensional images, the method error depends on factors such as resolution (voxel size) and the size of the landmarks in question. It should be noted that the radiolucency of the markers measured increases error [21,22].

A change in skull orientation does not influence the accuracy of linear measurements [1]; however, the results of a study in 2013 showed that a change in position during acquisition might result in changes in width and height, especially in the upper jaw and particularly in molar and premolar areas [3]. In addition, the operator's experience affects the accuracy [21]; although another study showed that high reliability can be achieved without formal software training [22]. Based on the above discussion, CBCT is still the best tool for preoperative assessment for rehabilitative treatments with dental implants and it can provide three-dimensional images of the mineralized tissue with minimum distortion [23,24]. In the current study, the majority of the evaluated edentulous spaces were in the upper jaw (12 spaces vs. seven spaces in the lower jaw). In the upper jaw, in five cases, the differences in measurements made on CBCT scans and on dental casts were more than 1mm; in three cases the measurements on casts were 1mm larger than those on CBCT scans and in four cases they were

less than 1mm. In the lower jaw, the differences in three CBCT cases and in three cast cases were more than 1mm and in one case less than 1mm. These differences can be explained by considering the differences in the number of evaluated cases in the upper and lower jaws. No significant relationship was found between the size of the edentulous area and the differences between the two measurement techniques; however, the error level decreased with an increase in the number of lost teeth. However, the sample size should increase for more accurate evaluations. What should be taken into account in clinical evaluations is the fact that measurements are made on the most superficial layer of soft tissues, which affects the numerical values obtained because the amount of gingival recession after bone resorption or an increase in gingival volume, irrespective of the reason, affects the data collected. As mentioned previously, depending on the type of the CBCT unit used (i.e. detector type, which might be intensifier or flat panel), there will be some degrees of deformity. In the current study, a Planmeca CBCT unit, which was flat panel with high accuracy was used. However, what should be considered is the fact that all the CBCT measurements were made on the axial view of different sections, which might have affected the numerical data values. On the other hand, the area selected for the initiation (clicking point) of measurements is important in terms of coronal and buccolingual (or buccopalatal) height. The following conclusions can be drawn from the results of the present study:

- The clinician should be familiar with the CBCT principles and software programs and should properly use them.
- Clinical and radiographic evaluations should be calibrated with each other.
- What is important for the number of dental implants and their distribution is not solely the size of the arch involved; the shape of the

arch, as well as the sizes and the diameters of the implants are also important [25].

- It should be emphasized that generally, paraclinical examinations are adjunctive tools and do not have an effective and accurate application alone in the clinical setting; but if acquisition protocols are followed precisely they will certainly be more reliable. What is important is the effect of artifacts on the CBT technique [4]. Therefore, depending on the involved area, the error level might be different. For example, the original value might be less than that measured on CBCT scans and the range of this increase might be 90–100% due to the higher density of obturated root canals, leading to artifacts and errors [26].

In general, CBCT provides some data for the clinician, which might be under the influence of the type of the section (oblique or vertical), the view in question (axial or panoramic) and buccolingual or occlusogingival direction. Finally, the clinician should use the data correctly. The results of this study showed that CBCT had lower error rate in measuring straight lines than curved lines.

CONCLUSION

Evaluation of the accuracy of CBCT technique by comparing the linear distance of the mesiodistal edentulous space between two teeth measured on the casts and on CBCT scans yielded the following results:

The CBCT unit used was highly accurate; however, its application in the clinical setting requires operator's skills and his/her familiarity with CBCT software programs. Attention to the calibration of the data acquired by clinical examination and CBCT is very important.

REFERENCES

- 1- Sato S, Arai Y, Shinoda K, Ito K. Clinical application of a new cone-beam computerized

- tomography system to assess multiple two-dimensional images for the preoperative treatment planning of maxillary implants: case reports. *Quintessence Int.* 2004 Jul-Aug;35(7):525-8.
- 2- Schropp L, Stavropoulos A, Gotfredsen E, Wenzel A. Comparison of panoramic and conventional cross-sectional tomography for preoperative selection of implant size. *Clin Oral Implants Res.* 2011 Apr;22(4):424-9.
- 3- Hardy TC, Suri L, Stark P. Influence of patient head positioning on measured axial tooth inclination in panoramic radiography. *J Orthod.* 2009 Jun;36(2):103-10.
- 4- Liang H, Frederiksen NL. Focal trough and patient positioning. *Dentomaxillofac Radiol.* 2004 Mar;33(2):128-9.
- 5- Nishikawa K, Suehiro A, Sekine H, Kousuge Y, Wakoh M, Sano T. Is linear distance measured by panoramic radiography reliable? *Oral Radiol.* 2010 Jun;26(1):16-9.
- 6- Kobayashi K, Shimoda S, Nakagawa Y, Yamamoto A. Accuracy in measurement of distance using limited cone-beam computerized tomography. *Int J Oral Maxillofac Implants.* 2004 Mar-Apr;19(2):228-31.
- 7- Visconti MA, Verner FS, Assis NM, Devito KL. Influence of maxillomandibular positioning in cone beam computed tomography for implant planning. *Int J Oral Maxillofac Surg.* 2013 Jul;42(7):880-6.
- 8- Ritman EL, Kinsey JH, Robb RA, Harris LD, Gilbert BK. Physics and technical considerations in the design of the DSR: a high temporal resolution volume scanner. *AJR Am J Roentgenol.* 1980 Feb;134(2):369-74.
- 9- Robb RA, Sinak LJ, Hoffman EA, Kinsey JH, Harris LD, Ritman EL. Dynamic volume imaging of moving organs. *J Med Syst.* 1982 Dec;6(6):539-54.
- 10- Mah J, Hatcher D. Three-dimensional craniofacial imaging. *Am J Orthod Dentofacial Orthop.* 2004 Sep;126(3):308-9.
- 11- Akdeniz BG, Oksan T, Kovanlikaya I, Genç I. Evaluation of bone height and bone density by computed tomography and panoramic radiography for implant recipient sites. *J Oral Implantol.* 2000 Apr;26(2):114-9.
- 12- Frei C, Buser D, Dula K. Study on the necessity for cross-section imaging of the posterior mandible for treatment planning of standard cases in implant dentistry. *Clin Oral Implants Res.* 2004 Aug;15(4):490-7.
- 13- Cushen SE, Turkyilmaz I. Impact of operator experience on the accuracy of implant placement with stereolithographic surgical templates: an in vitro study. *J Prosthet Dent.* 2013 Apr;109(4):248-54.
- 14- Jabero M, Sarment DP. Advanced surgical guidance technology: a review. *Implant Dent.* 2006 Jun;15(2):135-42.
- 15- Loubele M, Bogaerts R, Van Dijck E, Pauwels R, Vanheusden S, Suetens P, et al. Comparison between effective radiation dose of CBCT and MSCT scanners for dentomaxillofacial applications. *Eur J Radiol.* 2009 Sep;71(3):461-8.
- 16- Patel S, Dawood A, Ford TP, Whaites E. The potential applications of cone beam computed tomography in the management of endodontic problems. *Int Endod J.* 2007 Oct;40(10):818-30.
- 17- Kamburoğlu K, Murat S, Yüksel SP, Cebeci AR, Paksoy CS. Occlusal caries detection by using a cone-beam CT with different voxel resolutions and a digital intraoral sensor. *Oral Surg Oral Med Oral Pathol Oral Radiol Endod.* 2010 May;109(5):e63-9.
- 18- Pauwels R, Beinsberger J, Collaert B, Theodorakou C, Rogers J, Walker A, et al. Effective dose range for dental cone beam computed tomography scanners. *Eur J Radiol.* 2012 Feb;81(2):267-71.
- 19- Dawood A, Brown J, Sauret-Jackson V, Purkayastha S. Optimization of cone beam CT exposure for pre-surgical evaluation of the implant site. *Dentomaxillofac Radiol.* 2012 Jan;41(1):70-4.
- 20- Lascala CA, Panella J, Marques MM. Analysis of the accuracy of linear measurements obtained by cone beam computed tomography (CBCT-New Tom). *Dentomaxillofac Radiol.* 2004 Sep;33(5):291-4.
- 21- Ludlow JB, Laster WS, See M, Bailey LJ, Hershey HG. Accuracy of measurements of mandibular anatomy in cone beam computed tomography images. *Oral Surg Oral Med Oral Pathol Oral Radiol Endod.* 2007 Apr;103(4):534-42.

- 22- Pinsky HM, Dyda S, Pinsky RW, Misch KA, Sarment DP. Accuracy of three-dimensional measurements using cone-beam CT. *Dentomaxillofac Radiol.* 2006 Nov;35(6):410-6.
- 23- van Vlijmen OJ, Bergé SJ, Bronkhorst EM, Swennen GR, Katsaros C, Kuijpers-Jagtman AM. A comparison of frontal radiographs obtained from cone beam CT scans and conventional frontal radiographs of human skulls. *Int J Oral Maxillofac Surg.* 2009 Jul;38(7):773-8.
- 24- Wittwer G, Adeyemo WL, Beinemann J, Juergens P. Evaluation of risk of injury to the inferior alveolar nerve with classical sagittal split osteotomy technique and proposed alternative surgical techniques using computer-assisted surgery. *Int J Oral Maxillofac Surg.* 2012 Jan;41(1):79-86.
- 25- Misch CE. *Contemporary Implant Dentistry.* Implant Dent. 1999 Jan;8(1):90.
- 26- Decurcio DA, Bueno MR, de Alencar AH, Porto OC, Azevedo BC, Estrela C. Effect of root canal filling materials on dimensions of cone-beam computed tomography images. *J Appl Oral Sci.* 2012 Mar-Apr;20(2):260-7.