



# Reconstruction of a Mandibular Defect with Toronto Bridge Following Tumor Resection and Bone Graft: A Case Report

Hakimeh Siadat<sup>1</sup>, Arash Khojasteh<sup>2</sup>, Elaheh Beyabanaki<sup>3\*</sup>

1. Dental Research Center, Dentistry Research Institute, Tehran University of Medical Sciences, Tehran, Iran; Department of Prosthodontics, School of Dentistry, Tehran University of Medical Sciences, Tehran, Iran
2. Department of Oral and Maxillofacial Surgery, School of Dentistry, Shahid Beheshti University of Medical Sciences, Tehran, Iran
3. Department of Prosthodontics, School of Dentistry, Shahid Beheshti University of Medical Sciences, Tehran, Iran

## Article Info

**Article type:**  
Case Report

### Article History:

Received: 18 April 2018  
Accepted: 8 July 2018  
Published: 30 April 2019

### \* Corresponding author:

Department of Prosthodontics, School of Dentistry, Shahid Beheshti University of Medical Sciences, Tehran, Iran

E-mail: e.beyabanaki@gmail.com

## ABSTRACT

Dental implants are highly recommended to improve the retention, stability, and support of prostheses in edentulous patients with large surgical defects. Depending on the size of the defect, a bone graft procedure might be necessary. However, due to limitations of bone grafts, some complications might negatively affect the prosthetic rehabilitation of the patient. This case report presents some of these prosthetic problems following surgical resection and autogenous bone graft procedures.

**Keywords:** Dental Implant; Giant Cell Granuloma; Bone Transplantation; Resection Margin; Implant-Supported Prosthesis

- **Cite this article as:** Siadat H, Khojasteh A, Beyabanaki E. Reconstruction of a Mandibular Defect with Toronto Bridge Following Tumor Resection and Bone Graft: A Case Report. *Front Dent.* 2019;16(2):153-157. doi: 10.18502/fid.v16i2.1368

## INTRODUCTION

Surgical treatment of resected cases usually leaves a considerable defect in the jaw that could affect the function, aesthetics, and quality of life of the patients [1]. With the use of implant-supported prostheses after fusion of a bone graft to the remaining jawbone, acceptable aesthetics and function could be predicted [2]. Implant-supported prostheses have shown successful results in patients with reconstructed jaws [2-7]. However, selecting a specific prosthetic design requires the consideration of different aspects such as the crown height space, the relationship between the upper and lower jaws, the number and position of the implants, as well as patient-related factors including the cooperation in oral

hygiene and prosthesis maintenance, financial status, and the patient's demand [8-10]. Implant-supported prostheses can be divided into fixed (cement-retained, screw-retained, and Toronto Bridge) and removable restorations [10,11]. Toronto Bridge is a dual retention prosthesis that includes a screw-retained framework with cement-retained crowns; it is used in cases with increased crown height space [10,11]. Central giant cell granuloma (CGCG) is an uncommon, benign, intra-osseous non-odontogenic tumor limited to the head and neck region and is more common in the mandible and in females [12-14]. It is frequently diagnosed in the second or third decades of life [14]. The standard treatment regimen comprises curettage and surgical

resection followed by a reconstructive procedure, including distraction osteogenesis, tissue engineering, modular endoprosthesis or placing a free bone graft in the mandible for large defects [15,16]. Autogenous bone grafts are still the gold standard for alveolar augmentation.

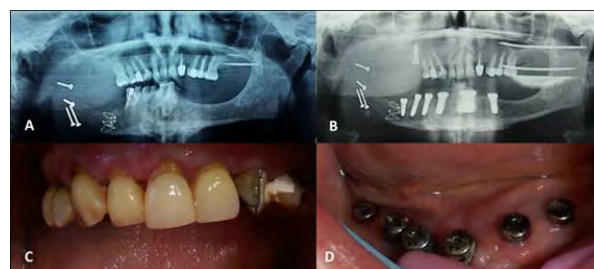
The cumulative survival rate for dental implants is reported to be the same for the native and grafted sites [3-5]. Also, implant-supported prostheses could participate in lowering the rate of bone graft resorption [17]. Extraoral sources are selected for providing greater bulk for jawbone reconstruction; however, they could be associated with considerable resorption during healing [6,7]. The case presented here had a mandibular bone defect due to surgical resection of a CGCG, which was enhanced by an autogenous rib bone graft. The treatment was continued with the placement of dental implants and a fixed implant-supported prosthesis due to the unstable position of the jaw upon movement. Toronto Bridge was selected as the prosthesis of choice because of the increased crown height space.

#### CASE REPORT

A 59-year-old female with a history of segmental mandibular resection due to a CGCG and bone graft surgery was referred for prosthetic rehabilitation. After one year and a half, the bone graft was displaced and loosened due to the recurrence of the tumor in the symphysis area. Therefore, after shaving the affected bone, the graft was fixated. Following graft fixation and extraction of the mandibular teeth due to being either mobile or un-restorable, they were replaced with six dental implants (Fig. 1. A to D).

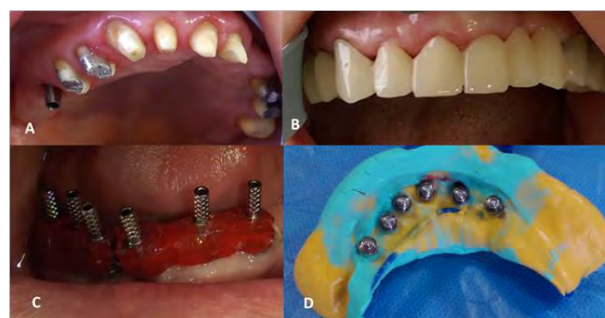
The treatment plan suggesting the use of a mandibular implant-supported overdenture was ruled out because the patient demanded a fixed prosthesis; also, a removable prosthesis could increase the risk of bone graft resorption. Also, the severe right-to-left jaw deviation upon guidance to the centric relation (CR) resulted in severe anterior overjet and posterior crossbite which would have made it impossible to establish a balanced occlusion. Six regular-neck implants (SuperLine II, Dentium Co. Ltd., Seoul, South Korea), 4.8 mm in diameter and 10 mm in height, were placed at the site of teeth #22, #23, #26, #27, #28, and #30.

Showing guarded prognosis, the maxillary left



**Fig. 1.** (A) Panoramic view of the jaws before the treatment. (B) Panoramic view of the jaws after fixating the graft and implant surgery. (C) Intraoral view of the maxillary teeth before the treatment. (D) Occlusal view of mandibular implants.

lateral incisor, canine and right first molar were extracted. The other maxillary teeth were saved and treated with root canal therapy, crown lengthening surgery, and computer-aided design/computer-aided manufacturing (CAD/CAM) temporary restorations (Fig. 2. A and B).

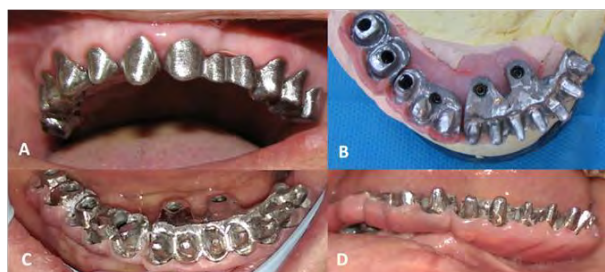


**Fig. 2.** (A) Prepared maxillary teeth. (B) Temporary computer-aided design/computer-aided manufacturing (CAD/CAM) restorations for maxillary teeth. (C) Splinted open impression copings. (D) The final impression of the lower jaw.

A mandibular complete denture was also made for the patient to make her able to chew during the healing period of dental implants. However, due to the muscle resection, the stability of the CR and regular mandibular movements were compromised. Four months later, the mandibular final impression was made using the splinted open tray technique (Fig. 2. C and D) [18].

After establishing vertical and horizontal jaw relations using a mandibular record base, the Toronto Bridge was chosen due to the excessive crown height space. After try-in of the acrylic resin pattern of the mandibular three-segmented Toronto prosthesis using customized abutments (Metal-Casting Abutment, SuperLine II, Dentium Co. Ltd., Seoul,

South Korea) with a 4.5-mm diameter, casting was performed using base metal alloy. The maxillary and mandibular metal frameworks were tried in the mouth for adaptation (Fig. 3. A).

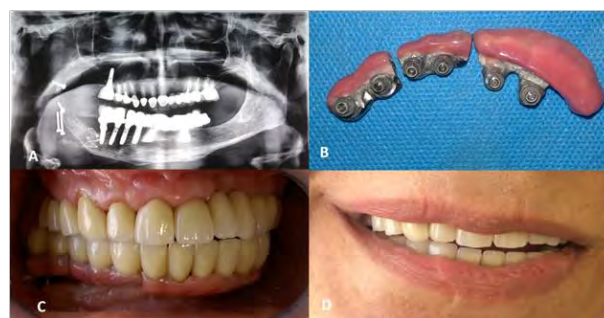

**Fig. 3.** (A) Try-in of maxillary metal frameworks. (B) Implant-supported metal frameworks, showing the buccolingual and distal cantilevers. (C) Try-in of metal frameworks. (D) The pink composite used for covering the gingival portion of the metal frameworks.

The left segment inevitably resulted in two cantilevers: first, an anterior cantilever due to the lingual positioning of the implant to achieve an acceptable horizontal overlap, and second, a distal cantilever extending to the second premolar for making occlusal contact with the upper teeth (Fig. 3. B and C). After fabrication of individual metal-ceramic crowns, the gingival part of the framework was covered with a pink laboratory composite (Fig. 3. C and D). After trying the crowns and making the necessary occlusal and proximal adjustments, the metal mesostructure was fastened with a 30-N.cm (Newton Centimeter) torque. The crowns were cemented using a temporary cement [19], and the baseline radiograph was taken (Fig. 4. A and B). Oral hygiene instructions for using Superfloss (Oral-B Inc., Iowa City, IA, USA) and an oral irrigator were given to the patient. Six and 12 months later, the patient was followed-up, and there were no functional or hygienic problems (Fig. 4. C and D).

## DISCUSSION

The present case suffered from a major mandibular defect following the resection of a CGCG and bone graft surgeries. After neuromuscular impairment due to tumor resection, the patient showed problems in controlling the jaw movement and establishing a stable CR. Therefore, removable conventional dentures could not have been tolerated or functioned satisfactorily.



**Fig. 4.** (A) Panoramic view of the final restoration after delivery. (B) The final implant-supported Toronto prostheses. (C) Frontal view of maxillary and mandibular restorations after delivery. (D) Smile view.

Also, when an edentulous mandible opposes a dentate maxilla, a single denture, even when supported by dental implants, could hardly be a suitable long-term treatment option. Since dental implants have shown high long-term success and survival rates in reconstructed jaws, implant-supported prostheses are highly recommended [2]. An implant-supported fixed prosthesis is the first treatment choice in resected/reconstructed jaws and could be advantageous for preventing further bone loss (compared to removable prostheses) [20]. According to Aghaloo and Moby [21], the residual bone supporting the implant is a more important factor in implant survival than the grafted bone itself. However, bone graft placement is usually necessary before implant placement to ensure a proper angulation, suitable diameter and length, and a proper number of implants at appropriate sites [6,7]. The condition of the jaws in the present case necessitated the use of a fixed implant-supported prosthesis designed for an excessive crown height space. The increased vertical space could have been the result of bone graft resorption and the 6-month delay between bone graft placement and implant placement procedures [22].

Considering the limitations of bone grafts in completely simulating the shape and curve of the mandibular arch, it was not possible to place the implants at optimal sites (buccolingually and mediolaterally). Implants with inappropriate positions could create aesthetic problems due to the labial position of the screw connection of the abutments. Also, some biomechanical disadvantages could be anticipated due to the presence of cantilevers

[23]. By magnifying the forces applied to the implants, the cantilevers have the potential to possibly jeopardize the long-term success of the implants if not managed properly [24]. Therefore, long-term follow-ups, including clinical and radiographical evaluations, are required to ensure that the bone loss around the implants is controlled.

## CONCLUSION

Toronto prosthesis is usually used when there is an excess vertical space. The excessive vertical space might be the result of bone loss after a tumor resection. This case described restoration of an edentulous mandible in a patient with the history of CGCG removal and bone graft surgery. Since the anterior implants were placed lingually, an anterior cantilever was considered to achieve an acceptable horizontal overlap.

## CONFLICT OF INTEREST STATEMENT

None declared.

## REFERENCES

1. Ndukwe KC, Aregbesola SB, Ikem IC, Ugboko VI, Adebisi KE, Fatusi OA, et al. Reconstruction of Mandibular Defects Using Nonvascularized Autogenous Bone Graft in Nigerians. *Niger J Surg.* 2014 Jul-Dec;20(2):87-91.
2. Chiapasco M, Colletti G, Romeo E, Zaniboni M, Brusati R. Long-term results of mandibular reconstruction with autogenous bone grafts and oral implants after tumor resection. *Clin Oral Implants Res.* 2008 Oct;19(10):1074-80.
3. Navarro Cuellar C, Caicoya SJ, Acero Sanz JJ, Navarro Cuellar I, Muela CM, Navarro Vila C. Mandibular reconstruction with iliac crest free flap, nasolabial flap, and osseointegrated implants. *J Oral Maxillofac Surg.* 2014 Jun;72(6):1226.e1-15.
4. Sbordone L, Toti P, Menchini-Fabris G, Sbordone C, Guidetti F. Implant survival in maxillary and mandibular osseous onlay grafts and native bone: a 3-year clinical and computerized tomographic follow-up. *Int J Oral Maxillofac Implants.* 2009 Jul-Aug;24(4):695-703.
5. Zouhary KJ. Bone graft harvesting from distant sites: concepts and techniques. *Oral Maxillofac Surg Clin North Am.* 2010 Aug;22(3):301-16.
6. Mertens C, Decker C, Seeberger R, Hoffmann J, Sander A, Freier K. Early bone resorption after vertical bone augmentation--a comparison of calvarial and iliac grafts. *Clin Oral Implants Res.* 2013 Jul;24(7):820-5.
7. Chiapasco M, Zaniboni M, Boisco M. Augmentation procedures for the rehabilitation of deficient edentulous ridges with oral implants. *Clin Oral Implants Res.* 2006 Oct;17(Suppl 2):136-59.
8. Berglundh T, Persson L, Klinge B. A systematic review of the incidence of biological and technical complications in implant dentistry reported in prospective longitudinal studies of at least 5 years. *J Clin Periodontol.* 2002;29(Suppl 3):197-212.
9. Goodacre CJ, Bernal G, Rungcharassaeng K, Kan JY. Clinical complications with implants and implant prostheses. *J Prosthet Dent.* 2003 Aug;90(2):121-32.
10. Zitzmann NU, Marinello CP. A review of clinical and technical considerations for fixed and removable implant prostheses in the edentulous mandible. *Int J Prosthodont.* 2002 Jan-Feb;15(1):65-72.
11. Heydecke G, Boudrias P, Awad MA, De Albuquerque RF, Lund JP, Feine JS. Within-subject comparisons of maxillary fixed and removable implant prostheses: patient satisfaction and choice of prosthesis. *Clin Oral Implants Res.* 2003 Feb;14(1):125-30.
12. Potter BJ, Tiner BD. Central giant cell granuloma. Report of a case. *Oral Surg Oral Med Oral Pathol.* 1993 Mar;75(3):286-9.
13. Spraggs PD, Roth J, Young-Ramsaran J, Goodwin WJ. Giant cell reparative granuloma of the maxilla. *Ear Nose Throat J.* 1997 Jul;76(7):445-6, 449.
14. Whitaker SB, Waldron CA. Central giant cell lesions of the jaws. A clinical, radiologic, and histopathologic study. *Oral Surg Oral Med Oral Pathol.* 1993 Feb;75(2):199-208.
15. Warnke PH, Whiltfang J, Springer I, Acil Y, Bolte H, Kosmahl M, et al. Man as living bioreactor: fate of an exogenously prepared customized tissue-engineered mandible. *Biomaterials.* 2006 Jun;27(17):3163-7.
16. Wong TL, Wat PY, Pow EH, McMillan AS. Rehabilitation of a mandibulotomy/onlay/graft-reconstructed mandible using a milled bar and a tooth- and implant-supported removable dental prosthesis: A clinical report. *J Prosthet Dent.*

2010 Jul;104(1):1-5.

17. Minichetti JC, D'Amore JC, Schwarz E. Complete oral rehabilitation of a postresection ameloblastoma patient: a clinical case report. *J Oral Implantol*. 2011 Dec;37(6):735-44.

18. Beyabanaki E, Shamshiri AR, Alikhasi M, Monzavi A. Effect of Splinting on Dimensional Accuracy of Impressions Made of Implants with Different Subgingival Alignments. *J Prosthodont*. 2017 Jan;26(1):48-55.

19. Nematollahi F, Beyabanaki E, Alikhasi M. Cement Selection for Cement-Retained Implant-Supported Protheses: A Literature Review. *J Prosthodont*. 2016 Oct;25(7):599-606.

20. Dalkiz M, Beydemir B, Günaydin Y. Treatment of a microvascular reconstructed mandible using an implant-supported fixed partial denture: case report. *Implant Dent*. 2001

Feb;10(2):121-5.

21. Aghaloo TL, Moy PK. Which hard tissue augmentation techniques are the most successful in furnishing bony support for implant placement? *Int J Oral Maxillofac Implants*. 2007;22 Suppl:49-70.

22. Freilich MM, Sándor GK. In-office iliac crest bone harvesting for peri-implant jaw reconstruction. *J Can Dent Assoc*. 2006 Jul-Aug;72(6):543-7.

23. Saadat F, Mosharraf R. Prosthetic Management of an Extensive Maxillary Alveolar Defect with an Implant-Supported Restoration. *J Dent (Tehran)*. 2013 May;10(3):256-63.

24. Romanos GE, Gupta B, Eckert SE. Distal cantilevers and implant dentistry. *Int J Oral Maxillofac Implants*. 2012 Sep-Oct;27(5):1131-6.