



A Variant of the Current Dens Invaginatus Classification

Meisha Gul^{1,2*}, Samira Adnan³, Fahad Umer¹

1. Department of Operative Dentistry, The Aga Khan University Hospital, Karachi, Pakistan
2. Department of Pediatric Dentistry, Bahria University Medical and Dental College, Karachi, Pakistan
3. Department of Operative Dentistry, Jinnah Sindh Medical University, Karachi, Pakistan

Article Info

Article type:
Case Report

Article History:

Received: 14 Jul 2018
Accepted: 8 Nov 2018
Published: 29 Oct 2020

* Corresponding author:

Department of Paediatric Dentistry,
Bahria University Medical and Dental
College, Karachi, Pakistan

Email: meishagul@gmail.com

ABSTRACT

Endodontic treatment of maxillary incisors may be considered straight forward. However, in some instances, they may exhibit aberrant morphology. One of these rare variations in tooth morphology is dens invaginatus. To improve the endodontic prognosis of such teeth, a detailed evaluation of the tooth under treatment is important, which requires comprehensive clinical and radiographic examinations, including periapical radiography and cone-beam computed tomography (CBCT), which is highly recommended whenever atypical root canal morphology is suspected on a periapical radiograph. The current case report discusses the diagnosis of type IV dens invaginatus in a maxillary lateral incisor using CBCT.

Keywords: Cone-Beam Computed Tomography; Dens in Dente; Maxilla; Incisor; Root Canals; Anatomy

- **Cite this article as:** Gul M, Adnan S, Umer F. A Variant of the Current Dens Invaginatus Classification. *Front Dent.* 2020;17:28. doi: 10.18502/fid.v17i28.4654

INTRODUCTION

Unpredictable outcomes in endodontic treatment can be attributed to variations in the configuration of the root canal anatomy, which can sometimes be overlooked by clinicians. Amongst incisors, the maxillary lateral incisor shows most anatomic variations, such as C-shaped canals and dens invaginatus [1-3]. These variations must be noted before endodontic treatment to avoid complications [2,3].

Dens invaginatus, also known as dens in dente, is a developmental anomaly with a reported frequency of 0.25-10% in the permanent teeth [4,5]. In most cases, it involves a deepening or invagination of the enamel organ into the dental papilla before calcification of dental tissues [5]. Oehlers [6] gave the most accepted classification of dens invaginatus in 1957. According to this

classification, there are three basic types of dens invaginatus (Table 1 and Fig. 1) [6].

Table 1. Oehlers Classification of Dens Invaginatus (6)

Type I	Invagination is limited to the crown up to the amelocemental junction
Type II	Invagination extends into the root beyond the cementoenamel junction with no communication with the dental pulp
Type III A	Invagination extends into the root and communicates laterally through a pseudoforamen with the periodontal ligament (PDL) with no pulpal communication
Type III B	Invagination extends into the root and communicates apically through a pseudoforamen with the PDL with no pulpal communication

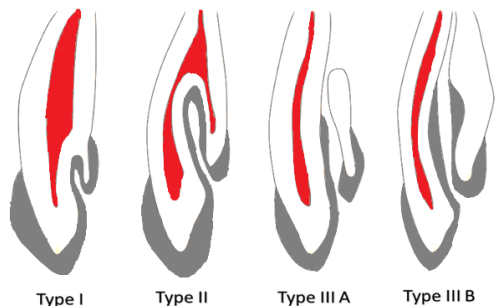


Fig. 1. Oehlers' classification of dens invaginatus

The presence of these developmental abnormalities poses a challenge in the prognosis of endodontic treatment [7]. Two-dimensional (2D) intraoral radiographs are the most common and routine means for initial diagnosis of pathologies but their diagnostic accuracy is limited. Three-dimensional (3D) imaging has overcome this limitation and it is now widely used in the diagnosis and treatment planning of complex endodontic cases [8]. This case report elucidates an addition to the Oehlers' classification [6] as type IV dens invaginatus in a maxillary lateral incisor, which was an incidental finding during cone-beam computed tomography (CBCT).

CASE REPORT

A 25-year-old female was referred by a general dental practitioner to the dental section of a tertiary care hospital for the evaluation of a recurrent sinus tract in the upper right lateral incisor region. The patient complained of recurrent episodes of swelling and pus discharge in the right maxillary anterior segment for one year. On the clinical examination, the maxillary right lateral incisor had typical crown morphology with incomplete access cavity preparation without any restoration. There was an associated intraoral draining sinus tract. The tooth was tender to percussion, and there was no response to thermal and electrical pulp testing. A periapical radiograph was taken, which showed periapical and lateral radiolucencies and two root canals with indistinct morphology (Fig. 2).

Hence, a CBCT scan (85 kilovolt peak (kVp) and 7 milliamperes (mA); Orthophos XG 3D, Sirona dental system D-64625, Bensheim, Germany) was taken, and the images were reconstructed using the Galaxis software (Version 1.9; Sirona dental system D-64625, Bensheim, Germany) on a 17-inch personal computer screen for definitive diagnosis. It was demonstrated that the main canal was pushed laterally by an invagination in the coronal third, which continued to the apex with apical and lateral communications through pseudo foramina (Fig. 3 and 4). There was also a lateral canal arising from the main root canal and communicating laterally with the periodontium along the same plane as the lateral communication of the dens invaginatus (Fig. 4).

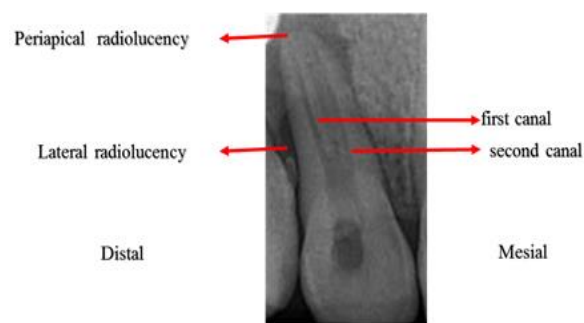


Fig. 2. Periapical radiograph showing lateral and periapical radiolucencies, two root canals, and indistinct canal anatomy

Considering the unique configuration of the current dens invaginatus, it cannot be placed into any of the current classifications as previously described by Oehlers (Fig. 1) [6]. Therefore, we propose to classify it as type IV dens invaginatus (Fig. 4).

DISCUSSION

There are various anatomic configurations of dens invaginatus. The invaginated cavity and the pulp chamber are linked through channels resulting in penetration of bacteria, causing inflammation of the pulpal tissue, degenerative changes, and eventually pulp necrosis [3,9].

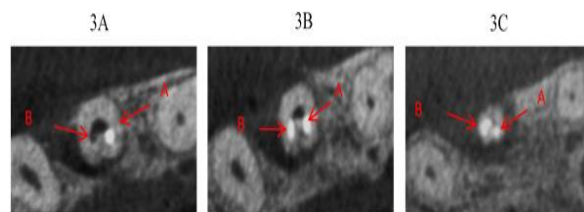


Fig. 3. (A) Cone-beam computed tomography (CBCT; axial view of the coronal third); the main root canal is pushed laterally by the invagination. (B) CBCT (axial view of the middle third); the main root canal and the invagination. (C) CBCT (axial view of the apical third); two apical openings, one is the pseudoforamen of the invagination and the other is the apical foramen of the main root canal

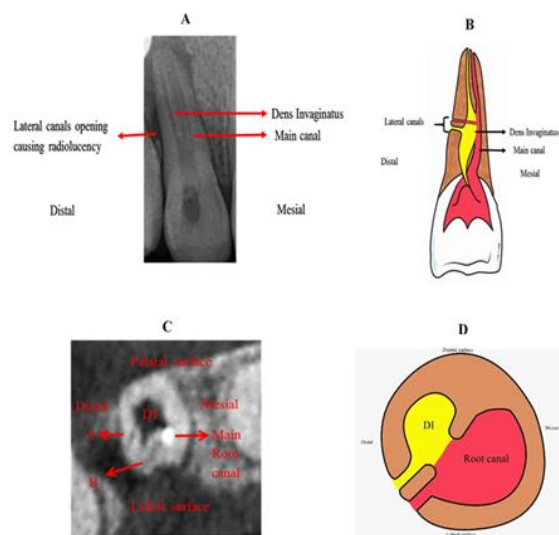


Fig. 4. Type IV dens invaginatus. (A) Preoperative radiograph and (B) pictorial diagram showing that the main root canal is pushed laterally by the invagination with a lateral canal arising from the main root canal plus the lateral communication of the invagination on the distal aspect of the maxillary right lateral incisor. (C) Cone-beam computed tomography (CBCT; axial view) and (D) pictorial axial view showing the lateral communication of the invagination with the periodontium and a lateral canal arising from the main root canal

CBCT is helpful in the correct diagnosis and treatment of invaginated teeth. This case report presents a new class of dens invaginatus that has not been described in the classification presented by Oehlers [6]. Type I is limited to the crown up to the

cementoenamel junction. In the present case, the invagination is extending beyond the amelocemental junction. Type II invagination extends into the root and may not communicate with the periodontal ligament (PDL). In the mentioned patient, we noted a lateral communication with the PDL. Type III invagination extends into the root and communicates through a pseudoforamen, either apically or laterally, with the PDL, but there is no communication with the dental pulp, whereas in the present case, the invagination is extending both laterally and apically, and there is a communication with the dental pulp. Therefore, the present case of dens invaginatus does not fall into any of the classes of dens invaginatus described by Oehlers [6]; hence, we propose to classify it as type IV dens invaginatus.

CONCLUSION

Root canal anatomy of maxillary incisors can be unpredictable; therefore, thorough knowledge of its variations, along with visual and radiographic assessments, is important. CBCT is a valuable diagnostic tool for identifying difficult and unusual cases like type IV dens invaginatus. In the proposed type IV dens invaginatus, the invagination extends into the pulp chamber beyond the amelocemental junction, pushing the main root canal laterally and communicating apically and laterally with the periodontium through a pseudoforamen. The invagination communicates with the dental pulp. In addition, there is a lateral canal arising from the main root canal.

CONFLICT OF INTEREST STATEMENT

None declared.

REFERENCES

1. Vertucci FJ. Root canal anatomy of the human permanent teeth. *Oral Surg Oral Med Oral Pathol.* 1984 Nov;58(5):589-99.
2. Kottoor J, Murugesan R, Albuquerque DV. A maxillary lateral incisor with four root canals. *Int Endod J.* 2012 Apr;45(4):393-7.
3. Jain P, Balasubramanian S, Sundaramurthy J,

Natanasabapathy V. A Cone Beam Computed Tomography of the Root Canal Morphology of Maxillary Anterior Teeth in an Institutional-Based Study in Chennai Urban Population: An In vitro Study. *J Int Soc Prev Community Dent.* 2017 Oct;7(Suppl 2):S68-S74.

4. Forghani M, Moghim Farooji E, Abuchenari J, Bidar M, Eslami N. Conservative Treatment of an Invaginated Maxillary Lateral Incisor with a C-shaped Canal Using Cone-Beam Computed Tomography. *Iran Endod J.* 2015 Fall;10(4):281-3.

5. Alani A, Bishop K. Dens invaginatus. Part 1: classification, prevalence and aetiology. *Int Endod J.* 2008 Dec;41(12):1123-36.

6. Oehlers FA. Dens invaginatus (dilated

composite odontome). I. Variations of the invagination process and associated anterior crown forms. *Oral Surg Oral Med Oral Pathol.* 1957 Nov;10(11):1204-18.

7. Kato H. Non-surgical endodontic treatment for dens invaginatus type III using cone beam computed tomography and dental operating microscope: a case report. *Bull Tokyo Dent Coll.* 2013;54(2):103-8.

8. Beach DA. CBCT Use in Endodontic Diagnosis. *Dent Today.* 2016 Feb;35(2):80, 82-3.

9. Rani N, Sroa RB. Nonsurgical endodontic management of dens invaginatus with open apex: A case report. *J Conserv Dent.* 2015 Nov-Dec;18(6):492-5.