



Implant-Retained Nasal Prosthesis with Bar and Clip for a Patient with Total Rhinectomy: A Clinical Report

Fatima Balaghi^{1,2}, Mahya Hasanzade^{1,2}, Hamid Mahmood Hashemi³, Simindokht Zarati^{1,2*}

1. Dental Research Center, Dentistry Research Institute, Tehran University of Medical Sciences, Tehran, Iran
2. Department of Prosthodontics, School of Dentistry, Tehran University of Medical Sciences, Tehran, Iran
3. Department of Oral and Maxillofacial Surgery, School of Dentistry, Tehran University of Medical Sciences, Tehran, Iran

Article Info

Article type:
Case Report

Article History:

Received: 1 June 2019

Accepted: 4 October 2019

Published: 20 December 2019

* Corresponding author:

Dental Research Center, Dentistry
Research Institute, Tehran University of
Medical Sciences, Tehran, Iran

Email: zaratisi@sina.tums.ac.ir

ABSTRACT

The present clinical report describes the fabrication of an implant-retained prosthesis with bar and clip retention for a patient with total rhinectomy due to basal cell carcinoma (BCC). The nasal prosthesis was retained on the face by a reverse Y-shaped bar with horizontal and vertical extensions, resulting in favorable retention and function.

Keywords: Nose Neoplasms; Maxillofacial Prosthesis Implantation; Case Reports [Publication Type]

- **Cite this article as:** Balaghi F, Hasanzade M, Mahmood Hashemi H, Zarati S. Implant-Retained Nasal Prosthesis with Bar and Clip for a Patient with Total Rhinectomy: A Clinical Report. *Front Dent.* 2019;16(6):478-483. doi: 10.18502/fid.v16i6.3448

INTRODUCTION

Basal cell carcinoma (BCC) is the most common skin cancer worldwide [1,2]. It is a slow-growing, locally aggressive and rarely metastatic malignancy. Since chronic exposure to sunlight is the main etiologic factor for BCC, it usually occurs in the head and neck region, and nose has the maximum risk of involvement [2]. As the majority of patients with BCC are managed by ablative surgery, the esthetic outcome is often disastrous. Therefore, postoperative facial reconstruction is of great importance. Nasal deformities can be reconstructed by means of a regional flap or with an extraoral prosthesis

depending on the site, size, etiology and patient's preferences. In case of large defects, surgical reconstruction often has limitations in restoring the form and function, and achieving a desirable color match. Furthermore, preoperative radiation can cause delayed wound healing and increase the risk of flap failure [3,4]. For these reasons, prosthetic rehabilitation seems to be the treatment of choice for these cases. Although being artificial, nasal prosthesis possesses several obvious advantages such as better color match in large defects, early rehabilitation, shorter surgical course and hospitalization period, no need for a donor site, and low initial

costs [5]. The retention of nasal prostheses may be achieved using the anatomical undercuts available in the defect, adhesives, or eye glasses [6]. Obviously, none of these methods are ideal. The use of extra-oral implants to improve the retention of craniofacial prosthesis was introduced in 1970. At present, implant retention is considered as the standard treatment in many situations [7,8]. The main advantage of using implants with craniofacial prostheses (especially nasal prostheses) is their easy maintenance (no need for cleaning the adhesive material). Other advantages include easier insertion of the prosthesis in its right position and improved retention compared with adhesive-retained prostheses. Hence, patient satisfaction was found to be higher with implant-retained craniofacial prostheses in comparison with adhesive-retained prostheses [9]. The overall implant survival for the implant-retained nasal prosthesis is estimated between 50% and 100% with the median survival rates of 85.5% and 80.0% for non-irradiated and irradiated patients, respectively [9]. The present clinical report describes the prosthetic rehabilitation of a patient who underwent rhinectomy due to tumor recurrence after 2 years. The patient had undergone radiotherapy after excisional biopsy for treatment of nasal BCC. An implant-retained nasal prosthesis was designed for him after 6 years of radiotherapy.

CASE REPORT

A 71-year-old man with total rhinectomy due to BCC was referred to the Department of Prosthodontics, Dental School of Tehran university of Medical Sciences. He had undergone radiotherapy at a dosage of 50 Gy for 25 sessions 1 year after his first excisional biopsy and 7 years before referring to our department. However, two years later, because of the recurrence with a diagnosis of infiltrative BCC (morphaea pattern) of the nose, the patient underwent complete rhinectomy. A split skin graft was placed at the base of the defect for lining of the surface of the area (Figure 1). Since he was edentulous, a complete denture was first made for him in order to provide optimal support for the upper lip before commencing the fabrication of nasal prosthesis.

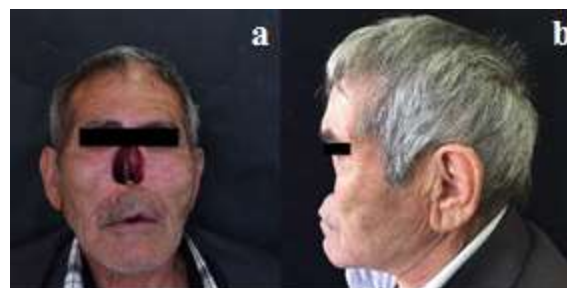

Fig. 1. Initial presentations. (a) frontal view, (b) lateral view

Two implant fixtures (Implantium II, Dentium, Korea) with 10 mm length and 4 mm diameter were inserted in the superior portion of the moderately resorbed maxillary bone, and the patient was provided with detailed instructions regarding the hygienic care (Figure 2).

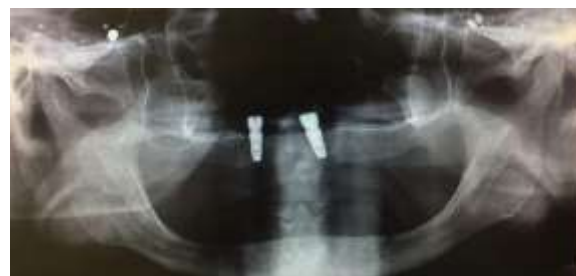

Fig. 2. Panoramic radiograph after implant insertion

An impression was made 6 months after the implant insertion using elastomeric materials. For direct impression making, two long impression copings were screwed to the fixtures and splinted with acrylic resin (GC Pattern Resin LS; GC America Inc., USA) in order to stabilize them during the impression making. Once the impression was made, the implant analogues were adapted and screwed into the pick-up impression copings. The cavity was filled with pieces of gauze coated with petroleum jelly in order to prevent the penetration of impression material into the deeper areas.

The undesirable undercuts were blocked-out and the regular body polyvinyl siloxane impression material (PVS; Panasil® monophase Medium, Kettenbach GmbH & Co. KG, Schoenberg, Germany) was then applied. Dental stone (Galaxy; Platres & Mineraux) was used over the silicon impression material to provide rigidity and support (Figure 3).

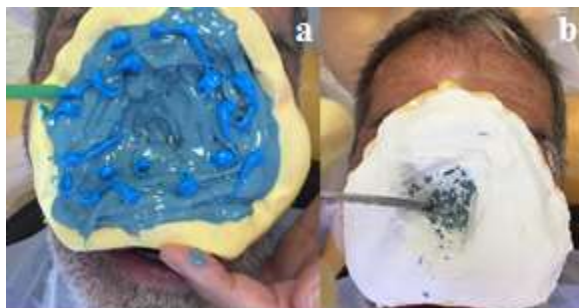


Fig. 3. Definitive impression of nasal defect with surrounding tissues. (a) Regular-body polyvinyl siloxane impression material. (b) dental Stone was used for rigidity and support

The impression was poured with type IV dental stone using 2 fixture analogues (Implantium II, Dentium, Korea). Given the similarity between our patient's facial form and his son, an impression was made from his son's nose with irreversible hydrocolloid (Iralgin, Golchaico, Iran). This mold was used to form the shape of nose in the next step. A verification jig was made to verify the accuracy of implant position transfer. The wax model prepared by making an impression from the patient's son was shaped and refined considering the esthetic contours for the defect site. The nose model was tried on the patient's face. The location of the eye glass nose pads was verified on the face and a transparent shield was made on the wax to serve as a guide during substructure fabrication in order to ensure sufficient space for the silicon. Two direct casting abutments (gold, non-hex, 4.5mm diameter) were selected. A bar-clip design, with one bar segment positioned vertically and the other one positioned horizontally, was designed in wax and casted with palladium-gold alloy (Quafibond 2, Qualident, Geneva, Switzerland) to prevent potential sensitivity of the skin graft. The cast bar was tried-on and its seating was verified with radiography (Figure 4).

Cold-cure acrylic resin (GC, Alsip, USA) was used for the fabrication of acrylic substructure. Metal housings were buried into the acrylic substructure for retention through the horizontal and vertical bars. Ceka preci-line

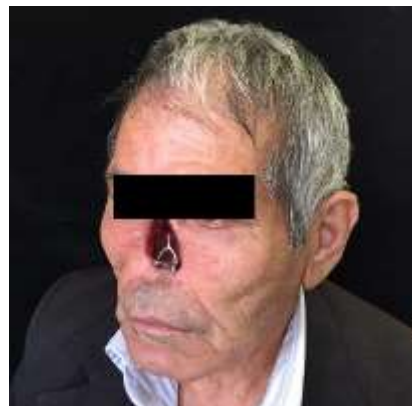

Fig. 4. Palladium-gold bar try-in

attachment (Waregem, Belgium) was then used in metal housings. Some retentive holes were created in the acrylic substructure for the mechanical retention of silicone to acrylic. The wax-up model was connected to the acrylic substructure and the assembly was tried-on the face again with casting bar being in its place. Cosmesil adhesive (Technovent Co, UK) was applied on the substructure to improve the retention of silicone to the acrylic substructure. The wax pattern was secured back onto the final cast and flaked. Intrinsic silicon colors (Cosmesil series) were added to the maxillofacial rubber (M511, maxillofacial silicon system, HT platinum rubber, Medical grade Technovent Co, UK) in order to simulate the skin's base color in a trial-and-error manner. Room-temperature silicone (Factor II, Lakeside, USA) was used in a two-piece mold. After 24 hours of processing at room temperature, extrinsic coloring was carried out for further matching with the patient's skin color. The patient was recommended to use eye glasses in order to hide the prosthesis edges (Figure 5). The process of insertion and removal of the prosthesis was thoroughly explained to the patient and the prosthesis was delivered. The hygienic instructions were also provided to the patient and he was instructed to clean the bar with the help of a proxy brush and gauze.

After 1 month, the patient was recalled for assessment of the retention of prosthesis, bar hygiene and discoloration.

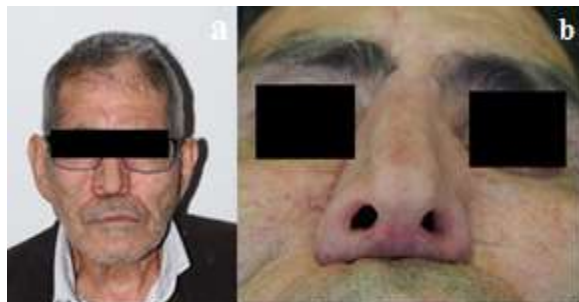

Fig. 5. Delivery of definitive implant-supported and bar-retained nasal prosthesis. (a) Frontal view. (b) Inferior view

DISCUSSION

Prosthetic rehabilitation of patients who have undergone rhinectomy should be able to meet both the esthetic and functional needs of patients [5]. Providing adequate retention for these prosthesis has always been a challenge. Worries concerning the prosthesis stability in certain situations affect patients' social activity self-confidence [10]. It has been shown that using inherent mechanical retention, chemical adhesive and eye glasses are faced with many problems and therefore unacceptable. Using chemical adhesive, the extensive tissue coverage is necessary to increase the retention and daily usage of these chemical agents can lead to the marginal degradation and increasing risk of skin irritation [11]. The predictable mechanical retention of facial prostheses has been developed by introducing the osseointegration to the extra-oral craniofacial prosthesis. Fixtures can be inserted during primary surgery or anytime postoperatively. There are numerous advantages for extra-oral implants including consistent retention, enhanced stability, improved patient's confidence, improved aesthetic due to the possibility of forming fine featheredge prosthesis and extended functional life of prosthesis [5,12]. The insertion of two endosseous implants in the nasal floor for supporting the nasal prostheses according to the standard protocol, yields high patient satisfaction. However, the average life span of silicone nasal prostheses is limited which is mainly due to the discoloration [5,9]. Various kinds of the retentive attachments can be used

for the purpose of retention including the bar and clip, ball and keeper and magnet and keeper [13-15]. The selection of retentive system depends on indication and abilities of the prosthodontist and maxillofacial prosthodontist [13]. Bar and clip which have been used in this study meet better retention than the magnetic attachment and they are frequently used in auricular and nasal prosthesis [6,14]. U-shaped and T-shaped bars are investigated in the literature from which, the latter one seems to be more applicable [6,14].

Radiotherapy is often used in treating the head and neck malignancies and it is accompanied by the increased risk of the implant failure [6]. Prognosis of the craniofacial implants in irradiated sites mainly depends on their site, dose and mode of radiation, gross tumor volume, clinical target volume, chemoradiotherapy and the length of implants further to the hyperbaric oxygen (HBO) usage [6]. In the study carried out by Granstrom [15], 54% of implants were placed in conjunction with HBO treatments. They showed that 23% of irradiated patients have implant failure in which 40% of failures were in non HBO-group and 8.5% in HBO group. The use of oral type implants in craniofacial sites, reduced the implant failure rate.

More recent literature suggests that there is no difference between the survival rate of implants placed for patients who received or did not received radiotherapy [6,16]. However, implants with at least 4 mm length should be considered for clinical use. Furthermore, implants with 3 mm length could be considered in a region with thick cortical bone [6].

The success rate of implant is estimated as 95%, 75% and 80% for the auricular site, 3mm and 4mm implants at nose's floor, respectively and the worst survival rate is reported in the orbital site due to the poor blood supply [6]. The Frontal bone around the orbit has not been considered as a proper place for the implant insertion due to its failure rate [6]. It has been shown that the failure rate is less with doses of 55Gy, but it increases as the doses exceed 65GY [6].

It has been reported that the implant retained

prosthesis for facial defects have limited survival rate of 14.5 months and the major reason for making a new prosthesis is the discoloration, decreasing quality fit of prosthesis at edges, prosthesis tearing, deposits on the prosthesis's tissue surface and mechanical failures of the acrylic resin substructure or retentive elements [15]. It is important to inform the patients about potential limitation of these prosthesis. They should also be aware of the regular scheduled appointments required for the prosthetic maintenance.

CONCLUSION

The present clinical report describes the implant-retained nasal prosthetic treatment of a total rhinectomy patient due to the basal cell carcinoma having the radiotherapy history about 5 years ago. The final prosthesis provided an acceptable retention and patient satisfaction. Insertion of 2 implants in the nasal floor, especially in the edentulous maxilla, provides a reliable treatment option for prosthodontic rehabilitation of patients after rhinectomy and also the high patient satisfaction, as a consequence. Nonetheless, the survival rate of the implants and prosthetic complications should be evaluated and it is recommended that the rehabilitation of irradiated patients to be carried out at clinics or institutions which are experienced in treating cancer patients.

ACKNOWLEDGMENTS

The authors would appreciate Mr. Mangoli for laboratory procedures

CONFLICT OF INTEREST STATEMENT

None declared.

REFERENCES

1. Al-Qarqaz F, Marji M, Bodoor K, Almomani R, Al Gargaz W, Alshiyab D, et al. Clinical and Demographic Features of Basal Cell Carcinoma in North Jordan. *J Skin Cancer*. 2018 Oct 4;2018:2624054.
2. Devine C, Srinivasan B, Sayan A, Ilankovan V. Epidemiology of basal cell

carcinoma: a 10-year comparative study. *Br J Oral Maxillofac Surg*. 2018 Feb;56(2):101-6.

3. Bourget A, Chang JT, Wu DB-S, Chang CJ, Wei FC. Free flap reconstruction in the head and neck region following radiotherapy: a cohort study identifying negative outcome predictors. *Plast Reconstr Surg*. 2011 May;127(5):1901-8.

4. Thankappan K. Microvascular free tissue transfer after prior radiotherapy in head and neck reconstruction—a review. *Surg Oncol*. 2010 Dec;19(4):34-7.

5. Becker C, Becker A, Dahlem K, Offergeld C, Pfeiffer J. Aesthetic and functional outcomes in patients with a nasal prosthesis. *Int J Oral Max Surg*. 2017 Nov;46(11):1446-50.

6. Beumer J, Curtis TA, Firtell D. Maxillofacial rehabilitation. St. Louis: Mosby. 1979:90-169.

7. Karakoca S, Aydin C, Yilmaz H, Bal BT. Retrospective study of treatment outcomes with implant-retained extraoral prostheses: survival rates and prosthetic complications. *J Prosthet Dent*. 2010 Feb;103(2):118-26.

8. Tjellström A, Lindström J, Hallén O, Albrektsson T, Brånemark P-I. Osseointegrated titanium implants in the temporal bone. A clinical study on bone-anchored hearing aids. *Am J Otol*. 1981 Apr;2(4):304-10.

9. Korfage A, Raghoobar GM, Noorda WD, Plaat BE, Vissink A, Visser A. Recommendations for implant-retained nasal prostheses after ablative tumor surgery: Minimal surgical aftercare, high implant survival, and satisfied patients. *Head & Neck*. 2016 Apr;38(S1):E61-E24.

10. Becker C, Becker AM, Pfeiffer J. Health-related quality of life in patients with nasal prosthesis. *J Craniomaxillofac Surg*. 2016 Jan;44(1):75-9.

11. Parel SM, Branemark P, Tjellstrom A, Gion G. Osseointegration in maxillofacial prosthetics. Part II: Extraoral applications. *J Prosthet Dent*. 1986 May;55(5):600-6.

12. Pekkan G, Tuna S, Oghan F. Extraoral prostheses using extraoral implants. *Int J Oral Maxillofac Surg*. 2011 Apr;40(4):378-83.

13. Cobein MV, Coto NP, Junior OC, Lemos JBD, Vieira L, Pimentel M, et al. Retention systems for extraoral maxillofacial prosthetic implants: a critical review. *Br J Oral Maxillofac Surg.* 2017 Oct;55(8):763-9.
14. Taylor TD (ed). *Clinical Maxillofacial Prosthetics.* Chicago, Quintessence, 2000:149.
15. Granström G. Osseointegration in irradiated cancer patients: an analysis with respect to implant failures. *J Oral Maxillofac Surg.* 2005 May;63(5):579-85.
16. Schiegnitz E, Al-Nawas B, Kämmerer P, Grötz K. Oral rehabilitation with dental implants in irradiated patients: a meta-analysis on implant survival. *Clin Oral Investig.* 2014 Apr;18(3):687-98