



# Thickness of Buccal and Lingual Alveolar Bone Plates according to the Position of Impacted Mandibular Third Molars on Cone-Beam Computed Tomography Scans

Seyed Alireza Parhiz<sup>1</sup>, Pegah Bakhtiary<sup>1</sup>, Farzaneh Mosavat<sup>2\*</sup>,  
Mohammad Javad Kharazifard<sup>3</sup>

1. Department of Oral and Maxillofacial Surgery, School of Dentistry, Tehran University of Medical Sciences, Tehran, Iran
2. Department of Oral and Maxillofacial Radiology, School of Dentistry, Tehran University of Medical Sciences, Tehran, Iran
3. Dental Research Center, Dentistry Research Institute, Tehran University of Medical Sciences, Tehran, Iran

## Article Info

**Article type:**  
Original Article

## Article History:

Received: 18 January 2018  
Accepted: 29 May 2018  
Published: 30 August 2019

## \* Corresponding author:

Department of Oral and Maxillofacial Radiology, School of Dentistry, Tehran University of Medical Sciences, Tehran, Iran

E-mail: farzaneh.mosavat@gmail.com

## ABSTRACT

**Objectives:** This study sought to assess the thickness of buccal and lingual alveolar bone plates according to the position of impacted mandibular third molars on cone-beam computed tomography (CBCT) scans.

**Materials and Methods:** Eighty-four CBCT scans of impacted mandibular third molars were evaluated in this retrospective study. All images had been obtained by ProMax 3D CBCT system with the exposure settings of 78 kVp, 12 mA, 16 s time, 0.2 mm voxel size and 10 × 9 cm field of view. The impaction angle of teeth and the thickness of buccal and lingual cortical plates were determined on images by drawing lines in the anterior, middle, posterior, superior, central and inferior regions. Thickness of bone plates was analyzed according to the position of impacted molars relative to the buccal and lingual plates using the Student t-test and relative to the second molars using one-way ANOVA and Tukey's test.

**Results:** In the buccolingual direction, the buccal plate thickness was maximum in lingual position followed by central position, and minimum in buccal position of the teeth. The lingual plate thickness was minimum in horizontal and distoangular positions and maximum in the mesioangular position of impacted teeth.

**Conclusion:** Risk of lingual plate preformation is higher in surgical removal of impacted third molars with distoangular and horizontal positions. Thus, further attention must be paid by the surgeons to such cases.

**Keywords:** Cone-Beam Computed Tomography; Molar, Third; Mandible; Surgery

- **Cite this article as:** Parhiz SA, Bakhtiary P, Mosavat F, Kharazifard MJ. Thickness of Buccal and Lingual Alveolar Bone Plates according to the Position of Impacted Mandibular Third Molars on Cone-Beam Computed Tomography Scans. *Front Dent.* 2019;16(4):279-289. doi: 10.18502/fid.v16i4.2087

## INTRODUCTION

Impacted teeth are defined as teeth that cannot erupt into their correct functional

position in the dental arch and therefore, do not have a normal relationship with the adjacent teeth or the soft tissue [1]. Of all teeth,

mandibular third molars have the highest rate of impaction ranging from 27% to 76% [1]. As a general rule, all impacted teeth have to be extracted except for some certain cases where the extraction of impacted tooth is not feasible [2]. Extraction of impacted mandibular third molars is a routinely performed surgical procedure, which is also associated with some risks and possible complications. The sensory disturbances of the inferior alveolar nerve are among the relatively common complications of surgical extraction of mandibular third molars [3,4], which mainly occur due to traumatization of the sensory nerve fibers [5,6]. Although rare, risk of displacement of third molars or the remaining root segment into the sublingual space also exists in surgical extraction of impacted mandibular third molars. In such circumstances, patients may complain of pain, swelling and trismus, and the tooth or root segment pushed into the sublingual space should be necessarily removed, which is a complex procedure associated with several postoperative complications [7]. Some factors determine the risk of complications following mandibular third molar extraction surgery including the position of impacted third molar, its lingual inclination, application of uncontrollable forces and poor preoperative clinical evaluation.

Use of cone-beam computed tomography (CBCT) for maxillofacial imaging yields three-dimensional images with lower dose, lower cost and higher resolution than computed tomography (CT) [8]. CBCT is a suitable modality to determine the level of difficulty of the procedure and propose an efficient treatment plan for surgical extraction of complex cases of impacted mandibular third molars. Using CBCT scans, the thickness of alveolar bone can be determined with high accuracy and precision [9]. Comprehensive preoperative clinical and radiographic examinations of the hard and soft tissue are imperative to minimize the risk of perioperative incidents and postoperative complications [9].

Removal of the alveolar bone is a critical step

in surgical extraction of impacted mandibular third molars.

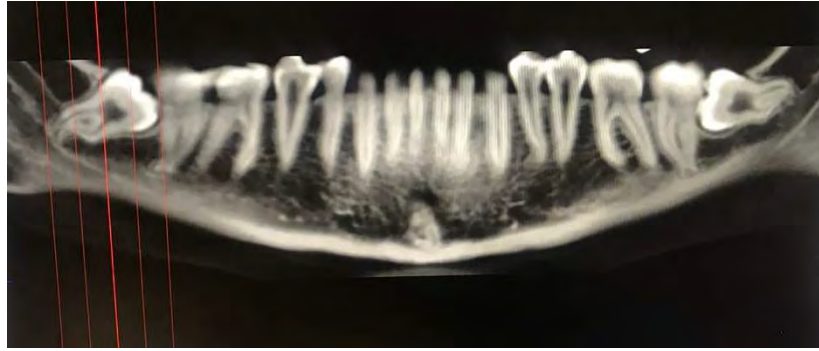
Knowledge about the alveolar bone thickness in different areas can aid clinicians in decision making about the treatment plan and the most efficient protocol for tooth extraction. Despite the availability of several classifications for bone thickness, none of them provide information about the buccal and lingual bone plate thickness at the site of impacted third molars [9]. Therefore, this study was undertaken aiming to determine the correlation of angle of impaction of mandibular third molars and buccal and lingual bone plate thickness at the site to estimate the risk of traumatization of lingual hard and soft tissue during surgical extraction of mandibular third molars.

### MATERIALS AND METHODS

This retrospective study was performed on 84 CBCT scans of the impacted mandibular third molars retrieved from the archives of the Oral and Maxillofacial Radiology Department of School of Dentistry, Tehran University of Medical Sciences.

Sample size was calculated to be 84 CBCT scans according to a study by Ge et al, [9] assuming  $\alpha=0.05$ ,  $\beta=0.1$  and  $d=0.06$ . The high-quality CBCT scans of the impacted mandibular third molars were selected using convenience sampling.

The exclusion criteria were presence of tumor, fracture or cyst at the site, and presence of dental crowns, dental implants or metal bridges causing beam hardening and compromising the quality of images. All CBCT scans had been taken with Alphared 3030 CBCT system (Asahi Rontgen. Ind. Co., Ltd., Kyoto, Japan) with the exposure settings of 80 kVp, 4 mA, 17 s time,  $10 \times 10$  cm field of view and 200  $\mu$  voxel size. Panoramic image reconstruction was performed. First, the reference section was determined. For this purpose, the distance between the most anterior and the most posterior parts of the impacted third molars on reconstructed panoramic images was divided into 4 equal segments by 5 vertical lines (Fig. 1).

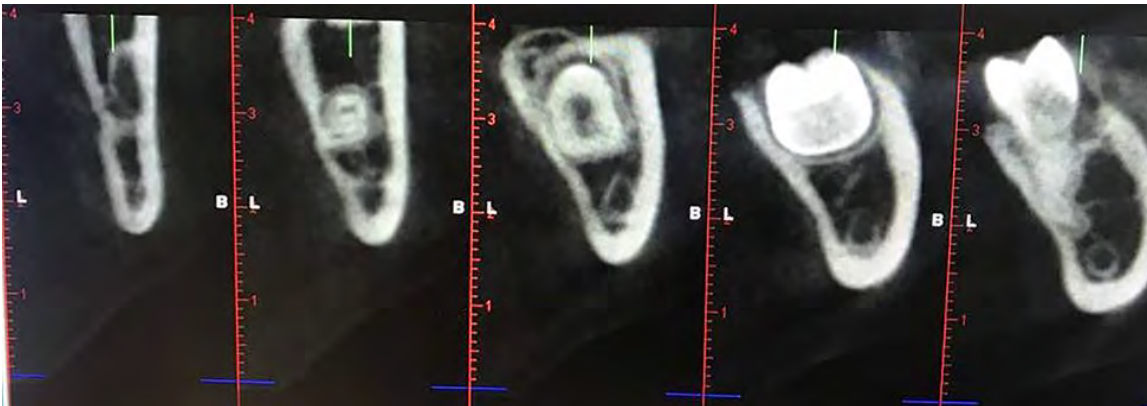


**Fig. 1.** Identifying the reference sections on a reconstructed panoramic image

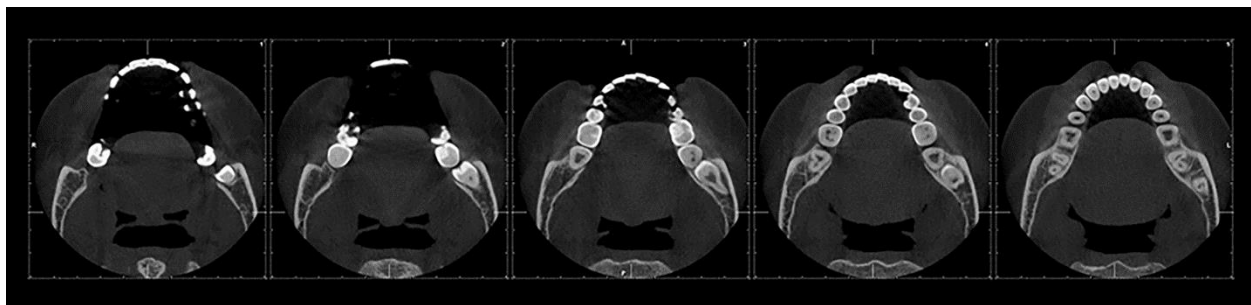
The three dividing lines at the middle were considered as reference and referred to as the anterior, middle and posterior lines. Cross-sectional slices were made at each line, and the respective measurements were made on these sections (Fig. 2).

Similarly, the distance between the most superior and the most inferior parts of the

impacted third molars on reconstructed panoramic images was divided into four equal segments by five horizontal lines. The three middle lines were considered as the reference lines and were referred to as the superior, middle and inferior reference lines. Axial sections were reconstructed for the respective measurements (Fig. 3).

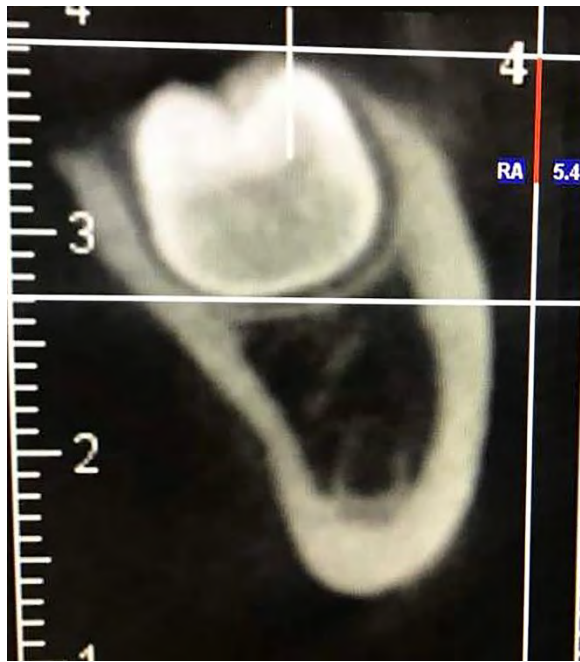

**Fig. 2.** Defining the anterior, middle and posterior reference lines for measurements on cross-sectional slices



**Fig. 3.** Superior, central and inferior sections on CBCT

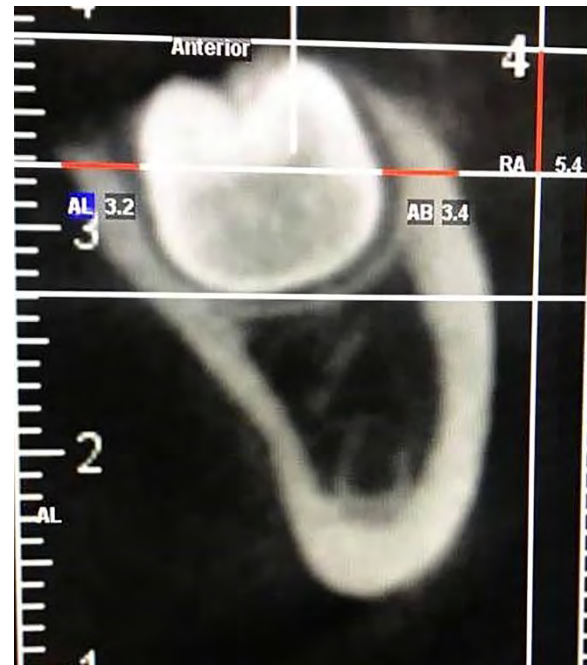Next, the midpoints were identified right in the middle of the distance between the inferior-superior borders of tooth on cross-sectional slices at the middle, inferior and posterior lines and were referred to as RA, RM and RP, respectively (Fig. 4).



**Fig. 4.** Anterior CBCT section of impacted third molar. The two white lines indicate the distance between the superior and inferior points and the distance between the two lines was measured to be 10.8 mm. This distance was divided by 2 and the obtained value was 5.4 mm (red line), referred to as RA.

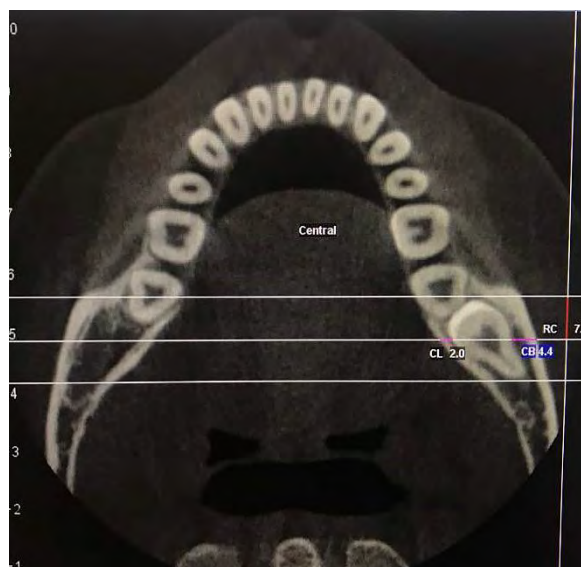
Afterwards, the alveolar bone thickness was measured. For this purpose, the anterior buccal and lingual bone thicknesses were measured on the anterior cross-sectional slice. Horizontal line was drawn passing through the RA point, and two variables were measured at the location of this line: (B) the thickness of alveolar buccal bone plate (distance between the external border of bone and buccal surface of tooth) and (L) the thickness of alveolar lingual bone plate (distance between the external border of bone and lingual surface of tooth). The results were reported as AB (the thickness of anterior alveolar buccal bone) and AL (the thickness of anterior alveolar lingual bone) (Fig. 5).

The same was performed in the middle section, and the buccal bone plate in this section was referred to as MB and the lingual bone plate in this section was referred to as ML. Similar measurements were made in the posterior section as well (PB and PL) and on



**Fig. 5.** Measurement of the alveolar bone thickness. As shown, a horizontal line was drawn from the point RA (white line). Red line at the buccal indicates the buccal bone plate (AB) and its thickness was measured to be 4.3 mm. Red line at the lingual indicates the lingual bone plate (AL) and its thickness was measured to be 3.2 mm.

axial sections at the superior, middle and inferior lines (RS, RC and RI). To measure the superior buccal and lingual bone thickness, the superior axial section was used such that a line was drawn from RS and the two variables were measured according to this line: (B) buccal bone thickness (distance between the external border of bone and buccal surface of tooth) and (L) the thickness of alveolar lingual bone plate (distance between the external border of bone and lingual surface of tooth). The same measurements were made on the middle and inferior axial sections for assessment of CL, CB, IL and IB (Fig. 6). Similar measurements were made on the middle and inferior axial sections (IB, IL, CB and CL).



**Fig. 6.** Central section showing the distance between the anterior and posterior points (white lines). RC was 7 mm, the buccal bone thickness (CB) was 4.4 mm and the lingual bone thickness (CL) was 2 mm.

Total buccal bone thickness (TB) = AB + MB + PB + SB + CB + IB

Total lingual bone thickness (TL) = AL + ML + PL + SL + CL + IL

The mean difference (MD) was calculated as follows: MD = TB - TL / 6

One oral and maxillofacial radiologist observed the images. Alveolar bone thickness was measured using Romexis software and categorized as follows:

MD ≥ 1: Lingual position; -1 < MD < 1: Central position; MD ≤ -1: Buccal position

If two separate roots were detected on axial sections or cross-sectional slices and the

midpoint was located at the middle of the distance between the two separate roots, the midpoints between the anterior and posterior tooth borders on axial sections or midpoints between the superior and inferior borders of teeth on cross-sectional slices for each root were determined separately, and separate lines were drawn from these points for each root. Next, the thickness of buccal and lingual plates for each root was determined. Eventually, the mean thickness of buccal and lingual bone was calculated.

Data were analyzed using SPSS version 25 (SPSS Inc., IL, USA). The thickness of buccal and lingual plates separately for central and lingual position of impacted third molars relative to the buccal and lingual plates was calculated and analyzed using the Student t-test. The thickness of buccal and lingual plates for different positions of impacted teeth relative to the second molars was analyzed using one-way ANOVA. In case of presence of significant differences, pairwise comparisons were carried out using the Tukey's test. P < 0.05 was considered statistically significant.

## RESULTS

The highest mean thickness of buccal bone (5.04 mm) was in the superior section and the lowest mean thickness of buccal bone (3.74 mm) was in the anterior section.

The highest mean thickness of lingual bone (3.0 mm) was in the superior section and the lowest mean thickness of lingual bone was in the posterior section (1.58 mm). The total

**Table 1.** Central dispersion of the mean thickness (mm) of buccal and lingual bone plates on cross-sectional and axial cone-beam computed tomography sections

		Anterior	Middle	Posterior	Superior	Central	Inferior
Buccal	Min-Max	1.4-8	1.2-7.6	0.8-9.6	1-12.6	1.2-10.6	0-8.8
	Mean(SD)	3.74(1.25)	4.01(1.45)	4.14(1.97)	5.04(1.91)	4.65(1.94)	2.13(4.29)
Lingual	Min-Max	0.8-4.5	0-4.2	0-4.6	0-8.6	0-6	0-5.8
	Mean(SD)	2.13(0.76)	1.78(0.85)	1.58(1.26)	3(1.75)	2.53(1.08)	2.04(1.46)

Min-Max: Minimum-Maximum; SD: Standard Deviation

mean thickness of lingual bone was  $13.44 \pm 5.12$  mm. The total mean thickness of buccal bone was  $26.14 \pm 8.81$  mm and MD (mean difference divided by 6) was  $2.09 \pm 1.71$  mm (Table 1). In general, the mean thickness of buccal bone plate at the site of impacted third molars was greater than that of the lingual plate. According to one-way ANOVA, significant differences were noted in the mean buccal and lingual bone thickness in different sections ( $P < 0.05$ ) and MD according to the position of impacted third molar relative to the second molar.

Significant differences were noted in buccal and lingual bone thickness in different sections based on vertical, horizontal, mesioangular and distoangular positions of teeth relative to the second molar ( $P < 0.05$ ). Table 2 demonstrates significant values related to central dispersion of mean thicknesses on different sections based on the position of the third molars relative to the second molars, in addition to the total thickness of lingual bone plate, due to its clinical significance. Regarding the position of third molars relative to the second molars, mesioangular teeth had the highest prevalence followed by horizontal, vertical and distoangular positions.

Table 3 shows pairwise comparisons of buccal and lingual bone thickness in different positions of impacted third molars relative to the second molars on CBCT sections.

Buccolingually, the lingual position had the highest frequency followed by central position. Buccal position had the lowest frequency. Lingual plate thickness was minimum in horizontal and distoangular and maximum in mesioangular position of impacted teeth. Table 4 shows the mean thickness of buccal and lingual plates on different sections based on the position of third molars relative to the buccal and lingual plates. Of 84 impacted mandibular third molars, 2 had buccal position and since they would decrease the power of statistical tests, they were excluded.

The minimum mean thickness of lingual bone

plate was in the posterior section for teeth with lingual position while the maximum thickness of lingual bone was in the superior section for teeth with central position. According to the Student's t-test, significant differences were noted in the thickness of buccal and lingual plates in different sections, total buccal and lingual thickness and MD in teeth with central and lingual positions relative to the buccal and lingual plates ( $P < 0.05$ , Table 4).

## DISCUSSION

This study assessed the thickness of buccal and lingual bone plates based on the position of impacted mandibular third molars on CBCT scans. Our results showed significant differences in buccal and lingual bone thickness on different sections, which calls for the attention of surgeons to this matter prior to surgery.

This study showed that the buccal bone thickness at the site of impacted mandibular third molars was generally greater than the thickness of lingual plate (26.14 mm versus 13.44 mm). The reason is probably the reinforcement of the buccal plate by the external oblique ridge [10-17]. Ge et al. [9] reported that the buccal bone plate was thicker than the lingual bone plate at the site of third molars (4.51 mm versus 1.69 mm), which was in line with our findings. Regarding the position of impacted third molars relative to the second molars, 20.2% of impacted teeth had horizontal, 57.1% had mesioangular, 13.1% had vertical and 9.5% had distoangular position. Mahdey et al. [1] evaluated 20 to 44-year-old Malaysians and reported that mesioangular impaction was the most common type in impacted mandibular third molars.

Xu et al. [18] reported that the majority of impacted third molars had mesioangular and vertical positions while horizontally-impacted teeth had the lowest frequency. Their findings were in agreement with our results.

In the current study, the mean buccal bone thickness in the anterior section was significantly different in mesioangular and

**Table 2.** Central dispersion of the mean buccal and lingual bone thickness (mm) on different cone-beam computed tomography sections according to the position of impacted third molars relative to the second molars

Bone thickness	Section Position	Vertical	Horizontal	Mesio-angular	Disto-angular	P-value
<b>Buccal</b>	<b>Anterior</b>	4.05	4.05	3.39	4.71	0.01
	<b>Posterior</b>	4.94	5.06	3.44	5.33	0.001
	<b>Superior</b>	4.54	6.42	4.76	4.49	0.008
	<b>Central</b>	4.39	5.64	4.23	5.5	0.04
	<b>Inferior</b>	3.71	5.86	3.63	5.75	0.001
<b>Lingual</b>	<b>Posterior</b>	2.09	0.53	1.73	2.2	0.001
	<b>Inferior</b>	1.42	2.38	2.25	0.94	0.04
<b>Total thickness of buccal plate</b>	-	26.89	31.49	23.29	30.81	0.002
<b>Total thickness of lingual plate</b>	-	12.54	12.94	14.06	12.09	0.63
<b>Mean difference</b>	-	2.35	3.03	1.55	3.05	0.004

distoangular positions, and the greatest buccal bone thickness was recorded for distoangular position where the roots had lingual inclination. In mesioangular position, the buccal bone thickness was minimal. Also, the difference in the mean buccal bone thickness in the posterior section in horizontal impaction was significant compared with that in mesioangular position. The difference in this respect between mesioangular and distoangular positions was significant as well. The mean buccal bone thickness was minimal in mesioangular position while it was greater in horizontal and distoangular positions in this

section. Thus, impacted third molars with horizontal and distoangular positions have greater lingual inclination compared with those with other positions. The mean thickness of lingual bone in the posterior section was significantly different between vertical and horizontal, horizontal and mesioangular, and horizontal and distoangular positions. In the posterior section, horizontally impacted third molars had the thinnest lingual plate and showed lingual inclination. The mean buccal bone thickness in the superior section was significantly different between vertical and

horizontal, and horizontal and mesioangular positions. Buccal bone thickness in central section was significantly different between horizontal and mesioangular positions and in both sections, teeth with horizontal impaction had the thickest buccal bone plate. The mean

thickness of buccal bone in the inferior section was significantly different in vertical and horizontal, horizontal and mesioangular, and mesioangular and distoangular positions. The distoangular and horizontal positions had the thickest buccal bone and showed lingual

**Table 3.** Pairwise comparisons of the impacted mandibular third molars with different positions relative to the second molars based on the thickness of buccal and lingual bone plates (mm) on different sections (only significant values are shown)

Bone thickness	Section	Position	P-value
Buccal	Anterior	Position 1: mesioangular	0.02
		Position 2: distoangular	
	Posterior	Position 1: horizontal	0.01
		Position 2: mesioangular	
		Position 1: mesioangular	0.04
		Position 2: distoangular	
	Superior	Position 1: vertical	0.04
		Position 2: horizontal	
		Position 1: horizontal	0.009
	Position 2: mesioangular		
	Central	Position 1: horizontal	0.05
		Position 2: mesioangular	
	Inferior	Position 1: vertical	0.02
		Position 2: horizontal	
Position 1: horizontal		0.001	
Position 2: mesioangular			
Position 1: mesioangular		0.02	
Position 2: distoangular			
Lingual	Posterior	Position 1: vertical	0.04
		Position 2: horizontal	
	Position 1: horizontal	0.009	
	Position 2: mesioangular		
Total thickness of buccal plate	-	Position 1: horizontal	0.004
		Position 2: mesioangular	
Mean difference	-	Position 1: horizontal	0.009
		Position 2: mesioangular	

inclination. In general, the overall mean thickness of buccal bone and MD had a significant correlation with angle of impaction of third molars, and horizontally impacted

teeth showed the greatest buccal bone thickness.

The mesioangular position showed the least thickness of buccal bone although the total



lingual bone thickness had no significant correlation with angle of impaction. Lingual bone plate thickness was less in distoangular and horizontal positions of third molars, and the greatest lingual bone thickness was noted in mesioangular position, which had 2 mm difference with other positions. Thus, in general, among different CBCT sections, horizontally

impacted third molars in 6 sections and distoangular impacted third molars in 4 sections had the greatest buccal bone thickness.

A significant correlation was also noted between horizontal and mesioangular impaction and buccal bone thickness such that mesioangular teeth in 7 sections had the thinnest buccal bone and had buccal inclination.

**Table 4.** Measures of central dispersion of the mean thickness of buccal and lingual bone plates on axial and cross-sectional CBCT sections based on the position of teeth relative to the buccal-lingual plates

Variable	Position	Mean	P value
<b>Buccal bone thickness in the anterior section</b>	Central	3.06	0.007
	Lingual	3.95	
<b>Buccal bone thickness in the middle section</b>	Central	2.73	0.0001
	Lingual	4.43	
<b>Lingual bone thickness in the middle section</b>	Central	2.16	0.04
	Lingual	1.68	
<b>Buccal bone thickness in the posterior section</b>	Central	2.26	0.0001
	Lingual	4.75	
<b>Lingual bone thickness in the posterior section</b>	Central	2.5	0.0001
	Lingual	1.28	
<b>Buccal bone thickness in the superior section</b>	Central	3.76	0.001
	Lingual	5.42	
<b>Buccal bone thickness in the central section</b>	Central	3.11	0.0001
	Lingual	5.09	
<b>Buccal bone thickness in the inferior section</b>	Central	2.64	0.0001
	Lingual	4.85	
<b>Buccal bone thickness in the inferior section</b>	Central	2.7	0.01
	Lingual	1.77	

These results were noted in sections showing significant correlation of bone thickness and angle of impaction. The results revealed minimum thickness of lingual bone in teeth with horizontal and distoangular impaction. Weak lingual cortex can cause lingual plate fracture during tooth extraction. Also, risk of lingual plate perforation, traumatization of lingual nerve and tooth displacement increases in such cases [19]. Our findings can help surgeons to prevent lingual plate fracture and its subsequent complications because knowledge about the position of impacted third molars relative to the second molars can help determine the position of tooth relative to the buccal and lingual plates.

Generally, the buccal plate thickness was greater than the lingual plate thickness at the site of impacted third molars. According to the position of impacted third molars in

buccolingual direction, bone thickness was maximum in lingual position followed by central position and minimum in buccal position of teeth. The lingual bone plate thickness was minimum in horizontal and distoangular positions of impacted teeth and maximum in mesioangular position of impacted teeth.

Surgical removal of impacted third molars is a common procedure in dental clinics. Thus, preoperative radiographic assessment to determine the level of difficulty of the procedure and the position of impacted tooth relative to the second molar and lingual and buccal plates can help prevent complications and promote the prognosis of surgical procedure [9]. Using this information, the surgeon can estimate the thickness of buccal and lingual plates according to the angle of impaction of mandibular third molars and

prevent complications such as lingual plate fracture, tooth displacement into the sublingual space and lingual nerve damage. Future studies on other populations and with different CBCT systems are required to further elucidate this topic. Also, the sensitivity and specificity of linear measurements made on CBCT scans should be evaluated in future studies to ensure the accuracy of the results.

## CONCLUSION

Risk of lingual plate preformation is higher in surgical removal of impacted third molars with distoangular and horizontal positions. Thus, further attention must be paid by the surgeons to such cases.

## CONFLICT OF INTEREST STATEMENT

None declared.

## REFERENCES

1. Mahdey HM, Arora SH, Wei M. Prevalence and difficulty index associated with the 3rd mandibular molar impaction among Malaysian ethnicities: a clinico-radiographic study. *J Clin Diagnost Res*. 2015 Sep 9(9):ZC65-ZC68.
2. Hupp JR, Tucker MR, Ellis III E. *Contemporary oral and maxillofacial surgery*. Elsevier Health Sciences, 2013:75-6.
3. Al-Anqudi SM, Al-Sudairy S, Al-Hosni A, Al-Maniri A. Prevalence and pattern of third molar impaction: a retrospective study of radiographs in Oman. *Sultan Qaboos University Med J*. 2014 Aug;14(3):e388-92.
4. Koong B, Pharoah MJ, Bulsara M, Tennant M. Methods of determining the relationship of the mandibular canal and third molars: a survey of Australian oral and maxillofacial surgeons. *Australian Dent J*. 2006 Mar;51(1):64-8.
5. Maegawa H, Sano K, Kitagawa Y, Ogasawara T, Miyauchi K, Sekine J, et al. Preoperative assessment of the relationship between the mandibular third molar and the mandibular canal by axial computed tomography with coronal and sagittal reconstruction. *Oral Surg Oral Med Oral Pathol Oral Radiol Endod*. 2003 Nov;96(5):639-46.
6. Blaeser BF. Panoramic radiographic risk factors for IAN injury after third molar extraction. *J Oral Maxillofac Surg*. 2003 Apr;61(4):417-21.
7. Aznar-Arasa L, Figueiredo R, Gay-Escoda C. Iatrogenic displacement of lower third molar roots into the sublingual space: report of 6 cases. *J Oral Maxillofac Surg*. 2012 Feb;70(2):e107-15.
8. White S, Pharoah M. *Oral Radiology: Principles and Interpretation*. Philadelphia: Mosby Co., 2004;5:166-72,272-3,677-82.
9. Ge J, Zheng JW, Yang C, Qian WT. Variations in the buccal-lingual alveolar bone thickness of impacted mandibular third molar: our classification and treatment perspectives. *Sci Rep*. 2016 Jan;6:16375.
10. Obiechina AE, Arotiba JT, Fasola AO. Third molar impaction: evaluation of the symptoms and pattern of impaction of mandibular third molar teeth in Nigerians. *Odontostomatol Trop*. 2001 Mar;24(93):22-5.
11. Ge J. Four osteotomy methods with piezosurgery to remove complicated mandibular third molars: a retrospective study. *J Oral Maxillofac Surg*. 2014 Nov;72(11):2126-33.
12. Hasegawa T. Risk factors associated with inferior alveolar nerve injury after extraction of the mandibular third molar—a comparative study of preoperative images by panoramic radiography and computed tomography. *Int J Oral Maxillofac Surg*. 2013 Jul;42(7):843-51.
13. Schneider T. Variations in the anatomical positioning of impacted mandibular wisdom teeth and their practical implications. *Swiss Dent J*. 2014;124(5):520-38.
14. Ghaeminia H. The use of cone beam CT for the removal of wisdom teeth changes the surgical approach compared with panoramic radiography: a pilot study. *Int J Oral Maxillofac Surg*. 2011 Aug;40(8):834-9.
15. Momin MA, Matsumoto K, Ejima K, Asaumi R, Kawai T, Arai Y. Correlation of mandibular impacted tooth and bone morphology determined by cone beam computed tomography on a premise of third molar operation. *Surg Radiol Anat*. 2013

May;35(4):311-8.

16. Peterson LJ. Principles of management of impacted teeth, in Contemporary oral and maxillofacial surgery. 5th Ed., St. Louis. CV Mosby Co., 2008:153-61.

17. Aalam AA, Nowzari H. Mandibular cortical bone grafts part 1: anatomy, healing process, and influencing factors. Compend Contin Educ Dent. 2007 Apr;28(4):206-12.

18. Xu GZ, Yang C, Fan XD, Yu CQ, Cai XY,

Wang Y, et al. Anatomic relationship between impacted third mandibular molar and the mandibular canal as the risk factor of inferior alveolar nerve injury. Br J Oral & Maxillofac Surg. 2013 Dec;51(8):e215-9.

19. Emes Y, Oncu B, Aybar B, Al-Badri N, İşsever H, Atalay B, et al. Measurement of the lingual position of the lower third molar roots using cone-beam computed tomography. J Oral Maxillofac Surg. 2015 Jan;73(1):13-7.