

Cementogenesis in Patients with Localized Aggressive Periodontitis

Mojgan Paknejad¹, Afshin Khorsand¹, Siamak Yaghobee², Pooriya Motahhari³, Arghavan Etebarian⁴, Mojtaba Bayani⁵✉, Ali Mehrfard⁶

¹Associate Professor, Dental Research Center, Dentistry Research Institute, Tehran University of Medical Sciences, Tehran, Iran; Department of Periodontics, School of Dentistry, Tehran University of Medical Sciences, Tehran, Iran

²Assistant Professor, Dental Research Center, Dentistry Research Institute, Tehran University of Medical Sciences, Tehran, Iran; Department of Periodontics, School of Dentistry, Tehran University of Medical Sciences, Tehran, Iran

³Oral and Maxillofacial Pathologist, Private Practice, Tehran, Iran

⁴Postgraduate Student, Department of Oral and Maxillofacial Pathology, School of Dentistry, Tehran University of Medical Sciences, Tehran, Iran

⁵Postgraduate Student, Department of Periodontics, School of Dentistry, Tehran University of Medical Sciences, Tehran, Iran

⁶Dental Student, Azad University of Medical Sciences, School of Dentistry, Tehran, Iran

Abstract

Objectives: The aim of this study was to determine the cementum thickness in the first molars of patients with localized aggressive periodontitis (LAP) compared to healthy individuals.

Materials and Methods: This case-control study compared eight first molar teeth affected by LAP with eight third molar teeth of healthy individuals. The teeth were disinfected by immersion in 10% buffered formalin solution for three days and were then sectioned. External mesial root surfaces (middle one-third) were evaluated under a stereomicroscope by a blinded pathologist to determine the mean thickness of cementum. SPSS software (version 16.0) and t-test were used for statistical analysis.

Results: Histological examination revealed a significant difference between the two groups in terms of the amount of cementogenesis ($P < 0.001$). The thickness of cementum was higher in the control group ($105.16 \pm 11.5 \mu\text{m}$) than in LAP patients ($86.44 \pm 7.3 \mu\text{m}$).

Conclusion: This study demonstrated the presence of cementum hypoplasia in mesial root surfaces of first molars affected by LAP.

Key words: Dental Cementum; Hypoplasia; Aggressive Periodontitis; Cementogenesis

Journal of Dentistry, Tehran University of Medical Sciences, Tehran, Iran (2015; Vol. 12, No. 5)

✉ Corresponding author:
M. Bayani, Postgraduate Student, Department of Periodontics, School of Dentistry, Tehran University of Medical Sciences, Tehran, Iran

Mbayani@mail.com

Received: 22 January 2015

Accepted: 28 March 2015

INTRODUCTION

Rapid progression, familial aggregation, non-contributory medical history, rarity, severity and early age of onset of clinical manifestations are among the main characteristics of aggressive periodontitis. This destructive periodontal disease results in severe bone loss, tooth loosening and eventual tooth loss. Several etiologies have been suggested for this condition

such as immunodeficiency of patients, bacterial invasion, genetic factors and defective cementogenesis of the involved teeth [1,2]. Cementum deposition is necessary for maintenance of periodontal health, and defective cementum formation may lead to the development of periodontal pockets [3]. Abnormal cementum results in abnormal adhesion of teeth to the surrounding bone and provides

an opportunity for invasion of pathogenic microorganisms [4]. It may also be responsible for the localization of lesion [5].

Thus, cementum structure may be the major determinant of susceptibility to microbial invasion and formation of periodontal pockets. Root surfaces of teeth extracted for LAP have been found to have hypoplastic or aplastic cementum [1,4,6]. Considering all the above, a question arises that whether the abnormal structure of cementum is responsible for the odd pattern and extremely rapid pace of spongy bone destruction in LAP. Two factors have been suggested to be responsible for attachment loss in LAP: *Aggregatibacter actinomycetemcomitans* and cementopathia [1,7]. It should be noted that none of the above mentioned factors have been confirmed as the sole etiology of this condition. Few comprehensive studies have evaluated cementogenesis in LAP patients. Thus, the present study was conducted to evaluate the prevalence of cementum hypoplasia in teeth extracted due to LAP using stereomicroscope for the first time.

MATERIALS AND METHODS

This case-control study was conducted on eight first molars with LAP and eight third molars extracted for orthodontic purposes in healthy individuals without conditions such as operculum or pericoronitis, selected among those referred to the Department of Periodontology of School of Dentistry, Tehran University of Medical Sciences. Written informed consents were obtained from the participants. Teeth in the case group belonged to patients in the age range of 17-20 years and the diagnosis of LAP was made according to clinical and radiographic criteria described by the American Academy of Periodontology [8]. A full-mouth series of periapical radiographs were obtained in LAP patients and in cases with more than 6 mm clinical attachment loss the teeth were extracted due to their hopeless prognosis (Fig. 1).

Before extraction, percentages of sites with bleeding on probing (BOP), probing depth

(PD), and clinical attachment level (CAL) were calculated in the case group [1]. Each extracted tooth in patients with LAP had more than 8 mm of PD and more than 6 mm of CAL. The control group consisted of third molars of healthy individuals in the age range of 19-22 years. Patients were excluded from the study if they met any of the following exclusion criteria: systemic diseases that might have affected the thickness of cementum (such as Paget's disease, calcinosis, rheumatic fever, acromegaly, osteodystrophy, hypothyroidism, calcium deficiency and goiter), para-functional habits, orthodontic appliances, localized periapical pathology, re-implanted teeth, any kind of pulpal conditions affecting root surfaces, radiographic evidence of hypercementosis or root resorption, trauma from occlusion, teeth without antagonists, unilateral chewing habit, open bite and periodontal treatment (mechanical or chemical) within the past one year.

After extraction, the teeth were disinfected in 10% buffered formalin for three days [9] and crowns were then separated from the roots. Fifteen serial sections with 5- μ thickness were cut from the cemento-enamel junction to the apex (with equal intervals of about 200 μ) using the Leica SP1600 saw Microtome (Leica Instruments, Nussloch, Germany) and coded. Mesial surface of mesial roots in the first and third molar teeth and areas adjacent to periodontal pocket walls (middle one-third) were then evaluated under a SZX12 stereomicroscope (Olympus, Tokyo, Japan) for cementum defects by a blind pathologist and cementum thickness was measured using an eyepiece graticule. Inter-rater and intra-rater coefficients of variation (CV) were used to evaluate cementum thickness by two oral pathologists. In this study, the intra-rater and inter-rater CV were 4.7% and 7.7%, respectively. Data were analyzed using SPSS version 16.0.

Independent sample t-test was used to evaluate the differences between the two groups. A p-value of less than 0.05 was considered statistically significant.

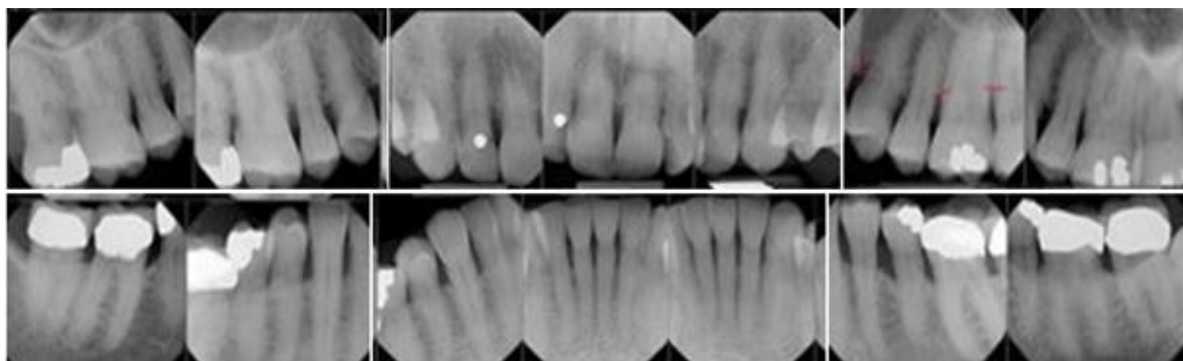


Fig. 1. Intraoral radiographs in a patient with localized aggressive periodontitis showed the presence of localized angular bony defects associated with clinical attachment loss in teeth #3, #14 and #19.

RESULTS

The mean age of patients was 18.5 years (range 17-20 years) in the case group and 20.5 years (range 19-22 years) in the control group.

Histological examination revealed a significant difference between the two groups in terms of the amount of cementogenesis ($P < 0.001$). The thickness of cementum was higher in the control group ($105.16 \pm 11.5 \mu\text{m}$) than in the LAP cases ($86.44 \pm 7.3 \mu\text{m}$).

Stereomicroscopic examination showed significant differences in thickness of cementum between teeth affected with LAP and the control teeth (Fig. 2).

The cementum surface in teeth affected with LAP showed areas of hypoplasia. These hypoplastic areas were seen on both suprabony and intrabony cementum surfaces of the mesial roots in all the examined molars and all over the root surfaces including the intra-alveolar surface (Fig. 3).

Dental calculus was not visible on any teeth with LAP. Cementum hypoplasia was found all over the root surface including the intra-alveolar surface.

Intraoral radiographs taken at the time of extraction were used to determine the approximate location of the alveolar bone level in order to make sure it was an actual hypoplasia rather than an artifact caused by any crevicular bacteria or treatments such as previous scaling and root planning.

DISCUSSION

In spite of its rare occurrence, LAP has been the focus of many investigations aimed at understanding its etiology and pathogenesis [1].

Difficulty in gathering sufficiently large populations, however, has resulted in few clinical studies addressing both diagnostic and therapeutic procedures for these subjects [2]. Studies have demonstrated that LAP patients have a defect in their immune system [7,10-12]. Also, some specific bacteria have been found to be associated with this disease [1,13]. It is not reliable to evaluate the reason for symmetric dissemination pattern of LAP just from the bacterial origin aspect without considering immunological conditions. Despite the presence of deep pockets, calculus and plaque around the affected teeth especially first molars are not significant.

These findings further confirm the hypothesis that abnormal cementum and its defective formation can enhance the invasion of pathogens and development of extensive bone loss [1,6]. It has been demonstrated that cementum matrix structural integrity and biochemical composition are severely compromised in periodontal disease and the provisional matrix produced in the process of periodontal healing is different from that in normal cementum [14].

The idea of defective cementum formation or cementopathia to be the cause of periodontitis and pocket formation was first suggested in

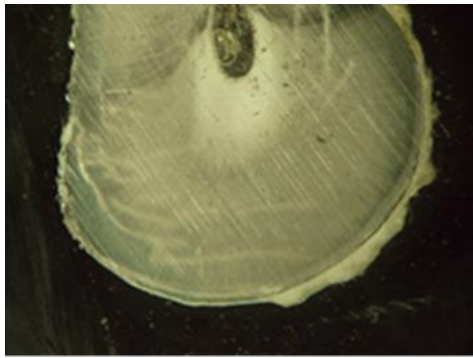


Fig. 2. Mesial surface of a mesial root section in a first molar of a patient with LAP, buccal aspect ($\times 4$ magnification)

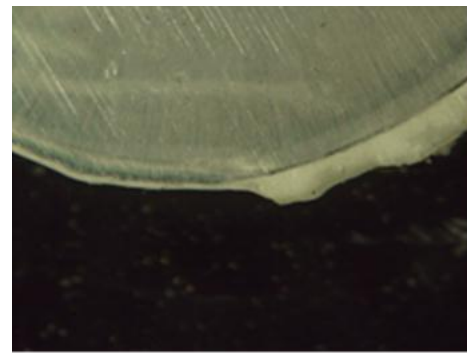


Fig. 3. Arrows indicating cementum thickness in the mesial surface of a mesial root of a first molar of a patient with LAP, buccal aspect ($\times 10$ magnification)

1946 and it was suggested that abnormalities or lack of cementum in patients with LAP would affect periodontal attachment and render the affected teeth highly susceptible to invasion by periodontal pathogens [3]. This may account for the periodontal involvement of the permanent first molars in LAP [3]. Since then, many authors have discussed the high probability of defective cementum deposition in LAP patients [15-18].

In the current study, the mean cementum thickness was measured in the root areas and the mean value of the obtained rates was calculated. In general, apical cementum thickness in molars of the healthy individuals is 150-200 μm and the coronal cementum thickness is considered to be 16-60 μm [1]. The reason for assessment of the middle portion of the external root surface is that this part of the root would be least affected by the pathological factors [1,2]. Our results were in agreement with the observations of previous studies regarding cementum hypoplasia in teeth affected with LAP [17,19-22]. Unlike the results of certain studies [18,23,24], we did not observe cementum aplasia in any of the case samples. This difference could be attributed to the fact that the mentioned studies have used electron microscopy instead of stereomicroscope. Regarding the aims of our study, a stereomicroscope was the best modality for precise measuring of the cementum thickness.

Presence of hypoplasia instead of aplasia indicates that the irritating factor disrupting the formation of cementum was not continuously present and emphasizes on its intermittent effect. Watanabe and colleagues suspected infection with *P. gingivalis* to be associated with periodontal destruction and believed that abnormal cementum formation might have contributed to the patients' periodontal condition [13].

Bimstein et al, also revealed that cementum anomalies may facilitate the establishment and progression of periodontitis in children with leukocyte adhesion deficiency, Down syndrome or hypophosphatasia [11].

After all, we could consider the changes in the cementum thickness as an etiology of the disease and also as a consequence of aggressive periodontitis.

CONCLUSION

Detection of the causative agents and their elimination are the most important steps in treatment of any condition. None of the suggested factors have been specified as the sole causative agent for development of LAP. The present study demonstrated the presence of cementum hypoplasia in mesial root surfaces of first molars affected with LAP. Future studies with a larger sample size are required to precisely evaluate patients' family members and their familial background.

REFERENCES

- 1- Newman MG, Takei H, Klokkevold PR, Carranza FA. Carranza's clinical periodontology: Elsevier health sciences; 2011: 494.
- 2- Lindhe J, Lang NP, Karring T. Clinical periodontology and implant dentistry: John Wiley & Sons; 2008:428.
- 3- Gottlieb B. The new concept of periodontoclasia. *J Periodontol.* 1946 Jan;17:7-23.
- 4- Petruțiu SA, Buiga P, Roman A, Danciu T, Miha CM, Miha D. Degenerative alterations of the cementum–periodontal ligament complex and early tooth loss in a young patient with periodontal disease. *Rom J Morphol Embryol.* 2012;53(4):1087-91.
- 5- Corbet EF, Vaughan AJ, Kieser JB. The periodontally-involved root surface. *J Clin Periodontol.* 1993 Jul;20(6):402-10.
- 6- Shafik SS, Zaki AE, Ashrafi SH. Comparative scanning electron microscopy of root surfaces in juvenile and adult periodontitis: a report of two cases. *Saudi Dent J* 1992 Sep;4(3): 115-119.
- 7- Hussain A. Principles of Drug Therapy in Dentistry. New Delhi, J.P. Medical Ltd., 2012:281.
- 8- American Academy of Periodontology. Parameter on aggressive periodontitis. *J Periodontol.* 2000 May;71(5 Suppl):867-9.
- 9- Lolayekar NV, Bhat VS, Bhat SS. Disinfection methods of extracted human teeth. *J Oral Health Comm Dent.* 2007;1(2):27-9.
- 10- Waldrop TC, Hallmon WW, Mealey BL. Observations of root surfaces from patients with early-onset periodontitis and leukocyte adhesion deficiency. *J Clin Periodontol.* 1995 Feb;22(2): 168-78.
- 11- Bimstein E, Wignall W, Cohen D, Katz J. Root surface characteristics of children teeth with periodontal diseases. *J Clin Pediatr Dent.* 2008 Winter;32(2):101-4.
- 12- Guzeldemir E, Toygar HU. From alveolar diffuse atrophy to aggressive periodontitis: A brief history. *J Hist Dent.* 2006 Winter;5(3):96-9.
- 13- Watanabe H, Umeda M, Seki T, Ishikawa I. Clinical and laboratory studies of severe periodontal disease in an adolescent associated with hypophosphatasia. A case report. *J Periodontol.* 1993 Mar;64(3):174-80.
- 14- Grzesik WJ, Narayanan AS. Cementum and periodontal wound healing and regeneration. *Crit Rev Oral Biol Med.* 2002;13(6):474-84.
- 15- Melnick M, Shields ED, Bixler D. Periodontitis: A phenotypic and genetic analysis. *Oral Surg Oral Med Oral Pathol.* 1976 Jul;42 (1):32-41.
- 16- Page RC, Baab DA. A new look at the etiology and pathogenesis of early-onset periodontitis: Cementopathia revisited. *J Periodontol.* 1985 Dec;56(12):748-51.
- 17- Blomlöf L, Hammarstrom L, Lindskog S. Occurrence and appearance of cementum hypoplasias in localized and generalized juvenile periodontitis. *Acta Odontol Scand.* 1986 Oct; 44(5):313-20.
- 18- Lindskog S, Blomlöf L. Cementum hypoplasia in teeth affected by juvenile periodontitis. *J Clin Periodontol.* 1983 Jul;10(4):443-51.
- 19- Bixler D. Heritable disorders affecting dentin. *Oral Facial Genetics.* St. Louis: C. V. Mosby 1976:227-261.
- 20- Bruckner RJ, Rickles NH, Porter DR. Hypophosphatasia with premature shedding of teeth and aplasia of cementum. *Oral Surg Oral Med Oral Pathol.* 1962 Nov;15:1351-69.
- 21- Pimstone B, Eisenberg E, Silverman S. Hypophosphatasia: Genetic and dental studies. *Ann Intern Med.* 1966 Oct;65(4):722-9.
- 22- Beumer J, Trowbridge HO, Silverman S, Eisenberg E. Childhood hypophosphatasia and the premature loss of teeth: A clinical and laboratory study of seven cases. *Oral Surg Oral Med Oral Pathol.* 1973 May;35(5):631-40.
- 23- Baab DA, Page RC, Morton T. Studies of a family manifesting premature exfoliation of deciduous teeth. *J Periodontol.* 1985 Jul;56(7): 403-9.
- 24- Baab DA, Page RC, Ebersole JL, Williams BL, Scott CR. Laboratory studies of a family manifesting premature exfoliation of deciduous teeth. *J Clin Periodontol.* 1986 Aug;13 (7):677-83.