

## Childhood Oral Lichen Planus: Report of Two Cases

Sageena George<sup>1</sup>, Sheen Ann John<sup>2</sup>✉, Anandaraj S<sup>3</sup>, Jyoti Sumi Issac<sup>4</sup>, Anoop Harris<sup>5</sup>, Reshmi J<sup>6</sup>

<sup>1</sup>Professor, Department of Pedodontics and Preventive Dentistry, PMS College of Dental Science and Research, Trivandrum, India

<sup>2</sup>Reader, Department of Pedodontics and Preventive Dentistry, PMS College of Dental Science and Research, Trivandrum, India

<sup>3</sup>Professor, Department of Pedodontics and Preventive Dentistry, PMS College of Dental Science and Research, Trivandrum, India

<sup>4</sup>Reader, Department of Pedodontics and Preventive Dentistry, PMS College of Dental Science and Research, Trivandrum, India

<sup>5</sup>Senior Lecturer, Department of Pedodontics and Preventive Dentistry, PMS College of Dental Science and Research, Trivandrum, India

<sup>6</sup>Postgraduate Student, Department of Pedodontics and Preventive Dentistry, PMS College of Dental Science and Research, Trivandrum, India

### Abstract

Lichen planus (LP) is a chronic mucocutaneous disease widely recognized in adults, but uncommon in children. The purpose of this paper is to report two cases of LP in children. The diagnosis was made based on clinical and histopathological findings. The treatment consisted of antifungal and multivitamin therapy. Regression of lesions was observed. The patients are still under follow-up. Although LP is uncommon in children, it is necessary to have adequate knowledge about this condition for proper diagnosis and treatment.

**Key words:** Childhood; Lichen Planus; Vaccination

*Journal of Dentistry, Tehran University of Medical Sciences, Tehran, Iran (2015; Vol. 12, No. 5)*

✉ Corresponding author:

S. Ann John, Department of Pedodontics and Preventive Dentistry, PMS College of Dental Science and Research, Trivandrum, India

Drann78@hotmail.com

Received: 7 December 2014

Accepted: 26 March 2015

### INTRODUCTION

Lichen Planus is an inflammatory mucocutaneous disease; it is a very common disease in adults but uncommon in children [1,2]. It can affect the skin, scalp, nails and mucous membranes [3]. In contrast to cutaneous LP, oral LP (OLP) demonstrates clinical variability. An autoimmune basis has been proposed; however, there is evidence suggesting that LP is not a true autoimmune disease but rather a chronic, cell-mediated immune disorder, involving activated lymphocytes and up-regulating cytokine production [1,4].

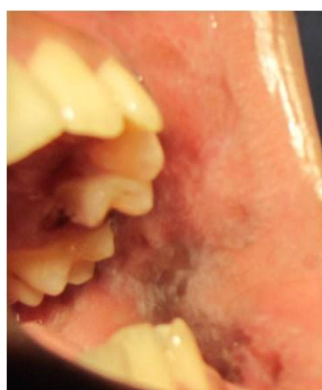Several retrospective reviews have estimated that only 1% -16% of LP patients are younger than 15 years [5,6]. Factors responsible for the rarity of juvenile OLP include a low incidence of autoimmune diseases, systemic diseases,

precipitating factors such as stress and LP related infections in children [7,8]. Lack of awareness among patients and parents may also be a contributing factor. The purpose of this paper is to report two cases of childhood OLP and review the literature in this regard.

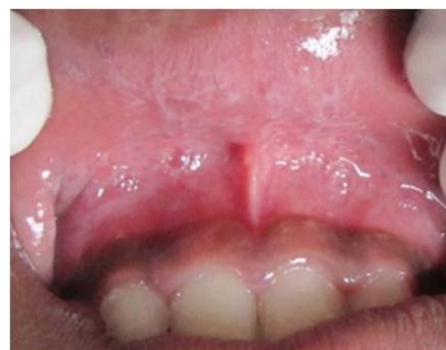### CASE REPORT

**Case 1:** An 8 year-old male patient was referred to the Department of Pedodontics, PMS College of Dental Science and Research with the complaint of pain and white discoloration under the tongue.

The patient had difficulty tolerating spicy food. The medical history revealed that the boy had been vaccinated against Japanese encephalitis one year earlier as part of school immunization program.



**Fig. 1.** White interlacing striae on the left buccal mucosa



**Fig. 2.** Striae on the upper labial mucosa (case 1)

Almost 10 months after this, fluid-filled blisters appeared on both feet and ruptured after 2-3 days.

These were associated with severe itching for which he had taken Ayurvedic medicine.

On examination, the patient had multiple carious teeth. Interlacing white striae were observed on the buccal mucosa bilaterally (Fig. 1), on the ventral tongue mucosa and also on the labial mucosa (Fig. 2).

On palpation, these lesions were non-tender and non-scrapable and the buccal mucosae appeared rough and corrugated. Differential diagnoses included OLP, lichenoid reaction and leukoplakia and a provisional diagnosis of LP was made by correlating the clinical appearance with the age of the patient. The provisional diagnosis was confirmed by histopathological examination following incisional biopsy from the left buccal mucosa. The biopsy specimen showed typical features of LP including the saw-toothed rete pegs, hyperkeratosis and lymphocytic infiltrate (Fig. 3).

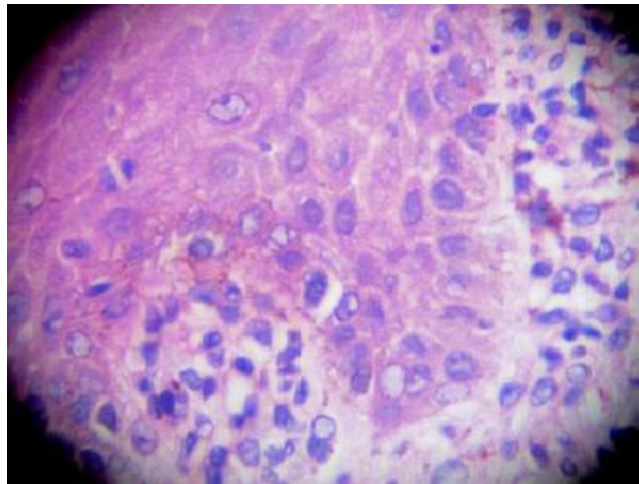
As the lesions were symptomatic, topical antifungal treatment (clotrimazole mouth paint twice daily) was prescribed for the first two weeks.

On the recall session, the burning sensation had reduced considerably and the clinical appearance of the lesions had improved with regard to severity.

**Case 2:** An 8 year-old male patient was referred from a local clinic with burning sensation while eating spicy food. There was no relevant medical history. They gave a history of burning sensation since three months earlier after which a local dentist replaced an amalgam restoration with glass ionomer in the left posterior mandible. Due to no relief, the patient was referred to a hospital. On examination, the patient had a glass ionomer restoration on tooth #75, and all other teeth were caries-free. White interlacing striae were noted on the left buccal mucosa (unilaterally) (Fig. 4). Peripheral to the lesion, there was evidence of pigmentation. On palpation, the lesion was non-scrapable. Differential diagnoses of lichenoid reaction and LP were considered. Incisional biopsy (Fig. 5) revealed saw-toothed epithelial rete pegs, basal cell degeneration with subepithelial lymphocytic infiltrates and melanin incontinence, which confirmed the diagnosis of LP. Routine hematological investigations revealed nothing relevant. After the biopsy, the lesion and the symptoms subsided; thus, no treatment was warranted. The patient is under follow up.

## DISCUSSION

Lichen planus is a chronic inflammatory mucocutaneous disease most frequently seen in the middle aged and the elderly populations with a female to male ratio of approximately 2:1 [2].



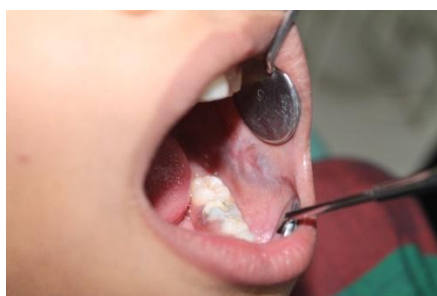**Fig. 3.** Pictomicrograph of case 1 showing saw-toothed rete pegs and lymphocytic infiltration

The first case of LP in a pediatric patient was reported in 1920 [3]. Childhood LP is common in the tropics, and children of Asian origin may be more prone to this condition [1,2,5]. This possibly indicates that a specific genetic predisposition (HLA-dependent) in the Asian race, in spite of a negative family history, may be involved in the pathogenesis of OLP [2,7]. The two cases reported here had Asian origin with no remarkable family history. Another unusual finding in these cases was that both were males. Similar cases have been reported earlier with predominance in Asian males than Caucasian males [2].

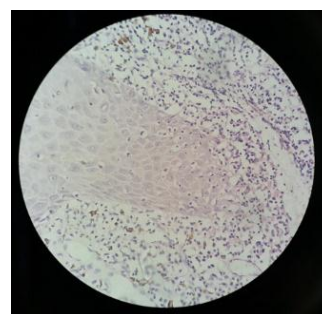
The etiology of LP remains obscure, but recently pathogenic mechanisms with an immune-mediated basis have been proposed [7]. Causes such as allergy to dental restorative materials, local trauma (Koebner phenomenon) [9] and several infections (plaque causing microorganisms)[7] have also been reported. Also, LP has been reported as a complication of hepatitis B vaccination in both children and adults [1,10]. Reactions to measles-mumps-rubella (MMR) and diphtheria-tetanus pertussis-polio (DTaP-IPV) vaccinations can also be related to this disease [3]. Moreover, genetic factors, stress and lifestyle can also play a role.

Our first case gave a positive medical history of vaccination against Japanese encephalitis within the previous year. But this association cannot be confirmed conclusively because there is no available literature regarding development of LP following this particular vaccination. Another possible etiology is the Koebner phenomenon. This agrees with Nnoruka, who reported a relationship between this phenomenon and the occurrence of LP [9]. In our second case, the etiology could be the amalgam restoration but persistence of symptoms even after replacement of amalgam with glass ionomer cement led to the diagnosis of idiopathic LP. The clinical presentation of LP is variable. In many cases, the onset is insidious and patients are unaware of this condition. Some patients report roughness of the lining of the mouth, sensitivity of the oral mucosa to hot or spicy foods, presence of red or white patches or oral ulcerations [11].

Mucosal lesions frequently have a bilateral, symmetrical distribution [12]. In our first case, symptomatic LP lesions were present bilaterally. But in our second case, unilateral presence of the lesion led us to a differential diagnosis of lichenoid reaction. Lichenoid reactions have the same clinical features as LP.



**Fig. 4.** Striae on the left buccal mucosa (case 2)



**Fig. 5.** Pictomicrograph of case 2 showing saw-toothed rete pegs and lymphocytic infiltration

The only difference is in the site of involvement like the palate, which is atypical of LP. In most cases, the cause for lichenoid reactions cannot be identified; hence the diagnosis by exclusion is idiopathic LP. Although the differential diagnoses were considered, histopathological features confirmed the diagnosis of LP in both cases. Use of topical corticosteroids is the most widely accepted treatment for OLP because it reduces patients' pain and inflammation. Several therapies, including intra-lesional injection, retinoids, dapsone, tacrolimus, and ultraviolet light have been tested with varying results [2,3]. Surgical excision, cryosurgery and laser therapy have also been recommended [13]. *Candida albicans* is present in about 37% of OLP lesions. Clinical improvement with relief of symptoms has been reported following the use of amphotericin-B, nystatin and azole antifungals.

Miconazole gel is useful as an adjunct to topical steroids [13]. In our first case, since the patient complained of severe burning sensation, immediate treatment with topical antifungals was done and there was marked reduction in the symptoms. While in our second case, since the lesion subsided spontaneously after the incisional biopsy, no treatment was warranted. There are a number of studies on OLP with regard to its malignant transformation in the past few decades [14]. However, there is considerable controversy regarding the malignant potential of OLP.

## CONCLUSION

Although OLP is considered rare in children, presence of a non-scrapable white lesion should alert the clinicians to consider LP in the list of differential diagnoses. Timely diagnosis with proper treatment oriented towards the etiological factor can prevent further complications especially in young children.

## REFERENCES

- 1- Scully C, Beyli M, Ferreiro MC, Ficarra G, Gill Y, Griffiths M, et al. Update on oral lichen planus: etiopathogenesis and management. *Crit Rev Oral Biol Med.* 1998;9(1):86-122.
- 2- Alam F, Hamburger J. Oral lichen planus in children. *Int J Paediatr Dent.* 2001 May; 11(3):209-14.
- 3- De Moraes PC, Teixeira RG, Tacchelli DP, Bönecker M, Junqueira JL, Oliveira LB. Atypical case of oral lichen planus in a pediatric patient: Clinical presentation and management. *Pediatr Dent.* 2011 Sep-Oct;33(5):445-7.
- 4- Eisen D, Carozzo M, Bagan Sebastian JV, Thongprasom K, Number V. Oral lichen planus: clinical features and management. *Oral Dis.* 2005 Nov;11(6):338-49.
- 5- Kumar V, Garg BR, Baruah MC, Vasireddi SS. Childhood lichen planus (LP). *J Dermatol.* 1993 Mar;20(3):175-7.
- 6- Luis-Montoya P, Domínguez-Soto L, Vega-Memije E. Lichen planus in 24 children with review of the literature. *Pediatr Dermatol.* 2005 Jul-Aug;22(4):295-8.

- 7- Laeijendecker R, Van JT, Tank B, Oranje AP, Neumann HA. Oral lichen planus in childhood. *Pediatr Dermatol.* 2005 Jul-Aug;22(4):299-304.
- 8- Eisen D. The clinical features, malignant potential, and systemic associations of oral lichen planus: A study of 723 patients. *J Am Acad Dermatol.* 2002 Feb;46(2):207-14.
- 9- Nnoruka EN. Lichen planus in African children: A study of 13 patients. *Pediatr Dermatol.* 2007 Sep-Oct;24(5):495-8.
- 10- Woo VL, Manchanda-Gera A, Park DS, Yoon AJ, Zegarelli DJ. Juvenile oral lichen planus: a report of 2 cases. *Pediatr Dent.* 2007 Nov-Dec;29(6):525-30.
- 11- Ismail SB, Kumar SK, Zain RB. Oral lichen planus and lichenoid reactions: Etiopathogenesis, diagnosis, management and malignant transformation. *J Oral Sci.* 2007 Jun;49(2):89-106.
- 12- Boorghani M, Gholizadeh N, Taghavi Zenouz A, Vatankhah M, Mehdipour M. Oral lichen planus: clinical features, etiology, treatment and management; a review of literature. *J Dent Res Dent Clin Dent Prospects.* 2010 Winter;4(1):3-9.
- 13- Lodi G, Scully C, Carrozzo M, Griffiths M, Sugerman PB, Thongprasom K. Current controversies in oral lichen planus: report of an international consensus meeting. Part 2. Clinical management and malignant transformation. *Oral Surg Oral Med Oral Pathol Oral Radiol Endod.* 2005 Aug;100(2):164-78.
- 14- Silverman S Jr, Gorsky M, Lozada NF. A prospective follow up of 570 patients with oral lichen planus: persistence, remission and malignant association. *Oral Surg Oral Med Oral Pathol.* 1985 Jul;60(1):30-4.