

Multiple Developmental Dental Anomalies in a Non-Syndromic Patient: Report of a Rare Simultaneous Occurrence

Maryam Ghasempour¹, Samane Hemmati¹, Samane Gharekhani^{1✉}, Ehsan Mooudi²

¹Associate Professor, Department of Pediatric Dentistry, Faculty of Dentistry, Babol University of Medical Sciences, Babol, Iran

²Postgraduate Student, Department of Pediatric Dentistry, Faculty of Dentistry, Babol University of Medical Sciences, Babol, Iran

³Assistant Professor, Department of Pediatric Dentistry, Faculty of Dentistry, Babol University of Medical Sciences, Babol, Iran

⁴Assistant Professor, Department of Oral & Maxillofacial Radiology, Faculty of Dentistry, Babol University of Medical Sciences, Babol, Iran

Abstract

A case of multiple pulp stones, a supernumerary tooth and a congenitally missing tooth accompanied by several developmental dental anomalies concurrently affecting the upper and lower anterior teeth in an Iranian healthy girl is reported. Developmental tooth abnormalities are usually found in conjunction with certain diseases or conditions. In the present case, although the patient had consanguineous parents and the role of genetics should be considered particularly for autosomal recessive traits, based on the child's family and medical history, no correlation could be established between dental findings and systemic or metabolic diseases.

Key words: Congenital; Missing; Dental Pulp Calcification; Tooth; Supernumerary

Journal of Dentistry, Tehran University of Medical Sciences, Tehran, Iran (2015; Vol. 12, No. 5)

✉ Corresponding author:
S. Gharekhani, Department of
Pediatrics, Faculty of Dentistry,
Babol University of Medical
Sciences, Babol, Iran

Sgharekhani@gmail.com

Received: 7 December 2014

Accepted: 26 March 2015

INTRODUCTION

Dental practitioners may discover important dental findings via routine clinical and radiographic examinations. The number, shape and size of teeth may change during tooth development. There are two common abnormalities in number of teeth called hypodontia and hyperdontia.

The supernumerary teeth in cases of hyperdontia are considered extra teeth to common dental formula. Extra teeth with normal size and shape are defined as supplemental teeth. On the other hand, the malformed additional teeth are known as rudimentary teeth [1].

Supernumeraries may cause complications such as poor esthetics, interfering with normal eruption of adjacent teeth and tooth impaction. They may be found as an isolated dental abnormality or as part of a syndrome. The prevalence of this anomaly is estimated to be 1-3% with a predilection for the Asian population [2]. Most of the supernumerary teeth are located in the anterior region of the maxilla (90%), followed by the mandibular premolar (4%) and maxillary canine regions (1.5%) [2]. Congenital missing of teeth or hypodontia is the most common developmental dental anomaly [3].

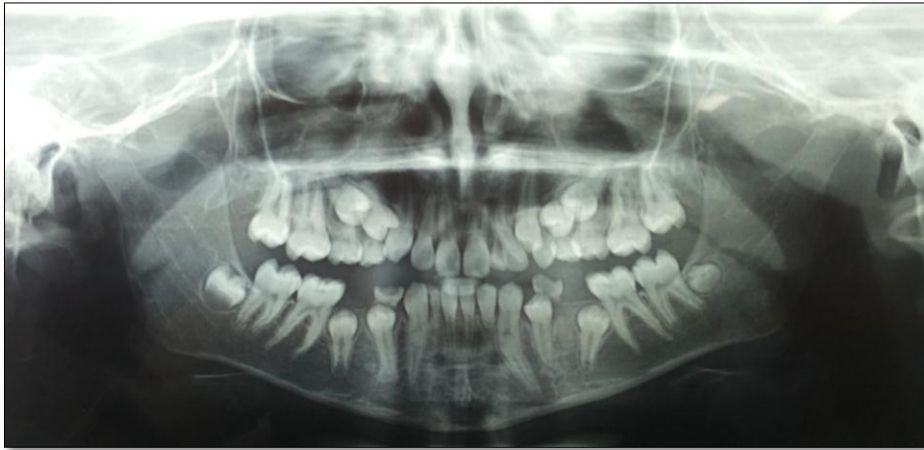

Fig. 1. Panoramic view of the patient

The prevalence of missing teeth excluding third molars varies in different areas with approximately 10.9% prevalence rate in the Iranian population [3]. Tooth germ may fail to develop or differentiate into dental tissues due to different factors. Genetics, radiation, trauma, inflammation and systemic disorders are considered the most common etiologic factors. Dental anomalies cause complications in mastication, speech and aesthetics, which may arise depending on the number of missing teeth [3]. Dens evagination (talon cusp in the anterior region) is an uncommon odontogenic anomaly comprising of a projection on tooth surface [4], which may cause malocclusion and aesthetic problems [5]. Although dens evagination may be found on the occlusal surface of posterior teeth, this anomaly is more commonly seen on the lingual surface of the maxillary lateral incisors (67%) followed by central incisors (24%) and canines (9%) [6]. The overall frequency of dens evagination has been reported to be 1-4% [1] and males are more affected than females [5]. Pulp stones are known as discrete intra-pulpal calcifications frequently found in molars [6-8]. Pulp calcifications vary in size ranging from tiny particles to huge masses that almost obliterate the pulp space [8]. Pulp stones have a clinical significance when root canal therapy is required.

This paper reports simultaneous occurrence of several dental abnormalities in an Iranian healthy girl.

CASE REPORT

A 12-year-old girl was referred to the Department of Pediatrics, Faculty of Dentistry, Babol University of Medical Sciences, Babol, Iran, with the chief complaint of toothache. The patient did not suffer from any systemic diseases, developmental disorders or syndromes. Her family history was unremarkable except that the child had consanguineous parents and her mother also had microdontia and generalized spacing. Extra-oral examination did not reveal any abnormalities. On intra-oral examination, an additional tooth was noted on the left side of the anterior region of the maxilla. A dens evagination (talon cusp) was also observed on the lingual surface of tooth #22, and tooth #82 was over-retained. A panoramic radiograph was ordered to evaluate developmental status of teeth. In the panoramic view, several dental anomalies were detected.

In addition to a supernumerary tooth, congenital missing of tooth #42 and incomplete root formation of tooth #32 were seen. Also, significant root dilacerations were noted in teeth #22 and #33. Interestingly, multiple intra-pulpal opacities were observed in the anterior upper and lower teeth (Fig. 1).

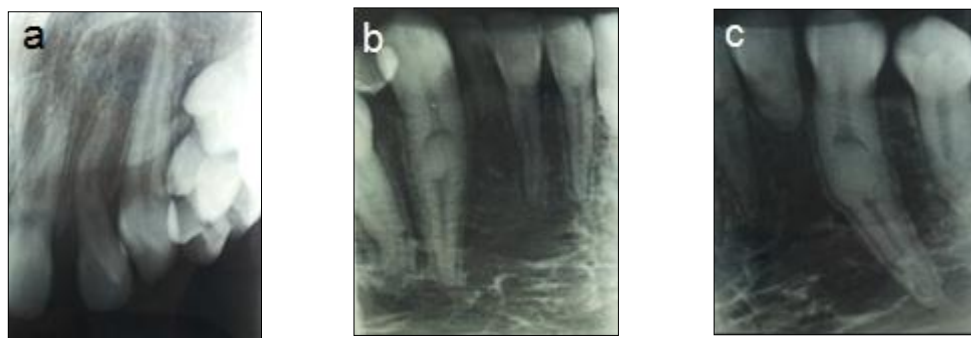

Fig. 2. Periapical radiographs (a: upper left region; b: lower right region; c: lower left region)

For further evaluation, selected periapical radiographs were requested and multiple pulp stones were detected in teeth #31, 41, 33, 43 and 22 (Fig. 2). Since the pulp stones were closely similar to dens invaginations, a cone beam computed tomography (CBCT) scan was ordered to confirm the diagnosis. Additionally, inspection by an explorer did not reveal any pit on the lingual surface of the anterior teeth that could have been mistaken for dens in dent. Based on the CBCT scan, pulp stones were located in the coronal part of the mandibular central and lateral incisors and in the root portion of mandibular canines and maxillary incisors and canines. (Figs. 3 and 4).

DISCUSSION

Supernumerary teeth are developmental disturbances, which occur during odontogenesis and result in excessive number of teeth due to hyperactivity of dental lamina [9]. It may be found as an isolated finding or as part of a syndrome, especially cleidocranial dysostosis [10]. Supernumerary teeth are associated with impaction or delayed or ectopic eruption of permanent teeth, rotation, root resorption and other pathologies in the adjacent teeth, abnormal root formation and space problems [11]. Management of supernumerary teeth depends on the type and position of the tooth. Early removal of supernumeraries is usually indicated in case of impaction, delayed or ectopic eruption of the neighboring teeth and in pathological situations such as cyst formation [10].

In our case, although the supernumerary tooth did not interfere with the eruption of the adjacent teeth, it resulted in crowding and displacement of the permanent incisors of the maxilla necessitating surgical removal to facilitate spontaneous correction of the permanent incisors and therefore the supernumerary tooth was extracted for orthodontic reasons. The patient also had a missing tooth in her lower right lateral region. Both environmental and genetic factors can lead to failure of tooth development [12]. Congenital absence of teeth may result from several factors such as physical obstruction or disruption of dental lamina, space shortage, functional abnormalities of dental epithelium or failure of induction of the underlying mesenchymal tissue, poorly developed alveolar bone and over-retained primary teeth [1].

In our patient, the primary lateral incisor was not a good choice for maintenance as an alternative to replace the missing permanent incisor. However, it was decided to maintain the tooth until the adulthood and then replace it with a dental implant. Incomplete root development and pulp canal obstruction of tooth #32 were also detected. Fortunately, the tooth was not mobile and had a relatively good long-term prognosis. A talon cusp existed on the lingual surface of tooth #22. Some clinical complications related to talon cusps depending on their location include food impaction, dental caries, soft tissue irritation, aesthetic problems and occlusal interference [13].

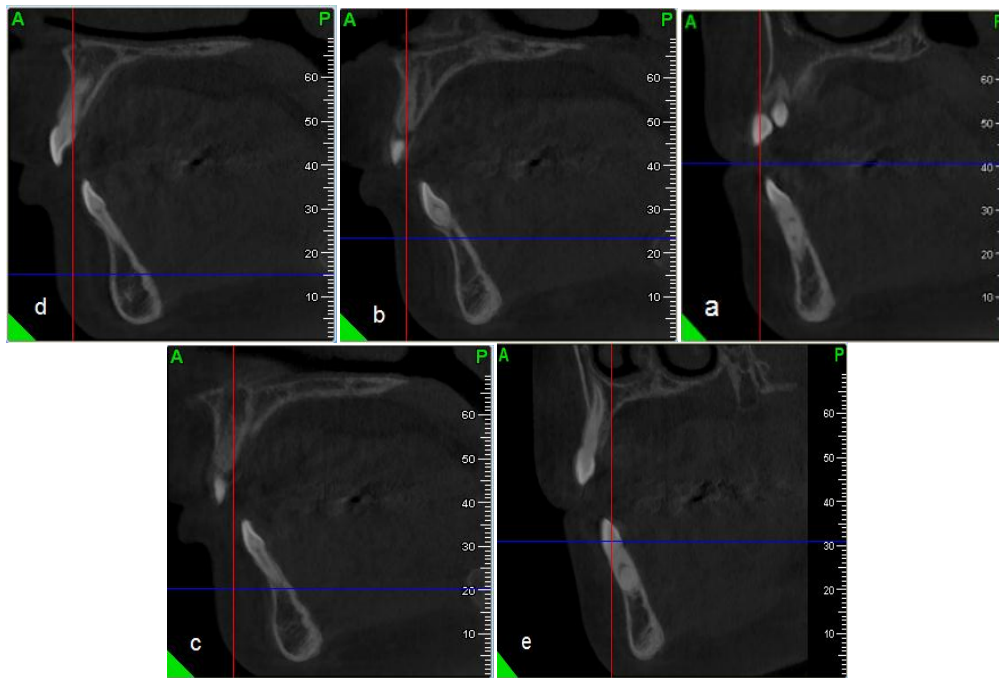


Fig. 3. The CBCT scan of the mandibular anterior teeth (a: left canine; b: left lateral incisor; c: left central incisor; d: right central incisor; e: right canine)

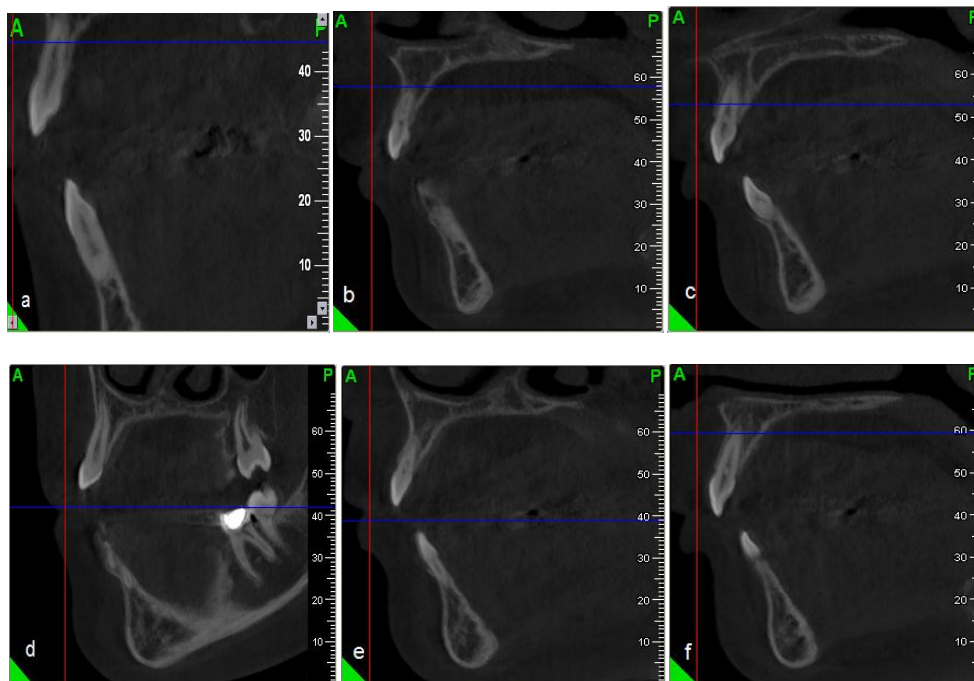


Fig. 4. The CBCT scan of the maxillary anterior teeth (a: left canine; b: left lateral incisor; c: left central incisor; d: right canine; e: right lateral incisor; f: right central incisor)

In our current case, the talon cusp did not cause any problem because of an increased overjet. An incorrect path of eruption was revealed in the panoramic view of upper and lower premolars. With regard to the patient's chronological and dental age, earlier eruption of premolars was expected. In order to accelerate the eruption of premolars via their normal path, upper and lower primary molars were extracted following orthodontic consultation. An interesting finding of the current study was multiple pulp stones. The etiology of pulp stones has been controversial. The causative factors include aging, caries, restorations, periodontal disease and epithelial rests in the pulp tissue. Pulp stones have been found in patients suffering from systemic or genetic diseases such as dentin dysplasia, dentinogenesis imperfecta, anemia and metabolic disorders as well as in patients with orthodontic treatment, traumatic occlusion and syndromes such as Van der Woude, Ehlers–Danlos type I and otodontal syndrome [14]. Hypercalcemia and renal lithiasis are the predisposing factors to pulp stones [15]. Interestingly, multiple pulp stones were found in our patient, a 12-year-old healthy female, which is contrary to the general concept of pulp stone formation in older age groups or in association with certain diseases. Based on our patient's family and medical history, no correlation could be established between dental pulp stones and any systemic disorder in this case. Fortunately, the anterior teeth with obstructed root canals were intact and did not require pulp therapy; otherwise, the root canals might have been inaccessible due to pulp stones. Oral hygiene was instructed to the patient and frequent regular dental recalls were recommended to prevent and manage dental problems.

REFERENCES

- 1- Casamassimo PS, Fields HW, McTigue DJ, Nowak A. Pediatric dentistry: infancy through adolescence. 5th ed. Elsevier Saunders 2013: 54-55, 65.
- 2- Rajab LD, Hamdan MA. Supernumerary teeth: Review of the literature and a survey of 152, cases. *Int J Paediatr Dent.* 2002 Jul;12(4): 244-54.
- 3- Sheikhi M, Sadeghi MA, Ghorbanizadeh S. Prevalence of congenitally missing permanent teeth in Iran. *Dent Res J (Isfahan).* 2012 Dec;9 (Suppl 1):105-11.
- 4- Gupta R, Thakur N, Thakur S, Gupta B, Gupta M. Talon cusp: A case report with management guidelines for practicing dentists. *Dent Hypotheses* 2013; 4(2):67-69.
- 5- Thakur S, Gupta R, Thakur NS, Gupta M. Facial talon cusp on permanent maxillary canine: A rare dental anomaly. *Eur J Gen Dent* 2013; 2(3):324-7.
- 6- Goga R, Chandler NP, Oginni AO. Pulp stones: a review. *Int Endod J.* 2008 Jun;41(6): 457-68.
- 7- Al-Ghurabi ZH, Najm AA. Prevalence of pulp stone (Orthopantomographic-based). *J Baghdad Coll Dent* 2012; 24(2):80-84.
- 8- Marwaha M, Chopra R, Chaudhuri P, Gupta A, Sachdev J. Multiple pulp stones in primary and developing permanent dentition: A report of 4 cases. *Case Rep Dent* 2012; 2012: 408045.
- 9- Wang XP, Fan J. Molecular genetics of supernumerary tooth formation. *Genesis.* 2011 Apr;49(4):261-77.
- 10- Khandelwal V, Nayak AU, Naveen RB, Ninawe N, Nayak PA, Sai Prasad SV. Prevalence of mesiodens among six- to seventeen-year-old school going children of Indore. *J Indian Soc Pedod Prev Dent.* 2011 Oct-Dec; 29(4):288-93.
- 11- Mittal M, Sultan A. Clinical management of supernumerary teeth: A report of two cases. *J Indian Soc Pedod Prev Dent.* 2010 Jul-Sep; 28(3):219-22.
- 12- Townsend G, Hughes T, Luciano M, Bockmann M, Brookc A. Genetic and environmental influences on human dental variation: a critical evaluation of studies involving twins. *Arch Oral Biol.* 2009 Dec;54 Suppl 1:S45-51.

- 13- Hamasha AA, Safadi RA. Prevalence of talon cusps in Jordanian permanent teeth: A radiographic study. *BMC Oral Health*. 2010 Apr; 20;10:6.
- 14- Kantaputra PN, Sumitsawan Y, Schutte BC, Tochraeontanaphol C. Vander Woude syndrome with sensorineural hearing loss large craniofacial sinuses, dental pulp stones and minor limb anomalies: Report of four generations Thai family. *Am J Med Genet*. 2002 Apr 1;108(4):275-80.
- 15- Nayak M, Kumar J, Prasad LK. A radiographic correlation between systemic disorders and pulp stones. *Indian J Dent Res*. 2010 Jul-Sep;21(3):369-73.