



## Anterior Mandibular Composite Graft for Regeneration of Knife-Edge Ridges in Implant Surgery: A Treatment Case Report

Isa Abdi<sup>1</sup>, Donya Maleki<sup>2\*</sup>

1. Dental Science Research Center, Department of Oral and Maxillofacial Surgery, Faculty of Dentistry, Guilan University of Medical Sciences, Rasht, Iran
2. Student Research Committee, Faculty of Dentistry, Guilan University of Medical Sciences, Rasht, Iran

### Article Info

**Article type:**  
Case Report

**Article History:**  
Received: 15 Jul 2019  
Accepted: 2 Dec 2019  
Published: 23 May 2020

**\* Corresponding author:**  
Student Research Committee, Faculty of  
Dentistry, Guilan University of Medical  
Sciences, Rasht, Iran

Email: donyamaleki93@gmail.com

### ABSTRACT

Implant insertion into an atrophic knife-edge ridge with non-simultaneous extraction of anterior and posterior teeth is challenging; this is why bone regeneration before implant placement is of great importance. One of the best sources for reconstruction is an intraoral autogenous bone graft. A composite bone graft is a combination of autogenic bone and mucosal flap that provides adequate blood supply and fixation compared to conventional (from the mandibular symphysis or ramus) and extraoral bone grafts.

**Keywords:** Alveolar Ridge Augmentation; Alveolar Bone Grafting; Dental Implants

- **Cite this article as:** Abdi I, Maleki D. Anterior Mandibular Composite Graft for Regeneration of Knife-Edge Ridges in Implant Surgery: A Treatment Case Report. *Front Dent.* 2020;17:10. doi: 10.18502/fid.v17i1.3968

### INTRODUCTION

Modern implantology has introduced new methods for the treatment of edentulous patients, such as the use of implants [1], bone grafts, bone distraction, and bone splitting [2]. With all these techniques, the prognosis and survival rate of implants still depend on the characteristics of the alveolar bone [3]. When the anterior ridge of the mandible is thin but high in the vertical dimension, the clinician tends to use guided bone regeneration or bone grafts [4]. Insertion of implants into an atrophic knife-edge ridge with non-simultaneous extraction of anterior and posterior teeth is still difficult and complex; in such cases, bone augmentation to regenerate

the vertical and horizontal dimensions is necessary to achieve an ideal site for implant placement [5]. This is even more complicated in the aesthetic zone where the preservation of the natural appearance is mandatory [2]. In addition to the characteristics of bony defects, the site of implant placement is also important [1,6].

By searching keywords such as “atrophic ridge”, “bone graft”, “augmentation”, and “dental implant” in the PubMed, MEDLINE, and Google Scholar databases, one can find articles related to the treatment of atrophic ridges [1-3,5]. In 2001, Tecimer and Behr [5] reported that the use of intraoral bone grafts (from the external oblique ridge and

symphysis) fixed by titanium bone screws provides better outcomes than extraoral ones for implant placement in the molar site of atrophic ridges due to good accessibility and quality, lack of scarring, and limited extension of the surgical field.

This treatment case report highlights a new approach for anterior mandibular composite grafting to regenerate knife-edge ridges before implant surgery.

## CASE REPORT

### *Patient examination:*

- *History:*

a 63-year-old edentulous female referred for implant treatment. She preferred implants over a full denture as her chief complaint was chewing problems.

Furthermore, aesthetics were very important to her. She reported a history of hyperlipidemia and Atorvastatin consumption. The routine laboratory tests were requested. The results were within the normal range.

- *Clinical assessment:*

The patient had a maxillary partial denture from tooth #2 to tooth #5 and from tooth #12 to tooth #15 when she referred. In the mandible, she had a partial denture replacing tooth #18 to tooth #22 on the left side and tooth #27 to tooth #31 on the right side; however, six months ago, teeth #23 to #26 were extracted. The soft tissue of the edentulous areas was healthy and normal with no inflammation.

- *Radiographic examination:*

A panoramic radiograph had been prescribed six months ago (before the extractions). Cone-beam computed tomography (CBCT) scans and a new panoramic radiograph were taken after teeth extraction for the assessment of ridge height, width, shape, quality, and *quantity*. The ridge was flat in the posterior region of the mandible and knife-edge in the anterior region (uneven resorption). Based on the prosthodontist's recommendations, the graphs, and the custom-made stent, dental implant placement was planned.

- *Diagnosis:*

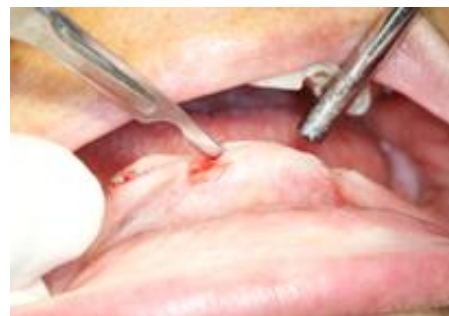As the anterior region of the mandible was knife-edge (with adequate vertical dimension and insufficient horizontal dimension), the placement of implants with suitable diameters was not possible. Besides, the height and volume of the posterior region were decreased, making the placement of implants with good lengths difficult.

- *Treatment plan:*

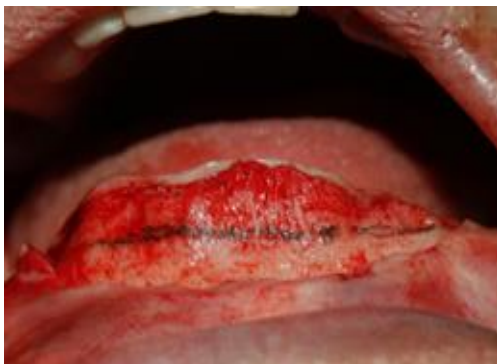Considering the treatment costs and the patient's state of edentulism, the treatment plan involved an overdenture for the mandible. After consulting the prosthodontist, a 4-unit bone level implant (3.3×13 mm, UF, Hex connection, Dio implant, Busan, South Korea) at the site of teeth #21, #23, #26, and #28 was offered according to the custom-made stent. Written consent was received from the patient.

- *Surgical protocol:*

Immediately before surgery, an oral nonsteroidal anti-inflammatory drug (NSAID; Ibuprofen 400 mg: Gelofen®, Dana Corp., Tabriz, Iran) was administered. We asked the patient to mouthwash with a 1.2% chlorhexidine solution for one minute. Local anesthesia was administered via a bilateral mental nerve block and local infiltration (lidocaine with 1:100,000 epinephrine, Xylopen®, Exir Co., Tehran, Iran). Afterward, a 2mm buccal incision was made using a No.15 surgical blade from the crest of the alveolar ridge in the anterior region of the mandible, extending from tooth #20 to tooth #29. The buccal subperiosteal flap was elevated. No releasing or elevated flap was made on the crest or the lingual side (Fig. 1).



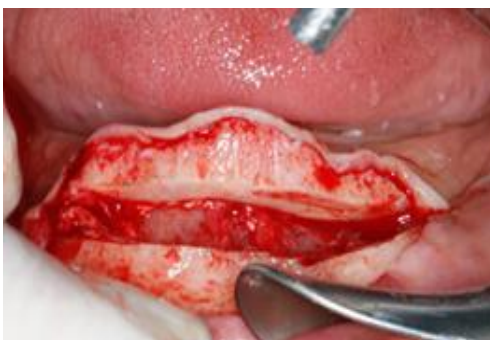**Fig. 1.** A 2 mm incision buccalized from peak of crest in anterior region of mandible



**Fig. 2.** Determining a 4 mm height of bone

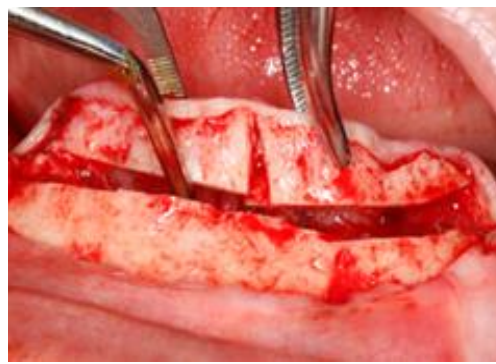
After exposing the bone on the buccal side, a bone segment from tooth #21 to tooth #28 with a 4mm height in the midline was measured using a caliper (Fig. 2). The marked bone was cut as follows:

1. The superior (crestal) part was separated using a reciprocal saw and an osteotome.
2. A subperiosteal composite graft was released on the lingual side since the lingual gingiva was intact. The lingual mucosal attachment was detached, and a 5mm pocket was made (Fig. 3).
3. Using a fissure bur, an incision was made in the midline of the separated bone segment for sectioning the bone into two halves. The subperiosteal attachment was preserved (Fig. 4).



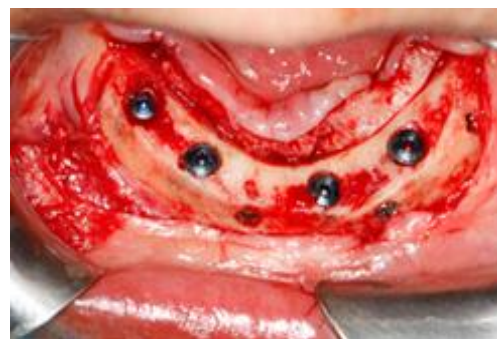**Fig. 3.** The subperiosteal composite graft

Afterward, the two segments were inserted lingually and were leveled and adapted to the remaining bone in the anterior region. Then, holes were drilled on both lingual and buccal segments while the operator's fingers fastened the segments together.



**Fig. 4.** Breaking the segment in two lateral parts

The holes in the separated crestal segment were larger than the lingual ones to provide better adaptation and lag screw effect. The holes were placed at least 2 mm far from the implant insertion site (Fig. 5).



**Fig. 5.** Interval of holes from implants

Two lag screws (diameter: 1.6 mm, length: 8 mm; Jeil Medical Corp., Seoul, South Korea) were inserted to fix the segments. The length of the screw was selected based on the width of the segments. This length should not be more than the above-mentioned width or it will perforate the lingual gingiva. After fixing the segments, the horizontal dimension was 2mm larger than the diameter chosen for the implants; therefore, the 4-unit implant was placed immediately. If the horizontal dimension is not enough to place the implants, it is better to consider 3 to 4 months as the healing time for conventional loading protocol [7]. The cover screw was inserted for each implant. The surgical area was irrigated using normal saline (0.9% Sodium Chloride®, Iranian Parenteral and Pharmaceutical Co., Tehran, Iran).

Finally, the soft tissue was sutured using 4-0 silk suture (Supa, Tehran, Iran) with minimal trauma.

- *Postoperative considerations:*

After surgery, a single dose of dexamethasone (8mg; to reduce inflammation) and Penicillin G (800mg; to prevent infection) was administered intramuscularly. In addition, Amoxicillin 500 mg was prescribed every 8 hours, as well as chlorhexidine mouthwash (three times a day). The patient was instructed to use cold compress every 20 minutes for the first 24 hours and soft food for six weeks.

- *Follow-up:*

Four months after surgery, a new CBCT scan was taken, and the achieved buccolingual thickness was evaluated. No resorption was detected. After the radiographic and clinical assessments, four implants with appropriate diameters and lengths were inserted. The status of the implants was checked for three months using panoramic radiographs. The lag screws were removed after uncovering the implants.

## DISCUSSION

Absence of teeth leads to bone resorption and ridge atrophy; these are common consequences of non-simultaneous teeth extraction, especially in the mandible [8]. Implant placement is an ideal preventive approach in these cases. According to Padmanabhan and Gupta [9], autogenous bone grafting is a trustworthy technique to regenerate knife-edge ridges and to prepare them for implant placement. Jivraj and Chee [10] reported that bone augmentation provides excellent aesthetic results. A popular approach among autogenous bone grafting techniques is onlay grafting with membranes and autografts; however, this approach can be time-consuming and inconvenient [11]. The use of the iliac crest, mental symphysis, external oblique ridge, and ascending ramus of the mandible as autogenous grafts is another common technique although inadequate gained bone and susceptibility of inferior alveolar nerve and mental nerve damage should be considered as disadvantages [11].

In the present case report, the use of a combination of autogenic bone and mucosal flap has been demonstrated, which provided adequate blood supply and fixation compared to conventional grafts. By adopting this approach, not only blood nutrition was supplied throughout the surgery but also the risk of flap infection was reduced. In uneven knife-edge ridges with sharp borders, movement of the prosthesis causes pain and discomfort [12].

These problems can be avoided by using the presented technique. It is important to measure the diameter and height of the available bone before choosing this approach because an anterior vertical defect can limit the use of this technique.

The preservation of the subperiosteal attachment during surgery is difficult. Besides, the available bone is limited, which may lead to the use of synthetic bone grafts. One limitation of this procedure is the reduction of the vertical facial dimension. Therefore, in patients with a prognathic profile, the exacerbation of facial concavity is expected; however, the lost vertical dimension can be reconstructed by a prosthetic approach. Therefore, proper case and technique selections are of great importance when considering this approach.

## CONCLUSION

In the regeneration of knife-edge ridges in the anterior region of the mandible before implant surgery, a combination of autogenic bone and mucosal flap is recommended as it provides adequate blood supply and fixation.

## ACKNOWLEDGMENTS

This study was partially supported by the Department of Oral Surgery and Implantology of Guilan University of Medical Sciences (GUMS; Rasht, Guilan, Iran).

## CONFLICT OF INTEREST STATEMENT

None declared.

## REFERENCES

1. Bertl K, Subotic M, Heimel P, Schwarze UY,



- Tangl S, Ulm C. Morphometric characteristics of cortical and trabecular bone in atrophic edentulous mandibles. *Clin Oral Implants Res.* 2015 Jul;26(7):780-7.
2. Rajput NS, Bhaskar J, Valiathan M, Chandrasekaran SC, Alam MN. Placement of dental implant in a knife edge ridge in anterior aesthetic zone. *J Clin Diagn Res.* 2013 Oct;7(10):2376-7.
  3. Al-Nawas B, Schiegnitz E. Augmentation procedures using bone substitute materials or autogenous bone - a systematic review and meta-analysis. *Eur J Oral Implantol.* 2014 Summer;7 Suppl 2:S219-34.
  4. Wang HL, Al-Shammari K. HVC ridge deficiency classification: a therapeutically oriented classification. *Int J Periodontics Restorative Dent.* 2002 Aug;22(4):335-43.
  5. Tecimer D, Behr MM. Use of autogenous bone grafting to reconstruct a mandibular knife edge ridge before implant surgery: a case report. *J Oral Implantol.* 2001;27(2):98-102.
  6. Wallace SS, Froum SJ. Effect of maxillary sinus augmentation on the survival of endosseous dental implants. A systematic review. *Ann Periodontol.* 2003 Dec;8(1):328-43.
  7. Payne AGT, Zarb G. Implant Overdentures. In: Zarb G, Hobkirk J, Eckert S, Jacob R (editors). *Prosthetic Treatment for Edentulous Patients. Complete Dentures and Implant-Supported Protheses.* St. Louis, Missouri: Elsevier Mosby, 2013:330-40.
  8. Katna V, Chopra V, Chadda A, Gaur A. Management of knife edge ridge. A case report. *Indian J Dent Sci.* 2011 Dec;3(5):57-8.
  9. Padmanabhan TV, Gupta RK. Comparison of crestal bone loss and implant stability among the implants placed with conventional procedure and using osteotome technique: a clinical study. *J Oral Implantol.* 2010 Dec;36(6):475-83.
  10. Jivraj S, Chee W. Treatment planning of implants in the aesthetic zone. *Br Dent J.* 2006 Jul;201(2):77-89.
  11. Reininger D, Cobo-Vázquez C, Rosenberg B, López-Quiles J. Alternative intraoral donor sites to the chin and mandibular body-ramus. *J Clin Exp Dent.* 2017 Dec 1;9(12):e1474-e1481.
  12. Goiato MC, Ribeiro AB, Dreifus Marinho ML. Surgical and prosthetic rehabilitation of patients with hemimandibular defect. *J Craniofac Surg.* 2009 Nov;20(6):2163-7.