



Endodontic Management of Complicated Vertical Crown-Root Fracture in Deciduous Molars: Report of Two Cases

Richa Kumari¹, Neeraj Kumar^{2*}, Krishan Gauba³

1. Unit of Paedodontics and Preventive Dentistry, Oral Health Sciences Centre, Post graduate Institute of Medical Education and Research, Chandigarh, India
2. Department of Dentistry, Government Medical College, Khandwa, Madhya Pradesh, India
3. Unit of Paedodontics and Preventive Dentistry, Oral Health Sciences Centre, Post graduate Institute of Medical Education and Research, Chandigarh, India

Article Info	ABSTRACT
<p>Article type: Case Report</p> <hr/> <p>Article History: Received: 29 Apr 2020 Accepted: 13 Nov 2020 Published: 28 Dec 2020</p> <hr/> <p>*Corresponding author: Department of Dentistry, Government Medical College, Khandwa, Madhya Pradesh, India</p> <hr/> <p>Email: dr.neeraj001@gmail.com</p>	<p>Dental traumatic injuries most commonly occur in the primary and mixed dentition, but vertical complicated crown-root fractures are rarely seen in children. Clinical and radiographic examination of these injuries helps in accurate diagnosis and management. According to the International Association of Dental Traumatology guidelines, treatment usually involves extraction followed by placement of a space maintainer. Cases of complicated crown and root fracture in primary posterior teeth are often unnoticed by the clinician, at the time of injury. Two such patients are presented, who reported symptoms a few weeks after their accident. They were managed conservatively by initial stabilization with stainless steel crowns, followed by root canal therapy. This report highlights the need for referral to specialists and emphasizes the importance of conservative management of primary teeth to maintain functional demands.</p> <p>Key words: Crowns; Pulpectomy; Wounds and Injuries; Tooth Fractures; Tooth, Deciduous; Endodontics</p>
<p>➤ Cite this article as: Kumari R, Kumar N, Gauba K. Endodontic Management of Complicated Vertical Crown-Root Fracture in Deciduous Molars: Report of Two Cases. <i>Front Dent.</i> 2020;17:39.</p>	

INTRODUCTION

Traumatic injuries to the oral cavity are considered as one of the most common dental health issues in children younger than 6 years of age. These injuries generally range from 11%-30.2% in the primary dentition with a reported crown-root fracture prevalence of 2%-2.5% [1,2]. Their peak incidence occurs between the ages of 2-4 years in the primary dentition and the most common type is luxation injury, which develops because of the soft and pliable nature of the alveolar bone in children [3]. Direct impact to the mouth particularly causes luxation of the primary maxillary incisors. However, indirect impact such as trauma to the chin may result in perpendicular or obliquely directed forces, leading to crown-root fractures [4].

The most common sources of traumatic injuries to children includes falls, collisions, motor vehicle accidents, contact sports, and malocclusions like increased over-jet and incompetent lips [5]. Crown-root fractures of primary molars are classified into 'uncomplicated' and 'complicated' types, based on pulpal involvement. The treatment method most commonly reported for complicated crown-root fractures of primary teeth is extraction of the tooth followed by placement of a space maintainer, as per the International Association of Dental Traumatology guidelines [6]. However, preservation of the tooth should be the main consideration, as primary teeth are essential for maintaining growth of the alveolar bone, arch length and mastication.

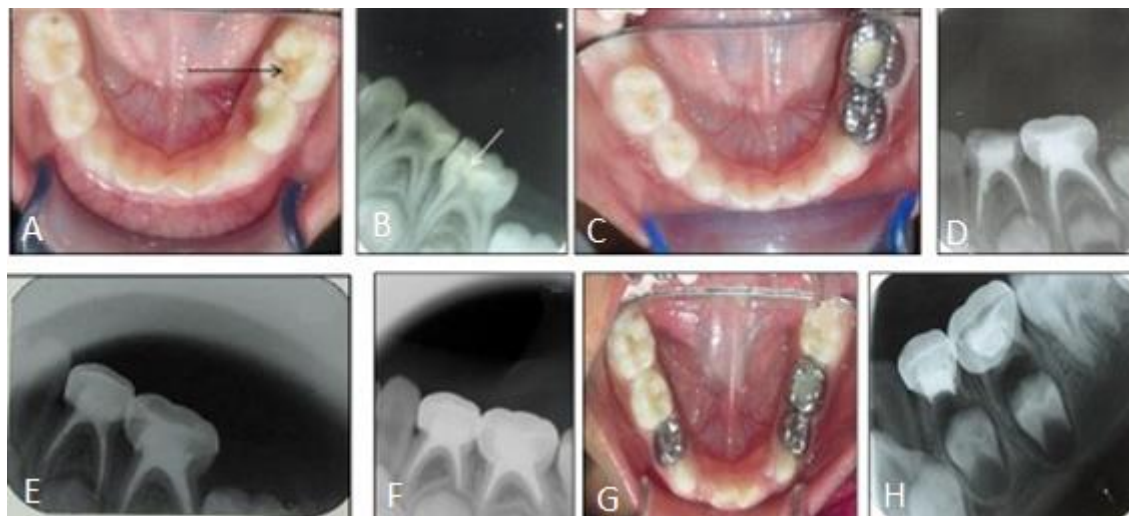


Fig. 1. Representative images of crown-root fracture management of Case 1. Preoperative intra oral view (1A) and periapical radiograph (1B) of lower first and second primary molars, showing crown-root fracture. Stainless steel crowns were placed followed by pulpectomy (1C,1D). Twelve-month (1E), 24-month (1F) and 36-month (1G,1H) follow-up were uneventful

The cases presented herein, demonstrate the conservative management of complicated crown-root fractures of deciduous molars which were stabilized by stainless steel crowns, followed by endodontic treatment and resin restoration. These cases were clinically and radiographically followed for 36 months without any complications.

CASE REPORT

A 5-year-old girl reported to the unit of Pediatric Dentistry with a chief complaint of 'pain in her left lower back teeth', during chewing. There was a history of trauma from falling off a swing, 4 months back. Her chin had struck directly against the ground, leading to a deep laceration which was immediately sutured by a private practitioner. The patient did not exhibit dental pain at that time. After 4 months, she started experiencing pain in her left lower posterior teeth while eating. Medical history revealed no systemic illness or history of previous hospitalization. On examination there was evidence of a healed laceration on the chin with no facial asymmetry and mouth opening was normal. Intraoral examination revealed a complicated crown-root fracture of the left first and second primary mandibular molars, which was confirmed by a periapical radiograph (Figures 1A and 1B).

We decided to preserve the primary teeth and after explanation to the parents, consent was obtained. Stabilization of the fractured segments was done with flowable composite (Filtek Z350 XT, 3M, ESPE, USA) followed by crown preparation, placement of stainless steel crowns (3M, ESPE, USA) and cementation, using GIC luting cement. Under rubber dam isolation, access was gained through the crown followed by biomechanical preparation, obturation with metapex (Metapex Biomed Co. Ltd, South Korea), restoration with GIC (Fuji II) and composite (3M, ESPE, USA) (Figures 1C and 1D). The child was instructed to maintain oral hygiene and all other carious teeth were restored during the subsequent appointments. On the recall visits on months 12 and 24 (Figures 1E and 1F), there was no clinical or radiographic pathology, with physiologic root resorption. The patient was asymptomatic clinically and radio-graphically after 36 months and showed continuation of physiologic root resorption (Figures 1G and 1H).

Case 2

A 5-year-old girl reported to our department with a chief complaint of 'pain in her upper left back tooth' while eating. The patient's father gave a history of falling from a height of 5 feet while playing.

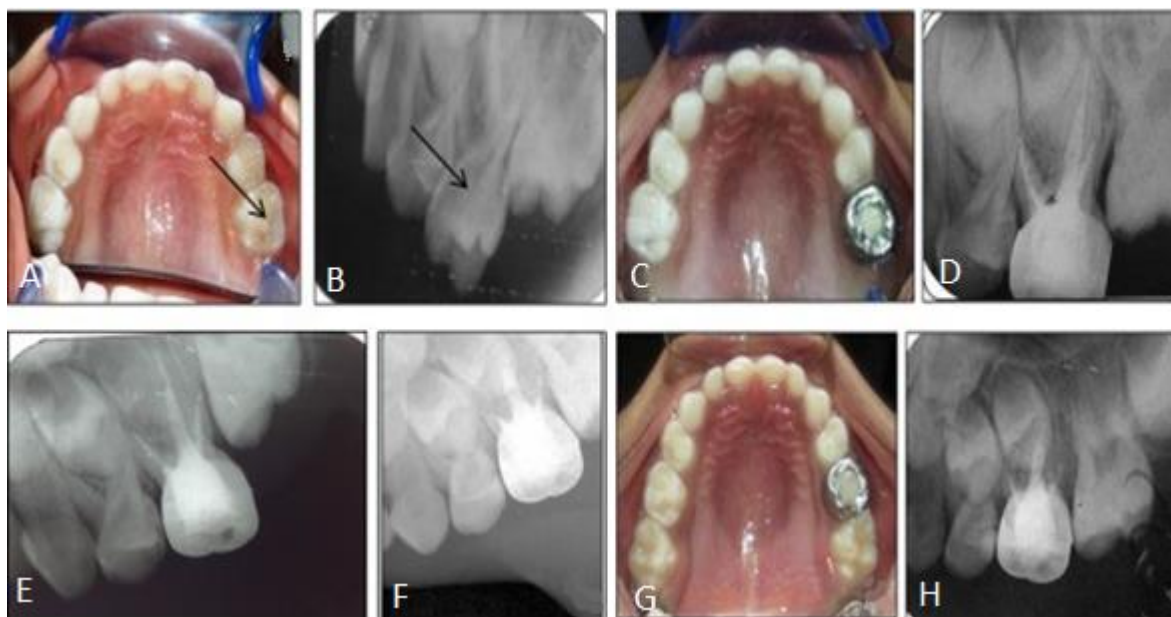


Fig. 2. Treatment of crown-root fracture in Case 2. Preoperative intraoral photograph (2A) and periapical radiograph (2B) show crown-root fracture in the upper left second primary molar. A stainless steel crown was placed, after which pulpectomy was performed (2C, 2D). No failure was observed in the 12-month (2E), 24-months (2F) and 36-months (2G, 2H) follow-up

She suffered abrasive injuries on the right side of her face, chin and neck, which were treated in a private hospital. No active intervention had been done for dental pain. The patient reported to the department 10 days after the day of injury. Medical history was not contributory. Extraoral examination revealed healed abrasive injuries on the right side of the forehead, cheek, chin and neck. Intraoral examination showed a crown fracture extending from the cervical region to the occlusal surface of the left maxillary second primary molar with subgingival extension of the fracture line (Figures 2A and 2B). There was no periapical abscess or fistula. Because of the patient's age, conservative treatment was opted similar to that discussed in Case 1, *i.e.*, stabilization with stainless steel crown followed by endodontic therapy of the offending tooth (Figures 2C and 2D). The child was followed for 12, 24 (Figures 2E and 2F) and 36 months with no clinical/radiographic signs of failure (Figures 2G and 2H).

DISCUSSION

Crown-root fractures resulting from indirect

forces caused by a blow to the chin region, are extremely rare. Holan et al [7] reported that 32%-35% of direct injuries to the mental area may result in coronal fractures of primary molars. In both presented cases, the children were approximately 5 years old, which corresponds to the peak age-range of traumatic dental injuries. The fact that the etiology in both patients was falling while playing, also coincides with the most frequent cause of dental traumatic injuries in children [1,2].

In most instances, crown-root fractures remain undetected immediately after trauma, but they may be manifested a few days/months later when the patient starts experiencing pain/gingival inflammation [8]. In both presented cases, primary teeth were fractured because of a sudden blow to the chin, which dissipated forces indirectly to the posterior primary teeth. Limited cases exist in the literature where more than two teeth had been fractured. According to a previous study, only two out of 96 children had five fractured primary molars, while 20.3% of the children had one tooth fractured due to trauma to the chin region [7].

Management of simple and complicated crown fractures in primary teeth varies from simple grinding of sharp cusps to pulp capping, pulpotomy, pulpectomy, restoration with adhesive resins or stainless steel crowns, and extracting the offending tooth followed by use of a space maintainer. Most authors have opted for radical treatment of fractured teeth in the form of extraction and space maintenance [9]. Examples include Morisaki et al [10], who selected this treatment to manage a crown-root fracture of a lower left first primary molar in a 21-month-old boy and others [11,12] that reported four complicated crown-root fractured primary molars, which were extracted because of pulp involvement and extensive damage.

Limited case reports exist where vertical complicated crown fractures are managed conservatively with follow-up ranging from 0-15 months. It is noteworthy that following these types of cases is extremely important and it is therefore necessary to advise the parents or patients on the importance of clinical and radiographic examination to prevent more serious complications like possible effects on succedaneous permanent teeth. Cuevas et al [13] reported necrosis/resorption of teeth following traumatic injuries to the chin region. Therefore, the present cases are on regular follow-up and have remained asymptomatic for 36 months.

Both the present cases were initially examined by a general physician who only treated their extraoral injuries and no referral for intraoral examination was recommended. Therefore, delay in diagnosis and treatment as described in these cases, often occurs. As a result, physicians are advised to take notice of unusual dental injuries, so that they can provide children with dental referrals. Dental professionals, especially pedodontists, should be aware of the dental consequences of traumatic injuries to the chin. They should decide which treatment option (conservative or radical) should be adopted for the patient keeping in mind the patient's age, extent of fracture, prognosis of the tooth etc.

CONCLUSION

This case report emphasizes the importance of general physicians/dentists referring cases with chin injuries to pedodontists. It also highlights the need for conservative management of fractured primary teeth so that their function could be maintained and the clinical problems that may arise after extraction can be better managed.

ACKNOWLEDGMENTS

The authors want to acknowledge that the present case was managed at Post graduate Institute of Medical Education and research, Chandigarh. The details related to the present case were not copied from any other sources. The authors have no conflict of interest.

CONFLICT OF INTEREST STATEMENT

None declared.

REFERENCES

1. Hargreaves JA, Cleaton-Jones PE, Roberts GJ, Williams S, Matejka JM. Trauma to primary teeth of South African pre-school children. *Endod Dent Traumatol.* 1999 Apr;15(2):73-6.
2. Andreasen JO, Andreasen FM. *Testbook and Color Atlas of Traumatic Injuries to the Teeth.* 3rd ed. Copenhagen: Munksgaard. 1993:257-76.
3. Kargul B, Çağlar E, Tanboga I. Dental trauma in Turkish children, Istanbul. *Dent Traumatol.* 2003 Apr;19(2):72-5.
4. Maréchaux SC. Chin trauma as a cause of primary molar fracture: report of case. *ASDC J Dent Child.* 1985 Nov-Dec;52(6):452-4.
5. Schatz JP, Joho JP. A retrospective study of dento-alveolar injuries. *Endod Dent Traumatol.* 1994 Feb;10(1):11-4.
6. Flores MT. Traumatic injuries in the primary dentition. *Dental traumatology.* 2002 Dec;18(6):287-98.
7. Holan G. Traumatic injuries to the chin: a survey in a paediatric dental practice. *Int J Paediatr Dent.* 1998 Jun;8(2):143-8.
8. Tejani Z, Johnson A, Mason C, Goodman J. Multiple crown-root fractures in primary molars and a suspected subcondylar fracture following trauma: a report of a case. *Dent Traumatol.* 2008 Apr;24(2):253-6.
9. Götze Gda R, Barreira AK, Maia LC. Crown-root fracture of a lower first primary molar: report of an unusual case. *Dent Traumatol.* 2008

Jun;24(3):e377-80.

10. Morisaki I, Kitamura K, Ooshima T, Sobue S. Vertical crown-root fracture of the mandibular first primary molar in a one-year-old child. *Endod Dent Traumatol.* 1989 Aug;5(4):197-9.

11. Needleman HL, Wolfman MS. Traumatic posterior dental fractures: report of a case. *ASDC J Dent Child.* 1976 Jul-Aug;43(4):262-4.

12. Suher T, Fixott HC. Multiple accidental

fractures of posterior primary teeth (a case report). *J Dent Child.* 1952;2013:115-7.

13. Gongora-Cuevas G, Rosales-Berber MA, Ruiz-Rodriguez MS, Martinez-Zumaran A, Garrocho-Rangel A, Pozos-Guillen AJ. Bilateral vertical complicated fracture of mandibular first primary molars associated with trauma: Report of an unusual case. *Pediatr Dent J.* 2012 Mar 31;22(1):72-7.