



Dental Management of a Patient with Pulmonary Atresia and Ventricular Septal Defect

Ghassem Ansari¹, Mahsa Mansouri¹, Leila Eftekhar^{2*}

1. Department of Pediatric Dentistry, Dental School, Shahid Beheshti University of Medical Sciences, Tehran, Iran
2. Department of Pediatric Dentistry, Dental School, Alborz University of Medical Sciences, Karaj, Iran

Article Info

Article type:

Case Report

Article History:

Received: 29 Nov 2020

Accepted: 28 Apr 2021

Published: 29 Jun 2021

* Corresponding author:

Department of Pediatric Dentistry, Dental School, Alborz University of Medical Sciences, Karaj, Iran

Email: leila.eftekhar.a@gmail.com

ABSTRACT

Pulmonary atresia with ventricular septal defect (PA/VSD) is one of the congenital heart diseases that results in cyanosis, susceptibility to bacterial endocarditis, and increased risk of complications during general anesthesia. Glucose-6-phosphate dehydrogenase (G6PD) deficiency is the most common inherited genetic disorder affecting the red blood cells. We aimed to elaborate the potential dental management for patients with this serious condition. This report presents the single-visit dental treatment of a three-year-old female with PA/VSD, G6PD deficiency and rampant caries. The complexity of dental treatments, high incidence of dental caries, lack of cooperation, and the systemic condition limit treatment options to providing service under general anesthesia and hospitalization. Careful monitoring of oxygen saturation during general anesthesia and antibiotic prophylaxis are essential due to the invasive nature of dental treatments. It appears that single-visit dental management under general anesthesia minimizes the risk of treatment of patients at high risk of bacterial endocarditis.

Keywords: Dentistry; Anesthesia, General; Glucosephosphate Dehydrogenase Deficiency; Heart Defects, Congenital

- **Cite this article as:** Ansari Gh, Mansouri M, Eftekhar L. Dental Management of a Case of Pulmonary Atresia and Ventricular Septal Defect. *Front Dent.* 2021;18:21.

INTRODUCTION

Congenital heart disease (CHD) includes a wide range of pathological cardiac conditions involving the structure and function of the heart and/or even the great vessels [1]. Pulmonary atresia along with ventricular septal defect (PA/VSD) is characterized by a biventricular heart problem with a large ventricular septal defect, a single-outlet aorta and absence of direct communication between the right ventricle and the pulmonary trunk which may be subvalvular or valvar [2,3]. The diagnosis is made during infancy with symptoms of cyanosis, failure to thrive, and dyspnea [3]. Compensatory right ventricle hypertrophy may be observed due to higher ventricular pressure produced in order to

maintain the blood flow to the lungs. The disease is manifested by cyanosis, polycythemia, systemic hypoxia, anemia, bluish appearance, and clubbing of the fingers [1]. Dental health is critically affected in patients with CHD. Such children have been reported to experience insignificantly higher rate of dental caries, periodontitis, and saliva lactobacilli colony count [4]. Delayed tooth eruption is seen as another oral manifestation beside stomatitis, glossitis, and cyanotic mucus membranes, tongue, and gingiva. Unattended dental caries with postponed treatment increases the rate of such problems which in turn may necessitate treatment under general anesthesia in patients with PA/VSD [5,6]. In addition, the risk of infective bacterial endocarditis should be taken

into consideration following such invasive dental procedures [1].

Patients with CHD are at increased risk of mortality and morbidity of anesthesia-related cardiac arrest during non-cardiac surgeries. Lifelong cyanosis is a common feature encountered in these patients at their routine controls with most of the organs being affected by chronic cyanosis. Cyanosis, polycythemia and coagulopathy are the main complications related to the anesthesia and surgery in these patients in addition to increased risk of hyperviscosity for children under the age of 5 years, leading to cerebral vein and sinus thrombosis [7]. Glucose-6-phosphate dehydrogenase (G6PD) deficiency is one of the most common inherited genetic enzymatic disorders of humans affecting the red blood cells [8]. G6PD is an enzyme promoting detoxification of free radicals and preventing cell damage [9]. Hemolysis of red blood cells can be induced by consumption of fava beans, certain drugs, infection, and certain metabolic conditions including diabetic ketoacidosis. Infection is probably the most common factor causing hemolysis in G6PD-deficient patients [8]. Inadequate management of patients with acute hemolytic anemia can lead to permanent neurological damage or even death [8].

It is necessary to consider that some uncontrolled oral infectious processes and some drugs may induce hemolysis [10], especially local anesthesia, non-steroidal anti-inflammatory drugs, and antibiotics commonly used by dentists. Local anesthetic agents have been reported to induce methemoglobinemia in G6PD-deficient individuals. These include prilocaine, articaine, lidocaine, and topical anesthetics such as benzocaine. Dental treatment may be challenging in patients with G6PD deficiency due to the risk of occurrence of acute hemolytic anemia caused by oxidative stress [11]. It has been indicated that although isoflurane, sevoflurane, diazepam, and midazolam have an inhibitory effect on G6PD activity, halothane, ketamine, and prilocaine have no such effect. Benzodiazepines, on the other hand, do not cause hemolytic crisis in the G6PD-deficient patients similar to

codeine/codeine derivatives, propofol, fentanyl, and ketamine. General anesthesia typically masks the immediate signs of hemolysis, making it difficult to identify the crisis; thus, the patient should be closely monitored intraoperatively [12]. The aim of this study was to present advanced single-visit dental treatment of a pediatric patient with PA/VSD and G6PD deficiency under general anesthesia.

CASE REPORT

A 3.5-year-old female patient was admitted to the Dental Clinic of Mofid Children's Hospital, Tehran with a chief complaint of dental pain for evaluation and treatment. She had been earlier diagnosed with PA/VSD (Fig. 1).

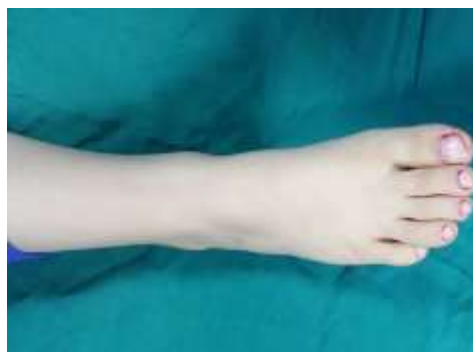

Fig. 1. Clubbing of the fingers due to pulmonary atresia along with ventricular septal defect

She also was proven to have G6PD deficiency at birth. The patient reportedly had a right-to-left shunt surgery. On examination, she was cyanotic with oxygen saturation level of 78-85%. As the patient was completely uncooperative, it was decided to perform all her dental treatments under general anesthesia to decrease the risk of multiple exposures to the treatment environment and potential complications in a chair-side setting. The parents were informed about the method, process and probable side effects before the general anesthesia, and signed an informed consent form. Preoperative physical examinations, blood tests, and full medical consultations were performed in order to ensure safety of the patient while receiving treatment under general anesthesia.

Taking the potential risks into account, treatment under general anesthesia was considered. The standard 8-hour preoperative fasting was instructed to the parents. Prophylactic antibiotic (ampicillin 50mg/kg) was administered 30 minutes before anesthesia, as instructed by a pediatric cardiologist. Maximum monitoring was conducted using the general anesthetic machine, pulse oximeter, capnograph, electrocardiogram, and blood pressure cuff. Anesthesia was induced by sevoflurane application and O₂ inhalation. Succinylcholine (1 to 1.5mg/kg) and atracurium (0.4 to 0.6mg/kg) were also administered per protocol as muscle relaxant and the spiral endotracheal tube (4mm gauge) was inserted. Desflurane and O₂ inhalation were used for maintenance of anesthesia after the initial dose of sevoflurane. These were followed by thiopental (5 to 6 mg/kg), fentanyl (0.5-2mcg/kg) and atropine (0.02mg/kg) intravenously.

Vital signs including the respiratory rate were measured during dental treatment with the O₂ saturation level at 78-85%. The procedure lasted for 135 minutes while the overall anesthesia lasted for 160 minutes. The patient received a range of dental procedures with vital pulpotomy being conducted on vital asymptomatic teeth. Restorative treatments with amalgam, stainless steel crown and composite resin were also performed as described in detail below and shown in Figures 2 and 3:

- 1- Pulpotomy and stainless steel crown: primary right mandibular second molar,
- 2- Pulpectomy of both maxillary and mandibular canines, filling them with calcium hydroxide paste (Metapex; Meta Biomed Co. Ltd., South Korea) followed by crown restoration with composite resin, and
- 3- Extraction of all 4 maxillary primary molars, all 8 maxillary and mandibular primary incisors, both mandibular first primary molars and left mandibular second primary molar.

The patient was then transferred to the intensive care unit, and monitored for 24h after the procedure.

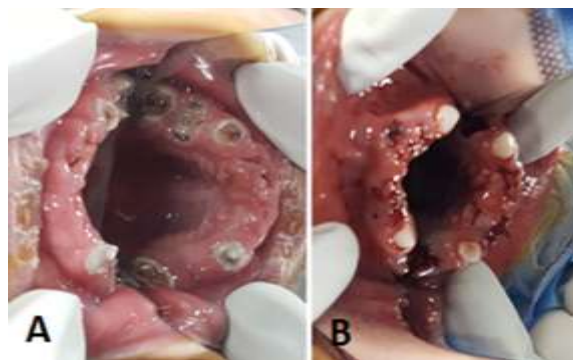


Fig. 2. (A) Pretreatment and (B) post-treatment intraoral view of the maxillary arch

She was then discharged since she had no problem or complication following the general anesthesia and dental treatments.

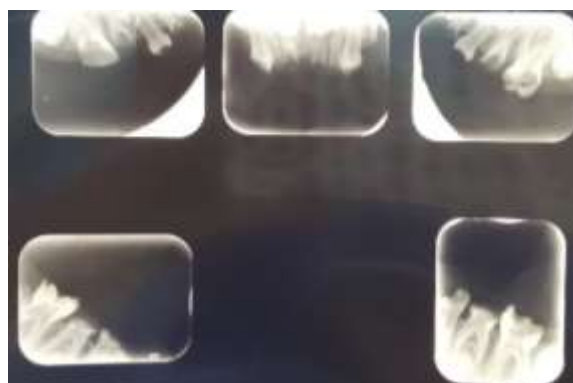


Fig. 3. Pretreatment periapical radiograph of the anterior and posterior teeth

DISCUSSION

General anesthesia is considered as an advantageous alternative to routine chair-side dental treatment for patients with anxiety, young age, and those with medical conditions. A thorough preoperative medical assessment is essential, and the parents should be informed about the advantages and disadvantages as well as the potential risks of the procedure. CHD is characterized by the structural and functional problems of the heart with an incidence of 8-10/1000 live births worldwide. The more common subgroups include ventricular septal defect, patent ductus arteriosus, transposition of the great arteries, and PA. Various factors should be noted while planning to treat children with CHD and PA/VSD.

These factors include dental caries, bacterial endocarditis, and patient cooperation. Higher incidence of dental caries has been reported in patients with such conditions [13], which in turn leads to complicated dental treatments requiring general anesthesia [5]. As higher salivary *Streptococcus mutans* [14] and lactobacilli colony counts [4] have been noted in most medically compromised patients, and due to the long-term use of sucrose-sweetened drugs [15], xerostomia induced by diuretic drugs, poor oral hygiene, and feeding difficulties, these patients may need single-visit full-mouth dental treatment. To prevent bacteremia and infective endocarditis, prophylactic antibiotic use should be considered prior to all invasive dental procedures [16]. To prevent cyanotic events, dental procedures should be performed under stress-free conditions if planned for outpatient care [15]. Several problems are thought to be potentially associated with CHD under general anesthesia including chronic hypoxemia, risk of brain abscess, pulmonary hypertension, and bacterial endocarditis [17]. The incidence of G6PD deficiency as an inheritable genetic disorder highly depends on the geographical region and ethnic group with a prevalence rate of 6.7% among Iranians [18]. Certain conditions may trigger hemolysis in these patients which include oral infections, some commonly prescribed drugs, and some general anesthesia agents. Further complications include severe anemia, acute renal failure, and malignant hyperthermia [10]. Patients with G6PD deficiency may receive inhalation sedation safely while hospitalization should be considered for general anesthesia administration [19] and maintenance of close postoperative follow-ups. The management protocol for patients suffering from G6PD deficiency is avoidance of any oxidative stressor and appropriate use of certain safe drugs [10].

CONCLUSION

Full-mouth dental rehabilitation of the current patient with PA/VSD and G6PD deficiency was carried out under general anesthesia safely and efficiently. Full-scale monitoring is

necessary to prevent hypoxia as well as bacterial endocarditis. The dental treatment plan may be altered in favor of more reliable treatment options in order to minimize the future risks of infection and complications.

ACKNOWLEDGMENTS

The authors would like to express their acknowledgment to the patient and her parents for helping to provide this report.

CONFLICT OF INTEREST STATEMENT

None declared.

REFERENCES

1. Garrocho-Rangel A E-GA, Rosales-Bérber MÁ, Flores-Velázquez J, Pozos-Guillén A. Dental management of pediatric patients affected by pulmonary atresia with ventricular septal defect: A scoping review. *Med Oral Patol Oral Cir Bucal*. 2017 Jul;22(4):e458.
2. Freedom RM, Benson LN, Smallhorn JF. Pulmonary atresia and ventricular septal defect, in Neonatal heart disease. London, Springer, 1992:229-56.
3. Gatzoulis MA, Swan L, Therrien J, Pantely G. Pulmonary atresia with ventricular septal defect, in adult congenital heart disease: A practical guide. Blackwell Publishing Ltd., 2005:132-138.
4. Pourmoghaddas Z, Meskin M, Sabri M, Tehrani MH, Najafi T. Dental caries and gingival evaluation in children with congenital heart disease. *Int J Prev Med*. 2018 Jun;9(1):52.
5. Cantekin K CI, Torun Y. Comprehensive dental evaluation of children with congenital or acquired heart disease. *Cardiol Young*. 2013 Oct;23(5):705-10.
6. Pimentel EL, AzevedoV, Castro RD, Reis LC, Lorenzo AD. Caries experience in young children with congenital heart disease in a developing country. *Braz Oral Res*. 2013 Mar-Apr;27(2):103-8.
7. White MC, Peyton J. Anaesthetic management of children with congenital heart disease for non-cardiac surgery. *Continuing Education in Anaesthesia, Critical Care & Pain*. 2011 Dec 12(1):17-22.
8. Elyassi CA, Rowshan M. Perioperative management of the glucose-6-phosphate dehydrogenase deficient patient: a review of literature. *Anesth Prog*. 2009 Autumn;56(3):86-91.
9. Monteiro WM, Val FF, Siqueira AM, Franca GP, Sampaio VS, Melo GC, et al. G6PD deficiency in Latin America: systematic review on prevalence

and variants. *Mem Inst Oswaldo Cruz*. 2014 Aug;109(5):553-68.

10. Hernández-Pérez D, Téllez Girón C, Ruiz-Rodríguez S, Garrocho-Rangel A, Pozos-Guillén A. Dental considerations in children with glucose-6-phosphate dehydrogenase deficiency (Favism): A review of the literature and case report. *Case Rep Dent*. 2015 Sep(9):459-506.

11. Kumar RA, Venkatesh B, Karumaran CS, Rajasekaran MS, Shankar P. Protocol for dental management in a patient with glucose-6-phosphate dehydrogenase deficiency. *J Clin Diagn Res*. 2017 Oct;11(10):ZD09-11.

12. Altikat S ÇM, Buyukokuroglu ME. In vitro effects of some anesthetic drugs on enzymatic activity of human red blood cell glucose 6-phosphate dehydrogenase. *Pol J Pharmacol*. 2002 Jan-Feb;54(1):67-72.

13. Stecksén-Blicks C, Rydberg A, Nyman L, Asplund S, Svanberg C. Dental caries experience in children with congenital heart disease: a case-control study. *Int J Paediatr Dent*. 2004 Mar;14(2):94-100.

14. Ajami B, Abolfathi G, Mahmoudi E,

Mohammadzadeh Z. Evaluation of salivary *Streptococcus mutans* and dental caries in children with heart diseases. *J Dent Res Dent Clin Dent Prospects* 2015 Jun;9(2): 105-8.

15. Ayala C, Aguayo L. Oral and systemic manifestations, and dental management of a pediatric patient with Tetralogy of Fallot. A case report. *J Oral Res*. 2016 Mar;5(2):87-91.

16. Pertiwi AS, Sasmita I, Nonong YH. Oral and dental management in children with tetralogy of fallot. *Dental Journal (Majalah Kedokteran Gigi)*. 2007 Mar;40(1):42-5.

17. Hasan MS, Chan L. Dexmedetomidine and ketamine sedation for dental extraction in children with cyanotic heart disease. *J Oral Maxillofac Surg*. 2014 Oct;72(10):1920. e1-4.

18. Moosazadeh M, Amiresmaili M, Aliramezany M. Prevalence of G6PD deficiency in Iran, a meta-analysis. *Acta Med Iranica*. 2014;52(4):256-64.

19. Greenwood M. Meechan J. General medicine and surgery for dental practitioners. Part 2—metabolic disorders. *Br Dent J*. 2010 May;208(9):389-92.