

Simple Method for Converting Conventional Face-bow to Postural Face-bow for Recording the Relationship of Maxilla Relative to the Temporomandibular Joint

Ali Gooya¹, Houman Zarakani², Yeganeh Memari³✉

¹Assistant Professor, Department of Prosthodontics, University of Gorgan, School of Dentistry, Gorgan, Iran

²Instructor, Department of Prosthodontics, University of Shahid Beheshti, School of Dentistry, Tehran, Iran

³Assistant Professor, Department of Prosthodontics, University of Shahid Beheshti, School of Dentistry, Tehran, Iran

Abstract

A fundamental assumption in prosthetic dentistry is that the axis-orbital plane will usually be parallel to the horizontal reference plane. Most articulator systems have incorporated this concept into their designs and use orbitale as the anterior reference point for transferring the vertical position of the maxilla to the articulator. Clinical observations of Cantonese patients suggest that in some individuals the Frankfort plane may not be horizontal, thus the orientation of the casts in the articulator is incorrect with respect to the horizontal plane. The purpose of this study was to introduce a simple method for converting the conventional face-bow to postural face-bow to reproduce the orientation of the occlusal plane relative to the true horizontal plane with the patient in Natural Head Posture (NHP).

Keywords: Face-bow; Maxilla; Temporomandibular joint

✉ Corresponding author:
Y. Memari, Department of Prosthodontics, University of Shahid Beheshti, School of Dentistry, Tehran, Iran

y_memari@yahoo.com

Received: 28 August 2014
Accepted: 2 December 2014

Journal of Dentistry, Tehran University of Medical Sciences, Tehran, Iran (2015; Vol. 12, No. 1)

INTRODUCTION

The maxilla - mandible relationship is not the same in all patients; the anatomy of maxilla and temporomandibular joint (TMJ) vary from person to person. A face-bow device is used to register the 3-dimensional relationship of the maxillary dental arch to the Frankfort horizontal plane (FHP) or hinge axis-orbital plane using either the patient's external meatus or the condylar heads (depending on the requirements of the face-bow) as the posterior reference [1]. Face-bows that incorporate earplugs have shown better overall performance [2]. One reference plane is the Frankfort plane also known as the FHP. This standard craniometric

plane passes the right and left porion and also the orbitale. Since the porion is a radiographic landmark not visible in living subjects, clinicians support using the axis-orbital plane as a new plane. This plane and the hard-tissue Frankfort plane roughly coincide called the hinge axis-orbital plane. In fact, the axis-orbital plane is 7° off from the Frankfort plane. Hinge axis-orbital plane is usually determined by marking three points on the patient's face.

Two points, one on each side of the face, are located on the hinge axis. The third point is located on the face at the level of the orbital rim beneath the eye [3].

Auxiliary components can be attached to the face-bow to aid in the anterior alignment using the nasion or infraorbitale [4]. This face-bow registration is transferred to the articulator to position and mount the maxillary cast. The mandibular cast is then mounted with an interocclusal registration.

Intracranial reference landmarks (i.e. nasion or infraorbitale) for maxillary cast alignment are convenient to use but may introduce uncontrolled variables in the transfer procedure. The relative position of anatomically defined landmarks is influenced by racial variation, gender differences, operator skills in the recognition of markers [5] and other factors. Previous arbitrary landmarks and measurements have been used based on average values of normative data and may be inappropriate for subjects of different ages and gender [6]. For instance, Ferrario et al. reported different Frankfort planes between the sexes. Males tended to have a plane inclining more upwards than females [7]. As the horizontal plane used for almost all semi adjustable articulators is the Frankfort plane or the orbital axis plane, the infraorbital notch will be used as the anterior reference point.

Recent researches showed that the position of the Frankfort plane is not horizontal in some Cantonese patients and thus, the orientation of the casts would be incorrect [2]. Other international studies have shown that both planes are not horizontal, and mounting a maxillary cast according to these planes can result in inaccurate mounting [8]. Failure to transfer the correct vertical relationship may result in esthetic compromise; in complete denture treatment, this error may produce an occlusal plane in which the maxillary posterior teeth are positioned below the incisal edges of the anterior teeth or vice versa [9]. Individual and racial differences in the classic intracranial reference planes can be eliminated using NHP and true horizontal plane together [10]. Also, some orientation errors which occur when maxillary

cast are mounted on the articulator may be eliminated [11, 12].

NHP is the upright position of the head of a standing or sitting subject [13, 14]. A number of studies have found NHP to be reasonably stable [15]. A recent investigation introduced a new, reliable computerized method for in vivo non-invasive determination of the 3-dimensional position of the occlusal plane with the head in NHP [16].

The purpose of this study is to introduce a simple method for converting conventional face-bow to postural face-bow designed to reproduce the spatial orientation of the occlusal plane relative to the true horizontal plane with the patient in NHP. Recording inclination of occlusal plane into the true horizontal plane and transfer of this relationship to the articulator is important to see the teeth in the true horizontal plane.

MATERIALS AND METHODS

Converting method:

To convert conventional face-bow (Dentatus face-bow, Sweden) to postural face-bow, we just need to replace the third component of the conventional face-bow (Orbital Pointer Pin) with true horizontal indicator pin (THIP). THIP is a single pin that is perpendicular to the two bubble style levels. THIP construction is as follows:

1. Two bubble style levels are placed perpendicular to each other when bubbles are placed in central position (two bubble style levels are placed on the true horizontal plane) and attached to each other. Two bubble style levels are used to find the true horizontal plane.
2. While two bubble style levels show true horizontal plane, a single pin is attached perpendicular to them (Figure 1). The best pin for fabricating THIP is the Orbital Pointer Pin of the face-bow.
3. The THIP is attached to the face-bow instead of the orbital pointer pin in the same place.



Fig 1. THIP is a single pin that is attached perpendicular to the two bubble style levels while they are in true horizontal position (bubbles placed in central position).

Hereby, the conventional face-bow is converted to the postural face-bow. In this device, the reference plane is the true horizontal plane. Thus, when bubbles are placed in the central position and the bubble style levels indicate the true horizontal plane, the single pin is placed perpendicular to the true horizon. For better performance, instead of the two perpendicular bubble style levels, one digital bubble style level can be attached to the single pin in the same manner.

Postural face-bow record and transfer:

1. An irreversible hydrocolloid impression of the maxillary dental arch is made for the subject and cast in dental stone.

2. The subject sits in a chair with the head in NHP. To obtain NHP, a 25 × 25-cm mirror is positioned at eye level at a distance of 1.5 m, and the subject is asked to look at the reflection of his pupils [16].

3. The face-bow fork, which was covered with putty (Elite HD, putty soft fast set, Zhermack, Italy) is positioned in the subject's mouth. Ear rods of the face-bow (Dentatus face-bow, Sweden) are used to locate the position of the external auditory meatus. The operator rotates the postural face-bow until the earplugs are centered over the external auditory meatus and then the assembly is centered and then the screws of the earpieces are closed.

4. While the subject is in NHP and the screw of the fork is closed, the THIP is adjusted to the true horizontal plane and then the screw is closed (Figures 2- 1, 2- 2 and 2- 3). Then, the earplugs are loosened and the postural face-bow is carefully removed.

5. The articulator (ARH Dentatus Articulator, Sweden) is placed on the horizontal plane and then earplugs are attached to the articulator in a centered position.

6. Then, the postural face-bow is rotated in earplug axis until the bubble style levels indicate the true horizontal plane and then fixed in this position. (Figures. 3- 1 and 3- 2).

7. The incisal pin and the incisal guidance table are set at zero; the condylar elements in the hinge position are locked and are attached via mounting ring to the upper part of the articulator.

The maxillary cast is seated in the postural face-bow fork record and then the maxillary cast is mounted in the articulator. Thus, the relationship between the inclination of the occlusal plane with the pin (that is perpendicular to the true horizontal plane) is transferred from patient to the articulator.

After mounting the casts on the articulator, the dental technician sees the same view of the dentition that the dentist sees in the clinic while the patient is in the NHP (Figures 4- 1 and 4- 2).

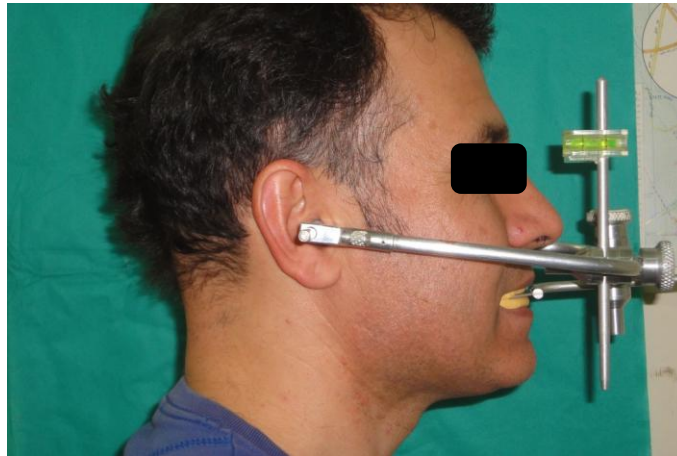

Fig 2- 1. The relationship of inclination of occlusal plane with perpendicular pin to the true horizontal plane is registered while the patient is in NHP.

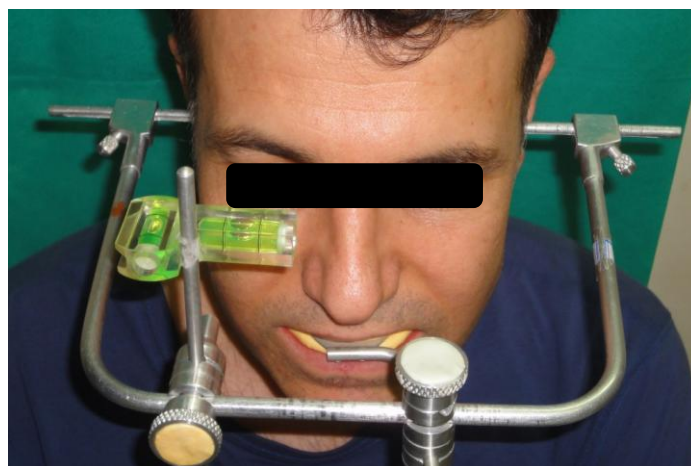


Fig. 2- 2. While the subject is in NHP, the screw of fork is closed, and then THIP is adjusted to the true horizontal plane.

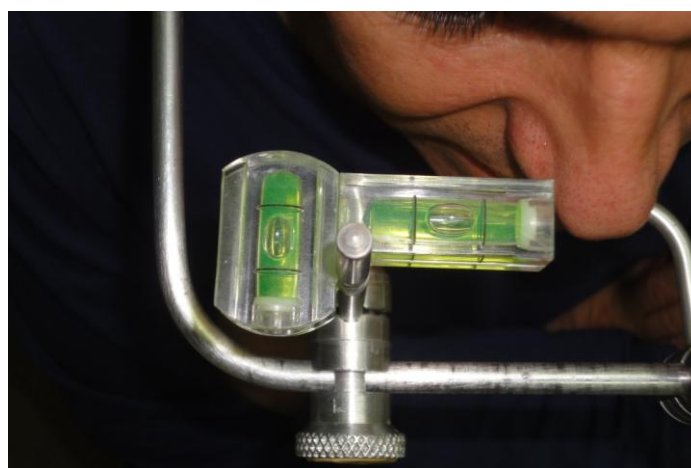

Fig.. 2- 3. THIP is adjusted to the true horizontal plane (bubble style levels placed in central position).

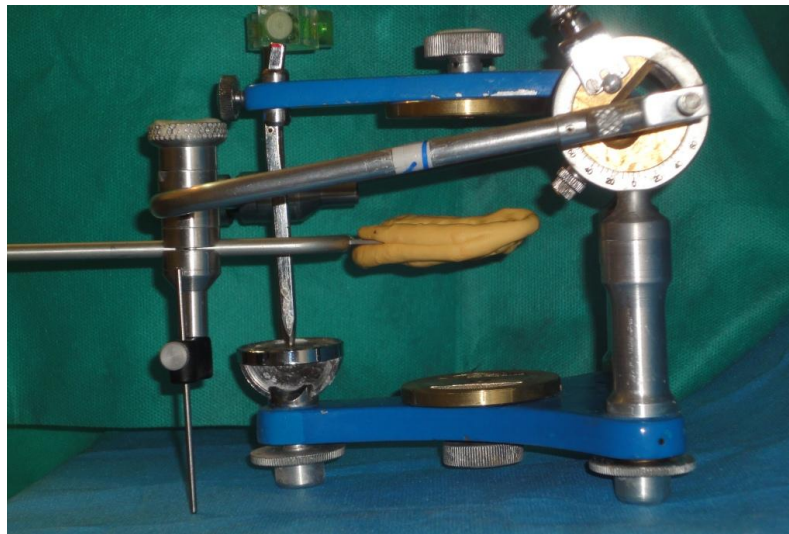


Fig 3- 1. Postural face-bow is rotated in earplug axis until the bubble style levels indicate the true horizontal plane.



Fig 3- 2. The bubble style levels indicate the true horizontal plane.

The postural face-bow is used to duplicate the orientation of the occlusal plane relative to the true horizontal plane while the patient is in NHP and this position is transferred to the articulator.

DISCUSSION

A combination of arbitrary and anthropometric landmarks is used in the common face-bow system, which identifies a plane related to the cranium.

Although there is considerable variation in the relationship between the outer cartilaginous margin and the bony margin of the external auditory meatus [17, 18], face-bows that incorporate earplugs have shown better overall performance. The earplug used as the posterior reference point in many face-bow systems is very convenient and seems acceptable except for patients with gross facial asymmetry [2]. Intracranial reference landmarks for maxillary cast alignment are convenient to use but may

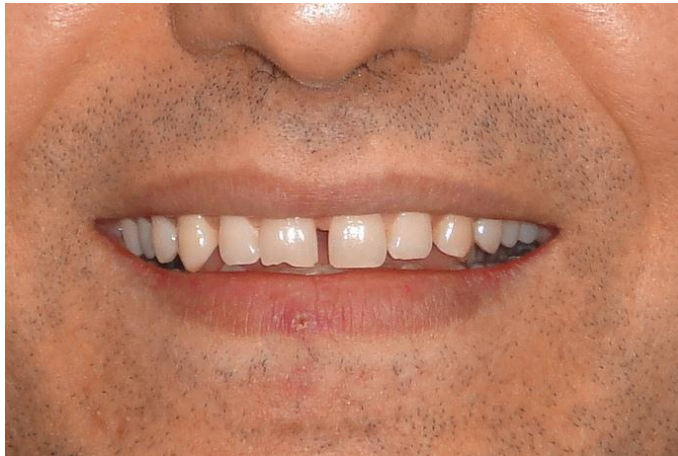

Fig 4- 1. Frontal view of the patient's smile in the clinic in the NHP.

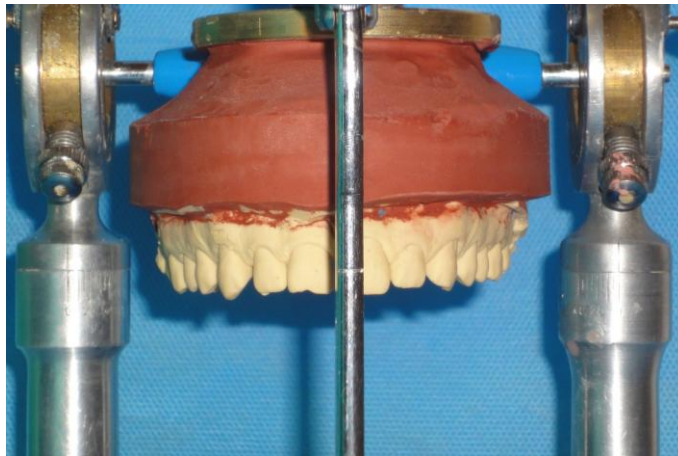


Fig 4- 2. Frontal view of the maxillary dental cast on the true horizontal plane.

introduce uncontrolled variables in the transfer procedure [8]. Landmarks are defined by their relative anatomical position, and racial and gender differences and operator skills can affect their position [5]. In addition, the arbitrary landmarks and measurements used are based on average values designated on the basis of normative data, which may be unsuitable for subjects with large differences in size or shape as a result of age, gender, or facial asymmetry [6]. Zizelmann et al. [19] evaluated the error magnitude in the clinical application of face-bow devices by using CT (computed tomography) database. They reported inaccuracy in the traditional use of face-bow devices.

Correct vertical dimension is important and failure in its transfer might be problematic and cause esthetic compromise and an occlusal plane in which the maxillary posterior teeth are positioned below the incisal edges of the anterior teeth or vice versa [9]. Wolford and Galiano [20] suggested mounting models via Occlusal Plane Indicator platform (OPI). OPI relies on the patient's clinical and cephalometric evaluations to mount the dental models on the articulator without the use of a face-bow. They claimed that transfer of the cephalometric measures to the articulator provides an actual relationship between the skull base, FHP, and maxillary occlusal plane.

On the other hand, Mayrink et al. [21] compared the inclination of maxillary occlusal plane in relation to FHP between the traditional method of mounting dental casts (with the use of traditional face-bow) and mounting models via OPI. The statistical analysis showed no significant difference between OPI and face bow. An advantage of this postural face-bow is that the common type of face-bows can be converted easily to this device; the third reference point component just needs to be replaced with THIP. Also, after mounting the casts on the articulator, the dental technician sees the same view of the dentition that the dentist sees in the clinic while the patient is in the NHP.

In other words, the technician will be able to see the teeth in the true relation into the true horizontal plane. Thus, laboratory errors, especially errors related to esthetics decrease. Another advantage of this postural face-bow is that it is easy to use. It is easy for beginners to put the bubble levels in the appropriate position and this position is transferred to the articulator with limited errors.

Virgilio et al, in 2002 introduced postural face-bow [6]. This postural face-bow is much easier to work with due to its simplicity; it can be installed quickly and easily on the patient's face. Also, it is easy to install on the articulator and mount. To achieve better cosmetic results, this postural face-bow can be easily used in daily practice. Converting conventional face-bow to postural face-bow requires very little cost. Performance is improved by replacing bubble style levels with one discoid or digital type.

CONCLUSION

Individual and racial differences described in the classic intracranial reference planes can be eliminated by using NHP and true horizontal plane. Also, some orientation errors which happen when maxillary casts are mounted on the articulator can be obviated. The conventional face-bow can be easily converted to

postural face-bow for reproducing the spatial orientation of the occlusal plane relative to the true horizontal plane with the patient in NHP to eliminate the described orientation errors that occur when the maxillary casts are mounted on the articulator.

REFERENCES

- 1- Gold BR, Setchell DJ. An investigation of the reproducibility of face-bow transfers. *J Oral Rehabil.* 1983 Nov;10(6):495-503.
- 2- Bamber MA, Firouzal R, Harris M, Linney A. A comparative study of two arbitrary face-bow transfer systems for orthognathic surgery planning. *Int J Oral Maxillofac Surg.* 1996 Oct;25(5):339-43.
- 3- Pitchford JH. A reevaluation of the axis-orbital plane and the use of orbitale in a face-bow transfer record. *J Prosthet Dent.* 1991 Sep;66(3):349-55.
- 4- Bailey JO Jr, Nowlin TP. Evaluation of the third point of reference for mounting maxillary casts on the Hanau articulator. *J Prosthet Dent.* 1984 Feb;51(2):199-201.
- 5- Chow TW, Clark RK, Cooke MS. Errors in mounting maxillary casts using face-bow records as a result of an anatomical variation. *J Dent.* 1985 Dec;13(4):277-82.
- 6- Ferrario VF, Sforza C, Serrao G, Schmitz JH. Three dimensional assessment of the reliability of a postural face-bow transfer. *J Prosthet Dent.* 2002 Feb;87(2):210-5.
- 7- Ferrario VF, Sforza C, Germanò D, Dalloca LL, Miani A Jr. Head posture and cephalometric analyses: an integrated photographic/radiographic technique. *Am J Orthod Dentofacial Orthop.* 1994 Sep;106(3):257-64.
- 8- Ercoli C, Graser GN, Tallents RH, Galindo D. Face-bow record without a third point of reference: theoretical considerations and an alternative technique. *J Prosthet Dent.* 1999 Aug;82(2):237-41.
- 9- Bowley JF, Bowman HC. Evaluation of variables associated with the transverse horizontal axis. *J Prosthet Dent.* 1992 Sep;68(3):537-41.

- 10- Ow RK, Djeng SK, Ho CK. The relationship of upper facial proportions and the plane of occlusion to anatomic reference planes. *J Prosthet Dent.* 1989 Jun;61(6):727-33.
- 11- Ellis E 3rd, Tharanon W, Gambrell K. Accuracy of face-bow transfer: Effect on surgical prediction and postsurgical result. *J Oral Maxillofac Surg.* 1992 Jun;50(6):562-7.
- 12- Dos Santos Júnior J, Nelson SJ, Nummikoski P. Geometric analysis of occlusal plane orientation using simulated ear-rod facebow transfer. *J Prosthodont.* 1996 Sep;5(3):172-81.
- 13- Solow B, Tallgren A. Natural head position in standing subjects. *Acta Odontol Scand.* 1971 Nov;29(5):591-607.
- 14- Lundström A, Lundström F, Le Bret L, Moorrees A. Natural head position and natural head orientation: basic considerations in cephalometric analysis and research. *Eur J Orthod.* 1995 Apr;17(2):111-20.
- 15- Siersbaek-Nielsen S, Solow B. Intra- and interexaminer variability in head posture recorded by dental auxiliaries. *Am J Orthod.* 1982 Jul;82(1):50-7.
- 16- Ferrario VF, Sforza C, Serrao G, Ciusa V. A direct in vivo measurement of the three-dimensional orientation of the occlusal plane and of the sagittal discrepancy of the jaws. *Clin Orthod Res.* 2000 Feb;3(1):15-22.
- 17- Ferrario VF, Sforza C, Anderbegani A, Poggio CE, Dalloca LL. Relative position of porion and tragus in orthodontic patients. *Clin Anat.* 1995;8(5):352-8.
- 18- Ashley-Montagu MF. Location of porion in the living. *Am J Phys Anthropol* 1939;25:281-95.
- 19- Zizelmann C, Hammer B, Gellrich NC, Schwestka-Polly R, Rana M, Buche P. An evaluation of face-bow transfer for the planning of orthognathic surgery. *J Oral Maxillofac Surg.* 2012 Aug;70(8):1944-50.
- 20- Wolford LM, Galiano A. A simple and accurate method for mounting models in orthognathic surgery. *J Oral Maxillofac Surg.* 2007 Jul;65(7):1406-9.
- 21- Mayrink G, Sawazaki R, Asprino L, de Moraes M, Fernandes Moreira RW. Comparative study between 2 methods of mounting models in semiadjustable articulator for orthognathic surgery. *J Oral Maxillofac Surg.* 2011 Nov;69(11):2879-82.