



Frequency and Severity of Second Molar External Root Resorption Due to the Adjacent Third Molar and Related Factors: A Cone-Beam Computed Tomography Study

Shirin Sakhdari¹, Sara Farahani², Ehsan Asnaashari³, Sahel Marjani^{1*}

1. Department of Oral & Maxillofacial Radiology, Islamic Azad University, Faculty of Dentistry, Tehran, Iran
2. Private Practice, Tehran, Iran
3. Department of Endodontics, Islamic Azad University, Faculty of Dentistry, Tehran, Iran

Article Info	ABSTRACT
<p>Article type: Original Article</p> <hr/> <p>Article History: Received: 22 Feb 2021 Accepted: 15 Aug 2021 Published: 15 Oct 2021</p> <hr/> <p>* Corresponding author: Department of Oral & Maxillofacial Radiology, Islamic Azad University, Faculty of Dentistry, Tehran, Iran Email: dr.marjani66@yahoo.com</p>	<p>Objective: This study sought to assess the frequency and severity of second molar external root resorption (ERR) due to the adjacent third molar and its correlation with the position of third molar and other related factors using cone-beam computed tomography (CBCT).</p> <p>Materials and Methods: This cross-sectional study evaluated 320 second molars and their adjacent impacted third molars on CBCT scans of patients over 16 years, retrieved from the archives of Azad University Radiology Department. Presence/absence of second molar ERR, its location and severity (if present), and position of adjacent third molar were determined on CBCT scans, and recorded in a checklist. Data were analyzed using a logistic regression model.</p> <p>Results: The frequency of second molar ERR was 33.4% in the mandible and 14% in the maxilla. The severity of ERR was significantly correlated with the involved jaw ($P=0.001$) but had no correlation with age, gender, or depth of impaction of adjacent third molar ($P>0.05$). The mesioangular and horizontal positions of impacted third molars had a significant correlation with the frequency of second molar ERR ($P<0.006$).</p> <p>Conclusion: According to the results of this study, ERR occurring in second molars adjacent to third molars is common, especially in the mandible. Mesially inclined third molars have a greater potential of being associated with ERR in second molars.</p> <p>Keywords: Cone-Beam Computed Tomography; Root Resorption; Molar, Third; Tooth, Impacted</p>
<p>➤ Cite this article as: Sakhdari Sh, Farahani S, Asnaashari E, Marjani S. Frequency and Severity of Second Molar External Root Resorption Due to the Adjacent Third Molar and Related Factors: A Cone-Beam Computed Tomography Study. <i>Front Dent.</i> 2021;18:36.</p>	

INTRODUCTION

Second molar external root resorption (ERR) adjacent to third molar is a common concern for dental clinicians [1]. ERR is a pathological process involving the external root surface with a progressive trend, that occurs as the result of presence of local inflammation or mechanical stress [1-4]. ERR in the second molars adjacent to impacted third molars has a prevalence of 4.3% to 49.43% [1-3]. Long-

term retention of impacted third molars can cause severe pathological complications [5]. Root resorption of permanent teeth was first described by Bates in 1856, and the reason was explained to be the traumatization of periodontal ligament [6]. Other etiologies of ERR include trauma, orthodontic tooth movement, pressure applied by the adjacent impacted tooth, and ectopic eruption of impacted tooth [1,3,4,7,8].

Early detection of second molar ERR is not easy in the clinical setting, unless the ERR causes pulpal or periapical inflammation [1,4,9,10]. Poor knowledge about the causes of ERR and the influential factors in this respect can compromise the normal function of the tooth and its vitality. It may necessitate root canal treatment or root amputation or even tooth extraction in severe cases [1,3,4].

Not long ago, conventional radiographic modalities such as periapical and panoramic radiography were the only available imaging modalities for detection of ERR. However, these modalities have drawbacks such as superimposition and overlapping of the adjacent structures, image distortion, and image magnification, which can compromise and complicate the correct detection of ERR [4,9-13]. Also, detection of ERR in the buccal or palatal root surfaces would be extremely difficult on 2D radiographic images [9,12].

Cone-beam computed tomography (CBCT) is an imaging modality that provides highly accurate 3D images of the structures. CBCT is ideal for detection of small changes such as ERR since it allows a comprehensive 3D assessment of 3D structures from different aspects and directions [4,14]. Evidence shows that CBCT has a higher diagnostic value than 2D radiographic modalities, and is highly effective for detection and diagnosis of complex pathologies such as ERR [12,15,16].

Previous studies on second molar ERR due to the adjacent impacted third molars had a small sample size and did not measure the depth of impaction of third molars or their relationship with second molar ERR [3].

Due to the information gap on the frequency and severity of second molar ERR adjacent to third molars, and the need for CBCT for its detection, this study sought to assess the frequency and severity of second molar ERR due to the adjacent third molar. The location of ERR and its relationship with the position of the adjacent third molar as well as its relationship with age, gender, and the involved jaw were also evaluated.

MATERIALS AND METHODS

This descriptive cross-sectional study evaluated patients presenting to the Radiology

Department of School of Dentistry, Islamic Azad University, Tehran Branch, from 2017 to 2018 who were eligible for study inclusion.

The sample size was calculated to be 320 teeth according to Wang et al, [1] assuming $\alpha=0.1$, $\beta=0.2$, and odds ratio of 1.5 using the logistic regression analysis.

CBCT scans of 320 teeth belonging to patients over 16 years of age were retrieved from the radiology archives. The CBCT scans had been requested for different treatment purposes not related to this study. The inclusion criteria were presence of impacted/semi impacted third molars and absence of cysts/tumors associated with the impacted third molars.

Exclusion criteria were presence of tumors or bone defects in other parts extending to the posterior jaws, impacted molars with shorter than two-thirds of the root length, second molars with extensive caries, extracted or impacted second molars, and low quality of CBCT scans. The CBCT scans were selected by convenience sampling. All CBCTs were taken by Rotograph Evo 3D (Villa, Italy) and Carestream 9300 (Kodak, France). All measurements were made using OnDemand software (Cybermed, Korea). The exposure settings were 80-90 kVp, 9-10 mA, and 8.5x8.5cm or 10x10cm field of view, and 0.180-0.185mm voxel size.

The sagittal, coronal and axial sections were reconstructed using OnDemand 3D software.

The following parameters were evaluated on CBCT scans:

- Presence/absence of second molar ERR adjacent to an impacted/semi impacted third molar
- The location of second molar ERR which was categorized into three categories of apical-, middle- and cervical-third
- The severity of second molar ERR which was categorized into the following four grades (Fig. 1):
 - No resorption: sound root surface or loss of cementum
 - Slight resorption: less than $\frac{1}{2}$ of dentin thickness is lost.
 - Moderate resorption: loss of $\frac{1}{2}$ or over $\frac{1}{2}$ of root dentin
 - Severe resorption: root resorption with pulp exposure [1-3].

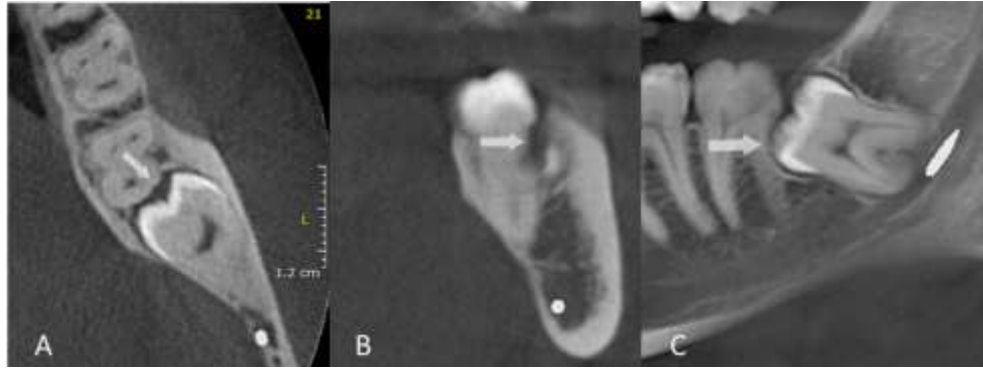


Fig. 1: Slight ERR of the mandibular second molar in the middle third on the axial (A), cross-sectional (B), and panoramic (C) reformatted views

Angulation of third molar on CBCT images was also categorized into the following five groups:

- (I) Vertical: the longitudinal axis of impacted third molar has 60-90° angle relative to the occlusal plane of the adjacent tooth
- (II) Horizontal: the longitudinal axis of impacted third molar has 0-30° angle relative to the occlusal plane of the adjacent tooth
- (III) Mesioangular: mesial deviation of longitudinal axis of impacted third molar with 31-60° angle relative to the occlusal plane of the adjacent tooth
- (IV) Distoangular: distal deviation of longitudinal axis of impacted third molar with 31-60° angle relative to the occlusal plane of the adjacent tooth
- (V) Transverse: buccolingual impaction when the crown and roots are superimposed.

Depth of third molar impaction was determined relative to the second molar and divided into three classes as follows:

Class A: The uppermost point of the impacted third molar is at the level or higher than the occlusal surface of the adjacent second molar.

Class B: The uppermost point of the impacted third molar is located between the occlusal surface and cemento-enamel junction of the adjacent second molar.

Class C: The uppermost point of the

impacted third molar is lower than the cemento-enamel junction of the second molar [1-3].

Data were collected in datasheets and analyzed using SPSS version 24 (SPSS Inc., IL, USA) at $P < 0.05$ level of significance. An ordinal regression model was used to investigate the effect of age, sex, impaction depth, and involved jaw on ERR severity. Comparison of ERR severity based on the impaction type (angulation) was done with the Kruskal-Wallis test, and pairwise comparisons were performed by the Dunn test.

RESULTS

A total of 320 CBCT scans of 190 females and 130 males with a mean age of 28.25 ± 7.66 years (range 16 to 62 years) were evaluated. The age and sex of patients, the involved jaw (maxilla/mandible), location of second molar ERR and its severity, and the angulation and depth of impaction of adjacent third molar were all measured and recorded. The correlation between the severity of second molar ERR and the study variables was also evaluated. The frequency of second molar ERR in the mandible was 33.4% ($n=66$); 7.16% were slight, 6.8% were moderate, and 1.8% were severe.

The frequency of second molar ERR in the maxilla was 14% ($n=17$); 6.6% were slight, 9.4% were moderate and 5.2% were severe. The overall frequency of second molar ERR was 47.4% ($n=83$).

Table 1. Frequency and severity of second molar ERR in the maxilla and mandible based on the location of ERR

Jaw	Location of resorption	None N(%)	Slight N(%)	Moderate N(%)	Severe N(%)	Total (100%)
Maxilla	Cervical	1 (11.1)	5 (55.6)	2 (22.2)	1 (11.1)	9
	Middle	0	2 (33.3)	3 (50.0)	1 (16.7)	6
	Apical	0	1 (33.3)	1 (33.3)	1 (33.3)	3
	Total	1(5.6)	8(44.4)	6(33.3)	3(16.7)	18
Mandible	Cervical	0	26 (52.0)	12 (24.0)	12 (24.0)	50
	Middle	1 (5.9)	7 (41.2)	5 (29.4)	4 (23.5)	17
	Total	1(1.5)	33(49.3)	17(25.4)	16(23.9)	67

The frequency and severity of second molar ERR in the maxilla and mandible of males and females were as follows: In males, the frequency was 23.5% (n=15) in the mandible and 7.5% (n=7) in the maxilla. In the mandible, most ERRs were slight (9.10%) while in the maxilla most ERRs were moderate (5.4%). In females, these values were 38.1% (n=51) in the mandible and 17.9% (n=10) in the maxilla. In the mandible, most ERRs were moderate (7.9%), and in the maxilla, most ERRs were slight (7.10%). In general, the frequency of second molar ERR was 31% in males (n=22) and 56% (n=61) in females. Table 1 presents the frequency and severity of second molar ERR in the maxilla and mandible based on the location of ERR.

The location of second molar ERR in the maxilla was in the cervical third in 47.05% (n=8), in the middle third in 35.29% (n=6), and in the apical third in 17.64% (n=3). The location of second

molar ERR in the mandible was in the cervical third in 75.75% (n=50) and in the middle third in 24.24% (n=16) of the cases.

Table 2 presents the severity of second molar ERR in the maxilla and mandible based on the position of impacted third molar. The frequency of second molar ERR in the maxilla was 64.7% (n=11), 5.88% (n=1), 11.76% (n=2), 17.64% (n=3) and 0.0% (n=0) in vertical, horizontal, mesioangular, distoangular and transverse positions of the adjacent impacted third molar, respectively.

The values in the mandible were 27.27% (n=18), 24.24% (n=16), 46.96% (n=31), 1.51% (n=1), and 0.0% (n=0) in vertical, horizontal, mesioangular, distoangular and transverse positions of the adjacent impacted third molar, respectively.

Table 3 shows the frequency of second molar ERR in the maxilla and mandible based on the depth of impaction of the adjacent third molar.

Table 2. Severity of second molar ERR in both jaws based on the position of impacted third molar

Jaw	Position	None N(%)	Slight N(%)	Moderate N(%)	Severe N(%)	Total (100%)
Maxilla	Vertical	72(86.7)	5(6)	5(6)	1(1.2)	83
	Horizontal	2(66.7)	0	1(33.3)	0	3
	Mesioangular	9(81.8)	2(18.2)	0	0	11
	Distoangular	16(84.2)	1(5.3)	0	2(10.5)	19
	Transverse	6(100)	0	0	0	6
	Total	105(86.1)	8(6.6)	6(4.9)	3(25)	122
Mandible	Vertical	69(79.3)	11(12.6)	2(2.3)	5(5.7)	87
	Horizontal	19(54.3)	8(22.9)	5(14.3)	3(8.6)	35
	Mesioangular	31(50)	13(21)	10(16.1)	8(12.9)	62
	Distoangular	9(90)	1(10)	0	0	10
	Transverse	4(100)	0	0	0	4
	Total	132(66.7)	33(16.7)	17(8.6)	16(8.1)	198

Table 3. Frequency of second molar ERR in both jaws based on the depth of impaction of third molar

Jaw	Depth of impaction	None N(%)	Slight N(%)	Moderate N(%)	Severe N(%)	Total (100%)
Maxilla	A	100(100)	0	0	0	10
	B	25(92.6)	1(3.7)	0	1(3.7)	27
	C	70(82.4)	7(8.2)	6(7.1)	2(2.4)	85
	Total	105(86.1)	8(6.6)	6(4.9)	3(2.5)	122
Mandible	A	11(50)	8(36.4)	2(9.1)	1(4.5)	22
	B	83(68)	15(12.3)	12(9.8)	12(9.8)	122
	C	38(70.4)	10(18.5)	3(5.6)	3(5.6)	54
	Total	132(66.7)	33(16.7)	17(8.6)	16(8.1)	198

The frequency of second molar ERR in the maxilla was 0% (n=0), 11.76% (n=2), and 88.23% (n=15) in class A, B and C impaction depth, respectively. These values were 16.66% (n=11), 59.09% (n=39), and 24.24% (n=16), respectively in the mandible.

The results showed that the severity of second molar ERR in the mandible was significantly higher than that in the maxilla (P=0.001). The severity of second molar ERR had no significant correlation with age (P=0.680). The frequency of second molar ERR in females was higher than that in males, but not significantly (P=0.089). The relationship of depth of impaction and ERR was not significant (P=0.696). The regression test showed that mesioangular and horizontal positions of impacted third molars had significant correlations with the occurrence of second molar ERR (P<0.006). No other significant correlations were noted (P=0.245).

DISCUSSION

This study assessed the frequency and severity of second molar ERR due to the adjacent third molar. The location of second molar ERR and its relationship with the position and depth of impaction of the adjacent third molar and some other influential factors such as age and gender of patients were also evaluated. The frequency of second molar ERR was 33.4% in the mandible and 14% in the maxilla. No correlation with age and gender of patients, or depth of impaction of third molar was seen. Our study showed that mesioangular and horizontal inclinations were at higher risk of being

associated with ERR than other impaction positions.

Oenning et al. [3] concluded that the diagnostic accuracy of CBCT was higher than panoramic radiography for detection of ERR, and its frequency in the mandible was higher than that in the maxilla. The frequency of ERR was 31% in the mandible and 14% in the maxilla in their study, which were close to the values in our study. Also, third molars with mesioangular and horizontal positions had higher odds of causing second molar ERR. Similarly, in our study, the severity of second molar ERR had significant correlations with the involved jaw (maxilla/mandible) and horizontal and mesioangular positions. The results of Oenning et al. [3] were close to ours, which confirms the accuracy and precision of our methodology. They had eligibility criteria similar to ours and evaluated impacted third molars in the maxilla and mandible. Movahhedian et al. [17] evaluated 500 mandibles and showed that ERR was the most common pathology caused by impacted third molars in the adjacent teeth with 31% frequency. In our study, the frequency of ERR was 33.4% in the mandible, which was close to their results. The frequency of ERR had a significant correlation with third molar position. By studying only the mandibular teeth, they found that mesially inclined teeth had a significant correlation with the occurrence of ERR in the adjacent tooth, which was in accordance with our results. Also, by an increase in impaction depth from class A to class C, risk of ERR increased. We found the same correlation although it was insignificant.

Oenning et al. [2] evaluated 174 teeth and found no significant correlation between ERR and gender of patients, type of CBCT system, position of third molar, and depth of impaction. Since they aimed to compare two CBCT systems, the frequency of ERR was not evaluated separately in each jaw but it had an overall frequency of 49.43%, which was close to our obtained value (47.4%). In our study, ERR had no significant correlation with gender or depth of impaction.

Li et al. [18] evaluated 184 CBCT scans of the maxilla and 323 CBCT scans of the mandible. They reported that the prevalence of ERR was 32.6% in the maxilla and 52.9% in the mandible. These rates were higher than the values in our study. They concluded that the frequency of ERR was significantly correlated with the depth of impaction and mesioangular position of third molars. Similarly, in our study, ERR had a significant correlation with the position of adjacent third molar. In their study, second molar ERR was more common in the mandible and in the cervical third, which was in agreement with our results. Tassoker [19] evaluated 200 CBCT scans of impacted third molars and reported the frequency of ERR to be 21%, which was lower than our obtained rate. He found that the prevalence of ERR in the mandible was 4 times higher than in the maxilla. Vertical and distoangular positions had a lower risk of causing ERR, and gender had no significant correlation with development of ERR; these findings were in accordance with our results. He concluded that aging increased the severity of ERR, which was inconsistent with our findings. The difference between the two studies in this regard may be related to the differences in the classification of severity of ERR. Tassoker [19] did not assess the depth of impaction in his study. Wang et al. [1] found that the frequency of ERR was 20.17%, which was lower than the value obtained in our study. However, they only assessed teeth with mesial and horizontal deviations. No significant correlation was noted between the severity of ERR with gender or location of ERR, which was in accordance with our results. They showed a significant correlation between ERR and age of

patients and depth of impaction of third molars. Similar to Tassoker [19], we believe that a cross-sectional study cannot provide full insight into age as a risk factor, because older people may have had their third molar teeth with ERR extracted beforehand in life. On the other hand, they evaluated only mandibular third molars and this also could be responsible for the difference in the results of the two studies in this regard. Future studies with larger sample size on different populations and racial groups are required to obtain more accurate results.

CONCLUSION

According to the results of this study, ERR occurring in second molars adjacent to third molars is common, especially in the mandible. Mesially inclined third molars have a greater potential of being associated with ERR in second molars.

CONFLICT OF INTEREST STATEMENT

None declared.

REFERENCES

1. Wang D, He X, Wang Y, Li Z, Zhu Y, Sun C, et al. External root resorption of the second molar associated with mesially and horizontally impacted mandibular third molar: evidence from cone beam computed tomography. *Clin Oral Investig*. 2017 May;21(4):1335-42.
2. Oenning AC, Melo SL, Groppo FC, Haiter-Neto F. Mesial inclination of impacted third molars and its propensity to stimulate external root resorption in second molars--a cone-beam computed tomographic evaluation. *J Oral Maxillofac Surg*. 2015 Mar;73(3):379-86.
3. Oenning AC, Neves FS, Alencar PN, Prado RF, Groppo FC, Haiter-Neto F. External root resorption of the second molar associated with third molar impaction: comparison of panoramic radiography and cone beam computed tomography. *J Oral Maxillofac Surg*. 2014 Aug;72(8):1444-55.
4. Creanga AG, Geha H, Sankar V, Teixeira FB, McMahan CA, Noujeim M. Accuracy of digital periapical radiography and cone-beam computed tomography in detecting external root resorption. *Imaging Sci Dent*. 2015 Sep;45(3):153-8.
5. Sandhya R, Dharman S. Radiographic findings associated with impacted third molars. *Int J Multidiscip Res Dev*. 2016;3(03):1334-8.

6. Massler M, Malone AJ. Root resorption in human permanent teeth: a roentgenographic study. *Am J Orthod*. 1954 Aug;40(8):619-33.
7. Ericson S, Bjerklin K, Falahat B. Does the canine dental follicle cause resorption of permanent incisor roots? A computed tomographic study of erupting maxillary canines. *Angle Orthod*. 2002 Apr;72(2):95-104.
8. Yamaoka M, Furusawa K, Ikeda M, Hasegawa T. Root resorption of mandibular second molar teeth associated with the presence of the third molars. *Aust Dent J*. 1999 Jun;44(2):112-6.
9. Dogramaci EJ, Sherriff M, Rossi-Fedele G, McDonald F. Location and severity of root resorption related to impacted maxillary canines: a cone beam computed tomography (CBCT) evaluation. *Aust Orthod J*. 2015 May; 31(1):49-58.
10. Alqerban A, Jacobs R, Fieuws S, Willems G. Comparison of two cone beam computed tomographic systems versus panoramic imaging for localization of impacted maxillary canines and detection of root resorption. *Eur J Orthod*. 2011 Feb;33(1):93-102.
11. Sarıkcı Ç, Alkurt MT, Değerli Ş, Altunkaynak B, Peker İ. Comparison of panoramic radiography and cone-beam computed tomography for qualitative and quantitative measurements regarding localization of permanent impacted maxillary canines. *Acta Odontol. Turc*. 2017; 34(1):1-7.
12. Walker L, Enciso R, Mah J. Three-dimensional localization of maxillary canines with cone-beam computed tomography. *Am J Orthod Dentofacial Orthop*. 2005 Oct;128(4):418-23.
13. Almuhtaseb E, Mao J, Mahony D, Bader R, Zhang ZX. Three-dimensional localization of impacted canines and root resorption assessment using cone beam computed tomography. *J Huazhong Univ Sci Technolog Med Sci*. 2014 Jun;34(3):425-30.
14. Dudic A, Giannopoulou C, Leuzinger M, Kiliaridis S. Detection of apical root resorption after orthodontic treatment by using panoramic radiography and cone-beam computed tomography of super-high resolution. *Am J Orthod Dentofacial Orthop*. 2009 Apr;135(4):434-7.
15. Strobel S, Lenhart E, Woelber JP, Fleiner J, Hannig C, Wrbas KT. Comparison of two cone-beam computed tomography systems in the visualization of endodontic structures. *Swiss Dent J*. 2017 Oct;127(3):221-9.
16. Kang F, Huang C, Sah MK, Jiang B. Effect of eruption status of the mandibular third molar on distal caries in the adjacent second molar. *J Oral Maxillofac Surg*. 2016 Apr;74(4):684-92.
17. Movahhedian N, Shahidi S, Jozari S, Mosharaf A, Naderi A. Impacted mandibular third molar, associated pathoses, and their relation to angulation and impaction depth: a cone beam CT study. *J Dent Biomater*. 2018 Mar;5(1):520-7.
18. Li D, Tao Y, Cui M, Zhang W, Zhang X, Hu X. External root resorption in maxillary and mandibular second molars associated with impacted third molars: a cone-beam computed tomographic study. *Clin Oral Investig*. 2019 Dec;23(12):4195-203.
19. Tassoker M. What are the risk factors for external root resorption of second molars associated with impacted third molars? A cone-beam computed tomography study. *J Oral Maxillofac Surg*. 2019 Jan;77(1):11-7.