



Amaurosis after Inferior Alveolar Nerve Block Injection in a Seven-Year-Old Girl: A Case Report and Review of the Literature

Arman Amirkhani¹, Hamid Mosleh^{2*}

1. Hamedan Eye Research Center, Department of Ophthalmology, Hamedan University of Medical Sciences, Hamedan, Iran
 2. Department of Pediatric Dentistry, Dental School, Shahrekord University of Medical Sciences, Shahrekord, Iran

Article Info	ABSTRACT
<p>Article type: Case Report</p> <hr/> <p>Article History: Received: 06 Oct 2023 Accepted: 12 Apr 2024 Published: 17 Oct 2024</p> <hr/> <p>* Corresponding author: Department of Pediatric Dentistry, Dental School, Shahrekord University of Medical Sciences, Shahrekord, Iran</p> <p>Email: mosleh@dnt.mui.ac.ir</p>	<p>A seven-year-old girl was referred for the treatment of her primary teeth. An inferior alveolar nerve block was administered using 1 mL of 2% lidocaine. Shortly after the injection, the patient experienced pain, erythema, blurred vision, and temporary loss of vision in her right eye. Based on these symptoms, a diagnosis of transient vision loss due to the anesthetic injection was made. The situation was explained to the child and her parents, assuring them that the complication was temporary. The right eye was covered with wet gauze, and all symptoms resolved within 20 minutes. A follow-up ophthalmological examination showed no abnormalities, and the procedure was successfully completed without further complications. A one-day follow-up revealed no issues.</p> <p>Keywords: Amaurosis; Blindness; Case Report; Local Anesthesia; Vision Disorders</p>

➤ **Cite this article as:** Amirkhani A, Mosleh H. Amaurosis after Inferior Alveolar Nerve Block Injection in a Seven-Year-Old Girl: a Case Report and Review of Literature. *Front Dent.* 2024;21:40.

INTRODUCTION

The use of local anesthetics is the most common method for behavior control and pain reduction during dental treatments. Among the local anesthetic injection techniques, inferior alveolar nerve block (IANB) is the most frequently used method for mandibular local anesthetic injection [1]. Although IANB is a safe and efficient administration technique, it is sometimes accompanied by complications such as allergy, hematoma, injection pain, burning sensation of the injection site, trismus, syncope, vasoconstriction, infection, edema, paresthesia, needle fracture, and facial nerve paralysis (cranial nerve VII) [1,2]. Ocular complications such as amaurosis (temporary blindness), mydriasis (pupillary dilation), miosis (constriction of the pupil), abnormal pupillary light reflex, enophthalmos

(recession of the eyeball within the orbit), diplopia (dual vision), blurred vision, and ophthalmoplegia (paralysis of muscle responsible for eye movement) have been occasionally reported following local anesthetic injections. Mandibular IANB is considered as having the highest risk, followed by maxillary posterior superior alveolar (PSA) nerve block [1-3].

Although such complications are typically rare and arise unexpectedly, their occurrence can be alarming for both dentists and patients. While no reports have documented these complications in children, the unpredictability of their movements during procedures increases the risk. Pediatric dentists should, therefore, remain vigilant and consider these potential complications during treatment. Pedodontists should also be well-versed in the

appropriate management of these complications to ensure prompt and effective care when such events arise.

CASE REPORT

A seven-year-old girl referred to the specialized dental clinic of School of Dentistry, Isfahan University of Medical Sciences. A study of the medical history showed the child had no history of food and drug allergies or drug consumption. The child complained of pain in mandibular right primary molars during mastication. Clinical examinations indicated caries in the mandibular right second primary molars. Based on the patient's complaints and clinical and radiographic examinations, reversible pulpitis was diagnosed. Moreover, the patient had undergone mandibular left pulpotomy and stainless steel crown (SSC) restoration. Indirect pulp capping with flowable resin-modified glass ionomer and SSC treatments were considered for the patient. After application of 2% local benzocaine anesthetic gel (Topex, Sultan, NJ, USA) on the dry mucosa for 2 minutes, a 27-gauge needle with a length of 25mm (Septoject: Septodont, Saint-Maur-des-fosses Cedex, France) and 2% lidocaine with 1/80000 epinephrine (Lignospan; Septodont, Saint Maur des Fosses, France) were used after aspiration for IANB at the occlusal plane level. The needle penetration rate was about 16mm, and 1ml of the anesthetic solution was injected for 1 minute.

The patient complained of pain in the right eye for 2 minutes. Analysis of the eyes showed erythema in the right eye, and the patient immediately reported blurred vision and inability to see with the right eye. No change was seen in the patient's consciousness, and her pupils had a normal size. The right eye response was evaluated after the patient closed her left eye, indicating no light reflex.

The eye movements were assessed by asking the patient to change the position of her eyes. These movements were normal in both sides, which showed rejection of oculomotor (cranial nerve III), trochlear (cranial nerve IV), and abducens (cranial nerve VI) damage.

No change was observed in the conditions of

the eyelids, and the patient had no complaints except for pain in the eye and inability to see with the right eye. The left eye had normal vision. The movement of facial muscles was evaluated by asking the child to change her facial expressions. Facial muscle movements were completely normal at both sides. The facial nerve (cranial nerve VII) had normal performance. Based on the patient's symptoms, she was diagnosed to have undergone loss of vision due to injection.

The child and her parents were reassured that the complication was temporary and she would gain her normal vision soon. The right eye was covered with wet gauze and all symptoms disappeared after 20 minutes. The patient was referred to an ophthalmologist for further evaluation, a follow-up dental treatment session was scheduled.

Ophthalmological examinations showed no abnormal results, and the patient had normal vision. The patient's follow-up was done by telephone, and her parents reported no abnormalities in the 24-hour and 48-hour follow-ups. The next treatment session was arranged with a one-week interval. In the next session, infiltration and intra-papillary (periodontal ligament) injection with 0.5ml 2% lidocaine and 1/80000 epinephrine were done. After removal of caries, flowable resin-modified glass ionomer (Ionoseal, VOCO, Cuxhaven Germany) was applied to the cavity (indirect pulp cap) and a stainless steel crown (3M, St. Paul, MN, USA) was cemented on the tooth using luting glass ionomer cement (GC Fuji I, Asia Dental Pte Ltd, Singapore).

DISCUSSION

The local anesthetic injection is a common method for pain control in dentistry. Among the local anesthetic injection techniques, IANB is the most frequently used method. It has advantages over other mandibular injections, including reduced visual exposure of syringe, which is especially important in children, and a reduced need for frequent injections since all alveolar, mental, and lingual branches on the injection side are blocked by one injection [4]. However, this injection is followed by complications such as hematoma, trismus,

infection, paresthesia, needle fracture, and complications caused by lip and cheek biting in children due to prolonged soft tissue anesthesia. Ocular complications occur rarely following this injection, which is about 1/1000 [5]. Among the ocular complications, diplopia, ptosis, mydriasis, and amaurosis have the highest prevalence [3,6]. Temporary loss of vision is observed in 20% of cases [7].

Although ocular complications have unknown incidence, it seems that the reasons for ocular complications are different between mandibular and maxillary local aesthetic injections. There is a consensus that local anesthetic injections may affect ocular nerve function and cause ocular complications through one of the vascular, neural, and lymphatic pathways [3,8].

The most common theory about the incidence of blindness following IANB is intra-arterial inferior alveolar nerve block [3]. Since IANB is performed according to the anatomic landmarks, intravenous injection is possible due to anatomic variations of the injection site and position of inferior alveolar artery and vein with a wide diameter behind the inferior alveolar nerve.

When the anesthetic is wrongly injected into the inferior alveolar artery with pressure, it is retrograded into the internal maxillary artery and then the middle meningeal artery which is a branch of the maxillary artery [3,8](Figure 1).

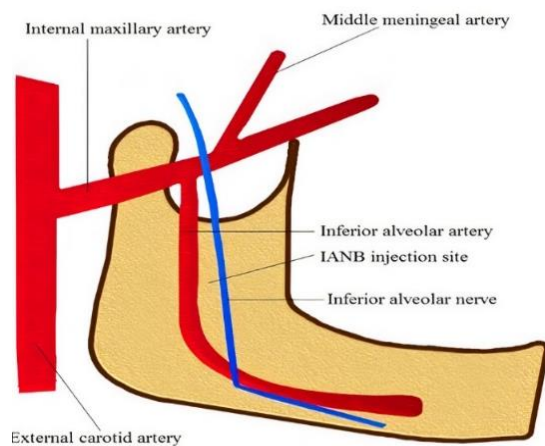


Fig 1. A schematic figure showing the proximity between the inferior alveolar nerve and artery and also the connection between the inferior alveolar and middle meningeal arteries

The middle meningeal artery enters the skull through the spinosum and is divided into various branches in the middle cranial fossa. In 4% of people, the ophthalmic artery is originated from the middle meningeal artery instead of the internal carotid artery [9]. This anatomic variation makes the anesthetic reach the ophthalmic artery and retinal artery afterward [8,9].

Vasospasm, which is caused by the anesthetic, leads to retinal vascular disorders depending on the duration and severity of the stenosis it induces [8,9]. The ophthalmic branch anastomosis of the middle meningeal and lacrimal arteries disrupts the feeding of the lateral rectus muscle and causes diplopia [3,8]. Cases with the rapid start of symptoms followed by neural symptoms such as headache, dizziness, and confusion, or cardiac symptoms such as palpitation and tachycardia should raise concern [8,9]. Hence, it is necessary to perform aspiration before injection and administer the injection slowly over one minute to prevent high-pressure injection and ocular complications subsequently. It is also recommended that 25-gauge or thicker needles (lower diameter needle, higher-pressure injection) be used in areas with possible incidence of aspiration to prevent high-pressure injection [10]. As for this patient, despite negative aspiration, the movements of the child or dentist during injection or the presence of anatomic variations may have led to inter-arterial injection and might have induced ocular complications.

The orbital branches of the middle meningeal artery form anastomoses with the lacrimal, retinal, and other branches of the ophthalmic artery, either through the superior orbital fissure or vascular canals in the greater wing of the sphenoid bone [3,5]. This pathway allows for the drug to reach the ophthalmic artery via the middle meningeal artery, potentially leading to blindness by affecting the retinal branch of the ophthalmic artery [3,8].

Another theory is intravenous inferior alveolar injection. It states that it is possible for the anesthetic drug to reach the cavernous sinus after an intravenous injection through the anterior facial vein and then inferior

orbital vein, or through pterygoid venous plexus [8] (Figure 2). The internal carotid artery, oculomotor, trochlear, and abducens nerves, and ophthalmic and maxillary branches of the trigeminal nerve (cranial nerve V) pass through the cavernous sinus. Delivery of the local anesthetic to the cavernous sinus causes numerous complications. If the drug blocks the cranial nerves III, IV, and VI, ophthalmoplegia occurs. Ptosis occurs if the cranial nerve III is blocked and mydriasis occurs if the parasympathetic nerves feeding the cranial nerve III are blocked [8]. The involvement of the ophthalmic branches of the trigeminal nerve also affects vision. Since cranial nerve VI (abducens) is located in the middle of the cavernous sinus, it is more likely to undergo diplopia than blindness [10].

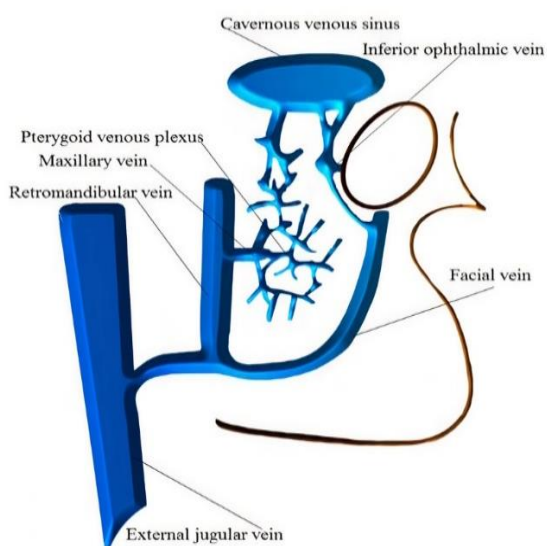


Fig 2. Schematic figure demonstrating the communication between the cavernous sinus, anterior facial vein and pterygoid venous plexus

Another theory attributes the anesthetic drug’s effects to its action on the stellate ganglion, where symptoms such as ptosis, miosis, conjunctival vasodilation, and hoarseness following IANB are due to sympathetic nerve block, characteristic of Horner syndrome [11]. Additionally, the anesthetic can induce mydriasis, accommodation disorder, and impaired pupillary light reflex [10,11]. Furthermore, needle trauma and vaso-constrictor effects, or direct damage to peri-arterial sympathetic nerves, may trigger a sympathetic neural response that travels toward the orbital region [11,12], causing transient blanching of peri-orbital skin and diffuse pain during the injection [13].

An alternative hypothesis is that myofascial spaces or bony openings have low resistance against the anesthetic diffusion from the regional nerves into the orbital area. For example, after the maxillary V2 block, the trigeminal nerve (cranial nerve V) may affect the ocular muscles and cause diplopia due to possible diffusion of anesthetic through the greater palatine canal and then through the inferior orbital fissure [10].

Variations in the incidence of symptoms can be associated with anatomic variations in different people. Such complications are usually followed by short-term effects, and complications completely disappear over a few minutes or a few hours [2-3] (Table 1). Permanent effects rarely occur and may happen due to reasons such as embolism and closure of the feeding vessels [12]. Necrosis and retinal ischemia due to retinal arterial vasospasm may also be linked to permanent blindness [14,15].

Table 1. Ocular complications of inferior alveolar nerve block in previous studies

Reference	Year	Age	Amaurosis	Diplopia	Mydriasis	Ptosis	Blurred vision	Time lasting
Williams et al. [14]	2010	25	✓	✓	✓	✓		5 min
Boynes et al. [13]	2010	27	✓					20 min
Verma et al. [16]	2013	25	✓				✓	2h, 30 min
		32	✓					3h
Barodiya et al. [2]	2017	30	✓				✓	30 min
Odabasi et al. [15]	2017	40	✓	✓				5 min
Pandey et al. [3]	2018	37	✓	✓			✓	30 min

No incidence of permanent blindness due to retinal arterial embolism has been reported, because of the oily nature of some anesthetic drugs such as procaine hydrochloride and fillers used in cosmetic cheek surgeries [16]. According to previous studies, the mechanisms leading to ocular complications are still unknown, but ocular complications during tooth injection are very rare and patients and their parents should be sure that these complications usually do not have long-term effects. If complications do not disappear within a few hours, it is necessary to visit an ophthalmologist. This study is a limited case-report that shows the occurrence of ocular complications based only on the patient's report and cannot definitively explain the cause of ocular complications. Future studies may be able to determine the exact cause of these complications using trace markers in the anesthetic.

CONCLUSION

Although ocular complications during tooth injection are very rare, it is important for the dental team to know the cause and management of these complications. In non-cooperative children, due to the possible occurrence of unwanted movements, safer local anesthetic injection or advance behavior control methods such as sedation and general anesthesia should be taken into account.

CONFLICT OF INTEREST STATEMENT

None declared.

REFERENCES

- Iwanaga J, Choi PJ, Vetter M, Patel M, Kikuta S, Oskouian RJ, Tubbs RS. Anatomical study of the lingual nerve and inferior alveolar nerve in the pterygomandibular space: complications of the inferior alveolar nerve block. *Cureus* 2018 Aug 6;10(8):e3109.
- Barodiya A, Thukral R, Agrawal SM, Rai A, Singh S. Temporary Blindness after Inferior Alveolar Nerve Block. *J Clin Diagn Res.* 2017 Mar;11(3):ZD24-ZD25.
- Pandey R, Dixit N, Dixit KK, Roy S, Gaba C. Amaurosis, an Unusual Complication Secondary to Inferior Alveolar Nerve Anesthesia: A Case Report and Literature Review. *J Endod.* 2018 Sep;44(9):1442-1444.
- Khalil H. A basic review on the inferior alveolar nerve block techniques. *Anesth Essays Res.* 2014 Jan-Apr;8(1):3-8.
- Steenen SA, Dubois L, Saeed P, Lange J. Ophthalmologic complications after intraoral local anesthesia: case report and review of literature. *Oral Surg Oral Med Oral Pathol Oral Radiol.* 2012 Jun;113(6):e1-5.
- Yoon RK, Chussid S. Ocular complications following an inferior alveolar nerve block on a child patient: a review of the literature and report of a case. *Pediatr Dent.* Jul-Aug 2012;34(4):343-6.
- Alamanos C, Raab P, Gamulescu A, Behr M. Ophthalmologic complications after administration of local anesthesia in dentistry: a systematic review. *Oral Surg Oral Med Oral Pathol Oral Radiol.* 2016 Mar;121(3):e39-50.
- You TM. Diplopia after inferior alveolar nerve block: case report and related physiology. *J Dent Anesth Pain Med.* 2015 Jun;15(2):93-96.
- Frangiskos F, Stavrou E, Merenditis N, Tsitsogianis H, Vardas E, Antonopoulou I. Incidence of penetration of a blood vessel during inferior alveolar nerve block. *Br J Oral Maxillofac Surg* 2003;41(3):188-189.
- Malamed SF. *Handbook of local anesthesia-e-book.* Elsevier Health Sciences; 2019; 157-160.
- Huang RY, Chen YJ, Fang WH, Mau LP, Shieh YS. Concomitant Horner and Harlequin Syndromes after Inferior Alveolar Nerve Block Anesthesia. *J Endod* 2013; 39(12):1654-57.
- Boynes S, Echeverria Z, Abdulwahab M. Ocular complications associated with local anesthesia administered in dentistry. *Dent Clin N Am.* 2010; 54: 677-686
- Lee C. Ocular complications after inferior alveolar nerve block. *Hong Kong Med Diary.* 2006; 11: 4-5
- Williams JV, Williams LR, Colbert SD, Revington PJ. Amaurosis, ophthalmoplegia, ptosis, mydriasis and periorbital blanching following inferior alveolar nerve anaesthesia. *Oral Maxillofac Surg.* 2011 Mar;15(1):67-70.
- Odabas, i O, S, ahin O, Polat ME. Transient amaurosis and diplopia after inferior alveolar nerve block. *J Craniofac Surg* 2017;28:e632-4.
- Verma DK, Rajan R, Prabhu S. Ipsilateral, isolated amaurosis after inferior alveolar nerve block: report of two rare cases. *Oral Maxillofac Surg* 2013;17:73-5.