

Natural Model Training, an Alternative Way to Enhance Learning in Pediatric Dentistry

Rasoul Sahebalam¹, Maryam Talebi², Shima Kazemian³, Majid Akbari⁴✉

¹Assistant Professor, Department of Pediatric Dentistry, Dental Research Center, Faculty of Dentistry, Mashhad University of Medical Sciences, Mashhad, Iran

²Associated Professor, Department of Pediatric Dentistry, Dental Research Center, Faculty of Dentistry, Mashhad University of Medical Sciences, Mashhad, Iran

³Dentist, Student Research Committee, Faculty of Dentistry, Mashhad University of Medical Sciences, Mashhad, Iran

⁴Associated Professor, Center of Excellence in Medical Education Technology, Mashhad University of Medical Sciences, Mashhad, Iran

Abstract

Objective: Educational teaching of the diagnosis of resorbed root for pulpectomy in deciduous teeth radiography has always been a big challenge in pediatric dentistry. The purpose of the study was to propose a new practical methodology to improve the quality of learning in students of dentistry.

Materials and Methods: Extracted deciduous teeth were molded in the transparent epoxy resin as their real position in the jawbone. Then, their own pre-extraction radiographs were attached to them. Forty dental students were randomly allocated to the control group of conventional teaching and experimental group of natural model training. All participants were attended in a validated exam and the data were analyzed. A questionnaire was designed with an answer choice in Lickert scale to measure the students' attitude towards the new method and finally the data were reported with descriptive statistics.

Results: The mean of the learning degree in the experimental group was graded 9.2 ± 3.2 and was significantly higher than 5.8 ± 1.1 which belongs to the participants of the conventional method as control ($p = 0.04 < 0.05$).

Conclusion: Considering the limitation of this study, using natural models in radiography training will improve the diagnostic competency and the student's educational satisfaction in pediatric dentistry.

Key Words: Pediatric Dentistry; Radiology; Pulpectomy; Medical Education Term

Journal of Dentistry, Tehran University of Medical Sciences, Tehran, Iran (2014; Vol. 11, No. 5)

✉ Corresponding author:
M. Akbari, Center of Excellence in Medical Education Technology, Mashhad University of Medical Sciences, Mashhad, Iran

akbarim@mums.ac.ir

Received: 28 March 2014

Accepted: 21 July 2014

INTRODUCTION

Modern dental education integrates conventional methods and new training policies such as simulation and virtual reality systems [1-3]. The current approach to training of hand skills for dental students involves the use of voxel-based models in order to represent a virtual tooth model [4].

However, it is not easy to resort to simulation with regards to other essential dental competencies such as diagnosis. Dental graduates should have the

ability to perform and interpret common radiological examinations in general dental practice. Determination of the disorders on radiographic images needs considerable knowledge of the anatomy. The most important reason for instruction of the anatomy is to accommodate the kind of education that provides students with spatial-mental models, offering them the appropriate insight for their daily practice. This is especially important in the field of radiology, in which practitioners need to routinely

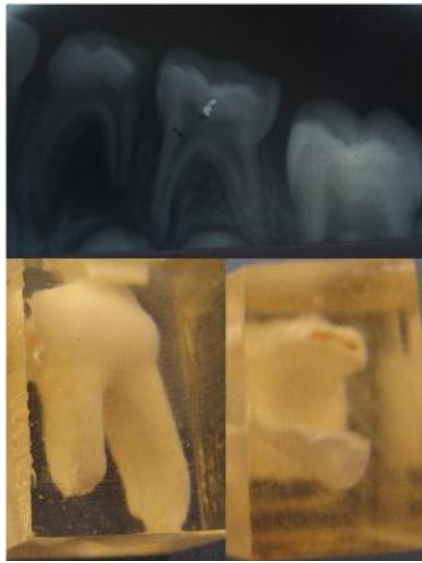


Fig 1. An extracted primary molar and the radiograph

examine radiographic images and to extract a three-dimensional perception from two-dimensional representations of the anatomy [5, 6]. The ability to determine the relative position of objects on radiographs can be described as an ability to mentally integrate 2D spatial information and to perform a transformation of that representation into 3D spatial information [7]. In pediatric dentistry, diagnosis based on radiograph imaging is one of the challenges in the education of dentistry due to overlap of the roots of the deciduous teeth with the buds of the successor permanent teeth as well as the diagnosis of the apex of resorbed roots. Simulator-supported radiology training is a method that offers a great value for students who are likely to fail in regular education methods. Moreover, generating 3D models based on cone beam computed tomography (CBCT) datasets may become another useful technique for demonstrating, planning and teaching. Mass production of these models is possible, but the availability of the computer numerical control (CNC) technology and the cost of model production in this method are existing challenges for developing countries without sufficient economic resources for education [8].

Therefore, alternative, more economical methods are required to help students in dental education to

understand the anatomical relations in radiology and to provide additional depth cues. This model needs to have the ability to mimic the characteristics of a real patient and to increase the spatial visualization of deciduous teeth and its resorbed anatomy. The aim of this study was to evaluate the impact of natural model-based training in pediatric dental radiology and to compare its effect on trainees' ability with that of the conventional training method routinely used at the department of pediatric dentistry, Mashhad University of Medical Sciences, Iran.

MATERIALS AND METHODS

To produce the "natural model" for pediatric dentistry, 30 hopeless extracted deciduous molars with relatively intact roots were collected. Selected cases were children between 4 and 10 years of age. All teeth with high-quality preapical radiographies (PA) were cleaned and disinfected by storing in 1% chloramin solution at least for a week. The teeth were mounted in transparent epoxy resin (Khoozestan Petrochemical Co, Iran) as positioned in the jawbone. Every tooth was attached to its pre-extraction radiograph and stored to be used as a "natural model" for pediatric radiography training (Figure 1). Forty fifth-year dental program undergraduates (out of a six-year pre-doctoral curriculum) voluntarily participated in the study (21 males and 19 females) at at Mashhad dental school in 2012. All aspects of the study were approved and performed in accordance with the guidelines of the ethical review process of Mashhad University of Medical Sciences. The design was a simple experimental study organized into three different parts, 1) Random allocation of participants 2) Educating radiographic landmarks used in the pulpectomy procedure in experimental and control groups with an allocated method 3) Proficiency testing after training and completing a questionnaire. A computerized randomization procedure based on the last pediatric dentistry exam results before training allocated participants to either the control or experimental group. The experimental group was assigned a natural model-based training program. The method was based on explaining the

anatomical landmarks on the radiographs along with the presentation of its natural model and apical region. Different types of resorption in the apical and forcation region that might alter the apical foramen and working length in pulpectomy of the primary teeth were discussed with the teeth mounted in transparent resin at sight. The control group received conventional training, namely explanations of the anatomical landmarks on the selected radiographs. Training lasted 30 minutes for both groups. Proficiency testing was then performed immediately after completion of training. All participants were finally assessed on their understanding of radiographic anatomy. The assessment consisted of 10 multiple-choice questions (MCQ) based on the radiographic anatomy as seen on 10 preapical radiographs (PA) taken from upper deciduous molars in patients aged 4 to 10 years old. The MCQ test was provided to each participant in a hard copy format, whereas the PAs corresponding to each question were provided in the form of a PowerPoint (office 2007) presentation on a screen. The total time allocated was 20 minutes (2 minutes per question), and each student had to circle one correct answer (out of three alternatives) on the hard copy sheet provided. The test was designed based on "must-learn" objects in diagnosis during the pulpectomy procedure and validated by the pediatric dentistry department members. The MCQ tests were marked by one of the authors (RS) in a blinded manner, and the score was calculated for each member of the groups. After completion of the intervention phase, each participant received the alternative training (the method used for the other group) and the students were subsequently asked to complete a questionnaire with three questions. The student's impressions were then assessed (in a qualitative term) regarding the effect of the "natural model-training tool" on their learning of pediatric radiographic anatomy. The questionnaire was designed on a four-point Likert scale with the following options: strongly agree, agree, disagree and strongly disagree to determine whether this tool enhanced the quality of learning. Statistical analysis of the groups was performed using the Student's t-test, and statistical signifi-

cance was accepted at the level of $P < 0.05$. The results of the questionnaire were finally analyzed by descriptive statistics.

RESULTS

Demography of the trial groups are presented in Table 1. The drop-out rate was 5 percent for the control group (one of twenty) and 30 percent (six of twenty) for the experiment group. Proximity of the test with the final courses of the semester on the schedule led to withdrawal of seven of the participants. The mean score of learning from the study was 9.2 ± 3.2 for the experiment group and higher than 5.8 ± 1.1 for the conventional method (control) group ($P=0.04 < 0.05$). The results of the questionnaire showed that most of the students thought that the new method resulted in more profound learning (96%) and was suitable for learning pediatric radiology (100%) and also that this method can save teaching time (92%) (Table 2).

DISCUSSION

The mean degree of learning in the natural model-training group was higher than the mean degree in the conventional method (control) group. Natural models in radiography training have improved the diagnostic competency in pediatric dentistry with regards to pulpectomy. This may be due to the increased interaction and engagement of the students visualizing the radiographs. Studies have shown that acquired skills can be long-lasting as long as the instruction using medical simulators is designed to involve hands-on practice or when performed on a repeated-practice-and-feedback basis [9-14]. Student's learning is significantly affected by their learning method, with the learning outcomes being strongly influenced by the learning process. The 'deep' approach is therefore, to promote better learning (or 'life-long'), as opposed to the 'surface' approach in which students try to memorize the text [15].

Table 1. Demography of Trial Groups

Group	Man	Woman	Total
Experiment	6	8	14
Control	9	10	19

This was in accordance with the data gained from the questionnaire. Other studies in medical education involving interactive 3D visualizations of anatomical structure showed similar results to those of this study. New methods are becoming increasingly prevalent in medicine for educational purposes, being proposed as an effectively successful alternative to the traditional learning resources [16-18]. Diagnosis and design of appropriate treatment sequences in pulpectomy require comprehensive understanding of the anatomy, especially of the root resorption in deciduous teeth that involves various spatial concepts, such as the shape of anatomical structures, the location of each partition relative to another, and how they are connected. Investigators in comprehension and learning sciences have defined visualization as external help with the potential for increasing or expanding cognition [19].

This method is believed to result in deep learning because of 3D imagination of the radiographs and better integration of radiologic landmarks and anatomy especially in resorbed roots. The other advantage of this method is enabling the rotation of the tooth in any direction, which may further help to improve the 3D visualization [20]. One of the mandatory skills required for each graduate of dentistry is the ability to interpret the common radiological examinations in general dental practice. Radiographic interpretations in medical students appear to be lacking accuracy. Studies have shown that the ability to interpret radiographs is not correlated to the level of medical education, which suggests that more emphasis should be placed on quality, rather than quantity in radiology learning and teaching [21]. It has been reported that simulators are currently used in the health care field for training of responses to cardiovascular emergencies in laparoscopic surgery, the emergency room,

and the operating room [22, 23].

Although the extended use of simulation for training purposes in dentistry is still an object of investigation, especially in the area of preclinical training [7], using anatomic data from patients seems to be an alternative method with a long tradition [4]. Educational simulators demand extended budgets, and that is a process that meets many limitations in developing countries. Thus, simple and technology-independent methods should be investigated to improve student learning.

This is a study with a limited number of individuals enrolled; therefore, a larger randomized study would have provided stronger evidence. One variable not included in this study was the learning style. It is possible that certain types of students may do better in the same study.

CONCLUSION

Despite the limitations of this study, it can be concluded that using natural models in radiography training seems to improve the diagnostic competency as well as the satisfaction of students in pediatric dentistry.

ACKNOWLEDGMENTS

The authors would like to thank the vice-chancellor for research of Mashhad University of Medical Sciences for the financial support of this project. The results presented in this study were obtained from the thesis of a DDS student.

REFERENCES

- 1- Jasinevicius TR, Landers M, Nelson S, Urbankova A. An evaluation of two dental simulation systems: virtual reality versus contemporary non-computer-assisted. J Dent Educ. 2004 Nov;68(11): 1151-62.

Table 2. Description of the Results of the Questionnaire

Questions: The new method	Strongly agree	Agree	Disagree	Strongly disagree
Causes more deep learning	92%	4%	4%	—
Is suitable for learning pediatric radiology	92%	8%	—	—
Is time consuming for teaching	4%	4%	8%	84%

- 2- LeBlanc VR, Urbankova A, Hadavi F, Lichtenhal RM. A preliminary study in using virtual reality to train dental students. *J Dent Educ.* 2004 Mar;68(3):378-83.
- 3- Güth JF, Ponn A, Mast G, Gemet W, Edelhoff D. Description and evaluation of a new approach on pre-clinical implant dentistry education based on an innovative simulation model. *Eur J Dent Educ.* 2010 Nov;14(4):221-6.
- 4- Yoshida Y, Yamaghuchi S, Kawamoto Y, Noborio H, Murakami S, Sohmura T. Development of a multi-layered virtual tooth model for the haptic dental training system. *Dent Mater.* 2011;30(1):1-6.
- 5- Wayne DB, Butter J, Siddall VJ, Fudala MJ, Linqvist LA, Feinglass J, et al. Simulation-based training of internal medicine residents in advanced cardiac life support protocols: a randomized trial. *Teach Learn Med.* 2005 Summer;17(3):210-6.
- 6- Wayne DB, Siddall VJ, Butter J, Fudala MJ, Wade LD, Feinglass J, et al. A longitudinal study of internal medicine residents' retention of advanced cardiac life support skills. *Acad Med.* 2006 Oct;81(10 Suppl):S9-S12.
- 7- Suvinen TI, Messer LB, Franco E. Clinical simulation in teaching preclinical dentistry. *Eur J Dent Educ.* 1998 Feb;2(1):25-32.
- 8- Jabero M, Sarment DP. Advanced surgical guidance technology: A review. *Implant Dent.* 2006 Jun;15(2):135-42.
- 9- Gallagher AG, Cates CU. Virtual reality training for the operating room and cardiac catheterization laboratory. *Lancet.* 2004 Oct;364(9444):1538-40.
- 10- Nestel D, Groom J, Eikeland-Husebo S, O'Donnell JM. Simulation for learning and teaching procedural skills: the state of the science. *Simul Healthc.* 2011 Aug;6 S10-3.
- 11- Lambrecht JT, Berndt D, Christensen AM, Zehnder M. Haptic model fabrication for undergraduate and postgraduate teaching. *Int J Oral Maxillofac Surg.* 2010 Dec;39(12):1226-29.
- 12- Nilsson T, Hedman L, Ahlqvist J. A randomized trial of simulation-based versus conventional training of dental student skill at interpreting spatial information in radiographs. *Simul Healthcare.* 2007;2(3):164-9.
- 13- Nilsson T, Hedman L, Ahlqvist J. Visual-spatial ability and interpretation of three-dimensional information in radiographs. *Dentomaxillofac Radiol.* 2007;36(2):86-91.
- 14- Stefanidis D, Korndorffer JR Jr, Sierra R, Touchard C, Dunne JB, Scott DJ. Skill retention following proficiency-based laparoscopic simulator training. *Surgery* 2005 Aug;138(2): 165-70.
- 15- Ross GC, Tuovinen JE. Deep versus surface learning with multimedia in nursing education development and evaluation of Wound Care. *Comput Nurs* 2001 Sep-Oct; 19(5): 213-23.
- 16- Grober ED, Hamstra SJ, Wanzel KR, Reznick RK, Matsumoto ED, Sidhu RS, et al. Laboratory-based training in urological microsurgery with bench model simulators: a randomized controlled trial evaluating the durability of technical skill. *J Urol.* 2004 Jul;172(1):378-81.
- 17- Bloom BS, Engelhart MD, Furst EJ, Hill WH, Krathwohl DR. Taxonomy of educational objectives: the classification of educational goals. Handbook 1, cognitive domain. New York: David McKay Company; 1956.
- 18- White SC, Pharoah MJ. Oral radiology: principles and interpretation. 5th ed. St. Louis: Mosby; 2004. p. 86-93.
- 19- Suebnukarn S, Rhiemora P, Haddawy P. The use of cone-beam computed tomography and virtual reality simulation for pre-surgical practice in endodontic microsurgery. *Int Endod J.* 2012 Jul;45(7):627-32.
- 20- Vuchkova J, Maybury TS, Farah CS. Testing the Educational Potential of 3D Visualization Software in Oral Radiographic Interpretation. *J Dent Educ.* 2011 Nov;75(11): 1417-25.
- 21- Margolis SA, Nilsson KA, Reed RL. Performance in reading radiographs: does level of education predict skill? *J Contin Educ Health Prof.* 2003 Winter;23(1):48-53.
- 22- Gallagher AG, McClure N, McGuigan J, Crothers I, Browning J. Virtual reality training in laparoscopic surgery: a preliminary assessment of minimally invasive surgical trainer virtual reality. *Endoscopy.* 1999 May;31(4): 310-3.
- 23- Small SD, Wuerz RC, Simon R, Shapiro N, Conn A, Setnik G. Demonstration of high fidelity simulation team training for emergency medicine. *Acad Emerg Med.* 1999 Apr;6 (4):312-23.