

Endodontic Management of Three-Canalled Mandibular Lateral Incisor Using Dental Operating Microscope

Vijayakumar Ashwinkumar¹, Suresh Nandini², Natanasabapathy Velmurugan³

¹Post Graduated Student, Department of Conservative Dentistry and Endodontics, Meenakshi Ammal Dental College and Hospital, India

²Department of Conservative Dentistry and Endodontics, Meenakshi Ammal Dental College and Hospital, India

³Professor, Department of Conservative Dentistry and Endodontics, Meenakshi Ammal Dental College and Hospital, India

✉ Corresponding author:

V. Ashwinkumar, Department of Conservative Dentistry and Endodontics, Meenakshi Ammal Dental College and Hospital, India

m_v_ashwin@yahoo.co.in

Received: 22 February 2014

Accepted: 7 April 2014

Abstract

This case report presents endodontic management of a mandibular lateral incisor with three canals using surgical dental operating microscope. This study describes the root canal variation of mandibular lateral incisor and highlights the importance of surgical operating microscope in detecting an unusual canal morphology.

Key Words: Endodontics; Dental Pulp; Incisor

Journal of Dentistry, Tehran University of Medical Sciences, Tehran, Iran (2014; Vol. 11, No. 4)

INTRODUCTION

Inadequate knowledge of tooth morphology and canal systems may pose significant problems during root canal treatment [1]. To ensure the long-term prognosis of a tooth undergoing root canal treatment, it is imperative to assess the anatomy of the root canals and their numerous variations before initiating root canal treatment [2,3]. The root canal anatomy of the mandibular lateral incisor usually has a single root with a single canal. Among the variations, the presence of an additional (lingual) canal is the most common. The incidence of the lingual canal has been reported as 44% [4,5]. Although a high incidence of a lingual canal has been reported, the majority of these canals will join and exit in a single foramen in 70% of the cases [4,6,7,8].

Few anomalies have been reported for the mandibular lateral incisor in the dental literature. Some of them include dens invaginatus

[9,10], fusion and germination [11]. The most common variation found in the mandibular lateral incisor is the presence of a second canal (lingual). Table 1 highlights various studies published on the root canal anatomy of mandibular lateral incisors.

The introduction of the dental operating microscope has revolutionized endodontic treatment. A microscope is the best tool in visualizing intricate dental anatomies otherwise not visible to the naked eye. The benefits of root canal procedures completed with a microscope include [4]:

Magnified image

Increased precision

Improved illumination

Improved visualization

On a thorough literature search it was observed that there has been no in-vitro or clinical case reports of a mandibular lateral incisor with three canals.

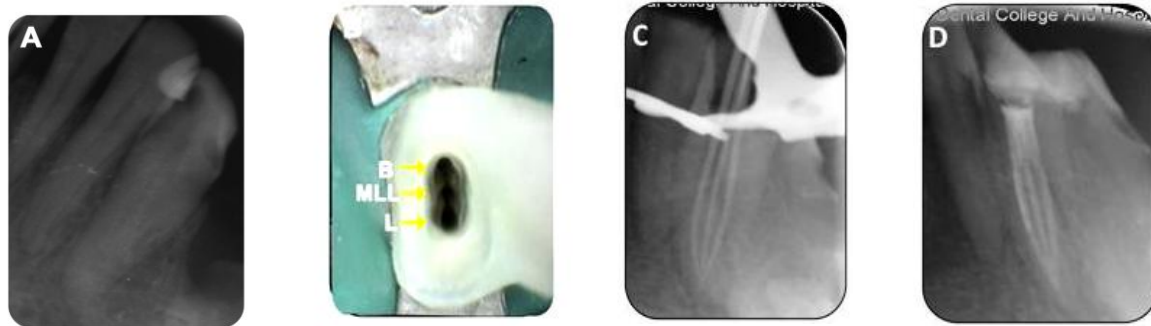


Fig 1. A, Pre-operative radiograph of tooth #23; B, Access opening of tooth #23 under dental operating microscope; C, Master cone radiograph; D, Obturation of tooth #23

The present case report discusses the successful endodontic management of a three-canal mandibular lateral incisor.

CASE REPORT

A 58-year-old woman was referred to the Department of Conservative Dentistry and Endodontics with the chief complaint of pain in her lower front teeth region.

The patient's medical history was noncontributory.

Dental history revealed dull, continuous pain in the left mandibular lateral incisor (tooth #23) for the past 1 month. On clinical examination, tooth #23 had a large proximal restoration and was tender on percussion (Fig 1A). Palpation of the labial and lingual aspect of the teeth did not reveal any tenderness. The tooth was immobile and periodontal probing around the tooth was within physiological limits.

No response was elicited in the tooth with the electronic pulp tester (EPT) (Parkel Electronics Division, Farmingdale, NY) and thermal (heat and cold) pulp vitality testing methods (Dentsply Maillefer, Ballaigues, Switzerland). A pre-operative radiograph revealed large proximal restoration close to the pulp space with periodontal ligament widening related to the left mandibular lateral incisor. Based on clinical and radiographic findings, a diagnosis of pulpal necrosis with symptomatic apical periodontitis was made for tooth #23. Tooth #23 was anesthetized with 1.8 mL (30 mg) 2% lignocaine containing 1:200,000 epinephrine (Xylocaine; AstraZeneca Pharma Ind Ltd, Bangalore, India) followed by rubber dam isolation. After access cavity preparation using a round carbide no #2 (MANI Inc, Toshigi-Ken, Japan), one labial and one lingual canal was identified in tooth #23, but on examination under surgical operating microscope (Seiler

Table 1. In-Vitro Studies on Root Canal Aberrations of Mandibular Lateral Incisors

Authors	Type of Study	Country	One Canal (%)	Two Canals (%)	Three Canals (%)
Vertucci (7)	Clearing	USA	98	2	-
Pineda and Kuttler (8)	Radiographic	Mexico	98.7	1.3	-
Caliskan et al. (3)	Clearing	Turkey	98	2	-
Sert and Bayirili (6)	Clearing (Men)	Turkey	90	10	-
	Clearing (Women)	Turkey	90	10	-
Walker (21)	Radiographic	China	99	1	-

Revelation, St Louis, MO), an additional canal was located between the labial and the lingual canal (Fig 1B).

This additional canal was initially negotiated using a C+ file ISO #8 (Dentsply Maillefer, Ballaigues, Switzerland). The working length was determined in all three canals using an apex locator (Root ZX; Morita, Tokyo, Japan) and was later confirmed by a radiograph. Coronal orifice opening was performed using Gates-Glidden drills No.2 and No.1 followed by cleaning and shaping with 2% stainless steel hand K-files up to ISO #30 (MANI Inc, Tshigi-Ken, Japan) using a crown-down technique. Irrigation was performed with 2.5% sodium hypochlorite and normal saline solution. Final irrigation was performed with 17% EDTA solution. Calcium hydroxide paste (RC CAL, Prime Dental Products Pvt Ltd, Mumbai, India) was used as an intracanal medication for a period of one week.

On the next appointment, the patient was asymptomatic. Calcium hydroxide paste was removed using ultrasonics. A master cone radiograph was taken to confirm the working length (Fig 1C). The canals were then dried with absorbent points (Dentsply Maillefer, Ballaigues, Switzerland), and obturation was performed using cold lateral compaction of gutta-percha (Dentsply Maillefer, Ballaigues, Switzerland) and AH Plus resin sealer (Maillefer, Dentsply, Konstanz, Germany) (Fig. 1D). The tooth was then restored with a posterior composite resin core (Z350; 3M Dental Products, St Paul, MN). The patient was asymptomatic during the 6-month follow up.

Tooth #26 that was also endodontically treated simultaneously had one buccal and one lingual canal. Endodontic treatment for tooth #26 was performed similar to that of tooth # 23.

DISCUSSION

Failure to identify extra canals is one of the most common reasons for the failure of endodontic treatment [12].

According to a recent study conducted by

Song et al., missed canal is the second most common reason for failure of endodontic treatment [13]. Multiple angulated pre-operative radiographs can help us identify complex root canal anatomies of the root canal system and thereby reduce the incidence of missed canals during routine endodontic therapy [14]. Use of higher investigation tools such as cone beam computed tomography (CBCT) has also been suggested for better understanding of the aberrations in the root canal anatomy [15,16]. Even though use of CBCT involves less radiation than conventional CT, the radiation dose is still higher than regular conventional intraoral radiographs [17].

In our case report, an additional canal was found between the labial and the lingual canal. This additional canal was termed as the midlabio-lingual (MLL) canal. This MLL canal was clearly distinguishable on examination under the surgical dental operating microscope. Use of the surgical operating microscope is indispensable in the field of endodontics. Matherne et al. [18] suggested the use of CBCT and surgical microscope to successfully diagnose various aberrations in the root canal anatomy. Sabala et al. [19] reported that in 60% of the cases, bilateral symmetry of variation is usually observed. He also stated that as the aberration increases, it is more likely to be bilateral in occurrence. In the present case report, all the three canals joined in the apical third of the root canal and exited as a single apical foramen. This pattern of root canal configuration is classified as type-I canal pattern according to a study conducted by Gulabivala et al. [20] and type- XVIII canal pattern based on a study performed by Sert and Bayirli [6]. Many mandibular incisors have two canals, which may merge into one canal before reaching the apex. In rare cases, separate foramina may form. In a radiographic study of 364 specimens, Benjamin and Dowson reported that 41.4% of the mandibular incisors had two separate canals; of which only 1.3% had two separate foramina [22].

Young et al. successfully managed three mandibular incisors with two separate canals and foramina. They suggested that manual exploration of the root canal system with an endodontic file or explorer is a reliable way to identify the exact configuration of the root canal, especially the number of foramina [23]. Kartal et al. studied the root canal morphology of 100 mandibular incisors and showed two additional canal configurations other than Vertucci's classification [24]. Type 6 was a newly defined canal configuration in which two separate canals leave the pulp chamber, a new tiny canal leaves the lingual canal in the middle third and comes to the midline, goes down to the apical third, and all of the canals merge together and constitute one canal joining at the apex. Type 7 was also newly defined.

After leaving the pulp chamber as a wide single canal, division occurs into two canals in the middle third.

These canals then rejoin into a single canal that splits again and exits as three separate foramina. Miyashita et al. showed that mandibular incisors possess a flat root that is longest in the labio-lingual direction, and furcate and ribbon-like canals occasionally appear in the center of the root. Therefore, the problem exists for instrumentation of the labio-lingual wall of ribbon-like root canals and also clinically it is almost impossible to discriminate between separate canals and ribbon-like canals [25]. Fortunately, only 3.1% of the samples have separate canals to two apical foramina. Therefore, authors suggest the use of circumferential filing rather than circular filing to prevent incomplete cleaning and shaping of the root canal system.

CONCLUSION

The present case report describes the endodontic management of a mandibular lateral incisor with three root canals. It highlights the importance of the dental operating microscope in detecting extra canals for successful endodontic treatment.

REFERENCES

- 1- Al-Qudah AA, Awawdeh LA. Root canal morphology of mandibular incisors in a Jordanian population. *Int Endod J.* 2006 Nov;39(11):873-7.
- 2- Vertucci FJ. Root canal anatomy of the human permanent teeth. *Oral Surg Oral Med Oral Pathol Oral Radiol Endod.* 1984 Nov;58(5):589-99.
- 3- Caliskan MK, Pehlivan Y, Sepetcioglu F, Turkun M, Tuncer SS: Root canal morphology of human permanent teeth in a Turkish population. *J Endod.* 1995 Apr;21(4):200-4.
- 4- Ingle JI, Bakland LK, Baumgartner J. *Ingle's Endodontics.* 6th ed. Hamilton, ON: BC Decker Inc.; 2008.
- 5- Boruah LC, Bhuyan AC. Morphologic characteristics of root canal of mandibular incisors in North-East Indian population: An in vitro study. *J Conserv Dent.* 2011 Oct;14(4):346-50.
- 6- Sert S, Bayirli GS. Evaluation of the root canal configuration of the mandibular and maxillary permanent teeth by gender in the Turkish population. *J Endod.* 2004 Jun;30(6):391-98.
- 7- Vertucci FJ. Root canal anatomy of the mandibular anterior teeth. *J Am Dent Assoc.* 1974 Aug;89(2):369-71.
- 8- Pineda F, Kuttler Y. Mesiodistal and buccolingual roentgenographic investigation of 7275 root canals. *Oral Surg Oral Med Oral Pathol.* 1972 Jan;33(1):101-10.
- 9- Beltes P. Endodontic treatment in three cases of dens invaginatus. *J Endod.* 1997 Jun;23(6):399-402.
- 10- Goncalves A, Goncalves M, Oliveira DP, Goncalves N. Dens invaginatus type III: report of a case and 10-year radiographic follow up. *Int Endod J.* 2001 Oct;35(10):873-89.
- 11- Brown P, Herbranson E. *Dental anatomy and 3D tooth atlas: version 3.0.* 2nd ed. Carol Stream, IL: Quintessence; 2005.
- 12- Grossman IL, Oliet S, Del Rio E. *Endodontic practice.* 11th ed. Philadelphia, PA: Lea and Fabringer; 1988. 145-51.

- 13- Song M, Kim HC, Lee W, Kim E. Analysis of the cause of failure in nonsurgical endodontic treatment by microscopic inspection during endodontic microsurgery. *J Endod.* 2011 Nov;37(11):1516-19.
- 14- Kottoor J, Velmurugan N, Sudha R, Hemamalathi S. Maxillary first molar with seven root canals diagnosed with cone-beam computed tomography scanning: a case report. *J Endod.* 2010 May;36(5):915-21 .
- 15- Kottoor J, Hemamalathi S, Sudha R, Velmurugan N. Maxillary second molar with 5 roots and 5 canals evaluated using cone beam computerized tomography: a case report. *Oral Surg Oral Med Oral Pathol Oral Radiol Endod.* 2010 Feb;109(2):162-5.
- 16- La SH, Jung DH, Kim EC, Min KS. Identification of independent middle mesial canal in mandibular first molar using cone-beam computed tomography imaging. *J Endod.* 2010 Mar;36(3):542-5.
- 17- Ludlow JB, Davies-Ludlow LE, Brooks SL, Howerton WB. Dosimetry of 3 CBCT devices for oral and maxillofacial radiology: CB Mercuray, NewTom 3G and i-CAT. *Dentomaxillofac Radiol.* 2006 Jul;35(4):219-26.
- 18- Matherne RP, Angelopoulos C, Kulild JC, Tira D. Use of cone-beam computed tomography to identify root canal systems in vitro. *J Endod.* 2008 Jan;34(1):87-9.
- 19- Bilateral root or root canal aberrations in a dental school patient population. *J Endod.* 1994 Jan;20(1):38-42.
- 20- Gulabivala K, Aung TH, Alavi A, Mg Y-L: Root and canal morphology of Burmese mandibular molars, *Int Endod J.* 2001 Jul;34(5):359-70.
- 21- Walker RT. The root canal anatomy of mandibular incisors in a southern Chinese population. *Int Endod J.* 1988 May;21(3):218-23.
- 22- Benjamin KA, Dowson J. Incidence of two root canals in human mandibular incisor teeth. *Oral Surg Oral Med Oral Pathol.* 1974 Jul;38(1):122-6.
- 23- Hwang YH, Min KS. Clinical management of 3 mandibular incisors with 2 separate canals and foramina: case report. *J Can Dent Assoc.* 2005 Jun;71(6):388-9.
- 24- Kartal N, Yanikoglu FC. Root canal morphology of mandibular incisors. *J Endod.* 1992 Nov;18(11):562-64.
- 25- Miyashita M, Kasahara E, Yasuda E, Yamamoto A, Sekizawa T. Root canal system of the mandibular incisor. *J Endod.* 1997 Aug;23(8):479-84.