

Apical Extrusion of Irrigants in Immature Permanent Teeth by Using EndoVac and Needle Irrigation: An In Vitro Study

N. Velmurugan¹, C. Sooriaprakas², Preetham Jain²✉

¹Professor, Department of Conservative Dentistry and Endodontics, Meenakshi Ammal Dental College and Hospital, Chennai, Tamil Nadu, India

²Post Graduate Student, Department of Conservative Dentistry and Endodontics, Meenakshi Ammal Dental College and Hospital, Chennai, Tamil Nadu, India

Abstract

Objective: Immature teeth have a large apical opening and thin divergent or parallel dentinal walls; hence, with conventional needle irrigation there is a very high possibility of extrusion. This study was done to compare the apical extrusion of NaOCl in an immature root delivered using EndoVac and needle irrigation.

Materials and Methods: Eighty freshly extracted maxillary central incisors were decoronated followed by access cavity preparation. Modified organotypic protocol was performed to create an open apex; then, the samples were divided into four groups (n=20): EndoVac Microcannula (group I), EndoVac Macrocan- nula (group II), NaviTip irrigation needle (group III) and Max-i-Probe Irrigating needle (group IV); 9.0 ml of 3% sodium hypochlorite was delivered slowly over a period of 60 seconds. Extruded irrigants were collected in a vial and analysed sta- tistically.

Results: Group I, group III and group IV showed 100% extrusion (20/20) but group II showed only 40% extrusion (8/20). The difference in this respect between group II and other groups was statistically significant (P<0.001). With regards to the volume of extrusion, group II had only 0.23 ml of extruded irrigant. Group I extruded 7.53ml of the irrigant. Group III and group IV extruded the entire volume of irrigant delivered.

Conclusion: EndoVac Macrocanula resulted in the least extrusion of irrigant in immature teeth when compared to EndoVac Microcannula and conventional needle irrigation.

Key Words: Open apex; Extrusion; Irrigation

✉ Corresponding author:
N. Velmurugan, Department of
Conservative Dentistry and
Endodontics, Meenakshi Am-
mal Dental College and Hospit-
al, Chennai, India

vel9911@yahoo.com

Received: 20 January 2014

Accepted: 29 April 2014

Journal of Dentistry, Tehran University of Medical Sciences, Tehran, Iran (2014; Vol. 11, No. 4)

INTRODUCTION

Endodontic management of necrotic immature permanent teeth is often difficult, as such teeth lack an apical stop and are also weak and fra- gile [1,2].

Traditionally, the treatment of choice in these teeth has been apexification using calcium hy- droxide or mineral trioxide aggregate (MTA) [3]. Apexification procedures do not result in continued root development.

A barrier is induced or created in the apical region against which obturation is performed; but these roots still remain short and are susceptible to fracture [4]. Hence, currently there is a shift in focus towards a more biological treatment called revascularization that allows for continued root development. Numerous case reports and case series on successful revascularization of necrotic immature teeth have been recently reported [5-8].

Three critical components identified to contribute to the successful outcome of this procedure are the presence of stem cells, signalling molecules (growth factors) and a 3-dimensional physical scaffold [9].

Revascularization procedures involve disinfecting the root canal by using sodium hypochlorite (NaOCl), and placement of an intracanal medicament. After 2-3 weeks, an intentional over instrumentation is done to induce bleeding into the root canal. Once a clot is formed inside the root canal, a cervical barrier with mineral trioxide aggregate is placed [4]. Root canal irrigants that are used for disinfection in immature teeth should not cause any damage to the stem cells. Trevino et al. [10] stated that NaOCl used for disinfecting the immature root canals should be used very carefully, as any extrusion of this irrigant can result in damage to these stem cells. Immature teeth have a large apical opening and thin divergent or parallel dentinal walls and hence with conventional needle irrigation there is a very high possibility of extrusion.

The EndoVac system (Discus Dental, Culver City, CA, USA) was introduced in 2007 and was designed to safely deliver irrigants to the apical terminus of the root canals. The device consisted of a delivery/evacuation tip that is attached to a syringe containing the irrigant and high speed suction of the dental chair. Using a combination of macro or micro cannulae attached to the suction device, the irrigant is introduced into the pulp chamber and is then pulled by negative pressure down the canal into the tip of the cannula and then removed

through a coronally positioned suction hose [11, 12].

Apical negative pressure system has proven to be the safest when compared to other irrigation systems, in terms of extrusion in teeth with mature apices [11]. Fukumoto et al. evaluated the intracanal aspiration technique for irrigation and found it to be superior for smear layer removal, when compared with conventional irrigation. They also reported that this intracanal aspiration technique resulted in limited extrusion of irrigants beyond the apical foramen in canine teeth where the apex of the root was resected [13]. To date, there are no studies done on extrusion of irrigants in immature teeth using EndoVac. Hence, the aim of this study was to compare the apical extrusion of NaOCl in immature roots delivered using EndoVac and needle irrigation. In addition, this study quantified the volume of irrigant extruded in immature permanent teeth.

MATERIALS AND METHODS

Eighty freshly extracted adult permanent maxillary central incisors were used. The study design was analyzed and approved by the Institutional Review Board of Meenakshi Ammal Dental College, Meenakshi University, Tamil Nadu, India. Collection, storage, sterilization, and handling of extracted teeth followed Occupational Safety and Health Administration guidelines and regulations. Each tooth was radiographed to confirm the presence of a single canal and all the teeth were decoronated and the root length was standardized to 17 mm. Endodontic access was achieved and the canals were negotiated with an ISO size #15 stainless steel K file (MANI Inc, Toshi-gi-Ken, Japan) until the tip just appeared through the apical foramen.

Preparation of Modified Root Canal Organotypic Model

The teeth were then instrumented under constant sterile saline irrigation using peeso reamer (MANI Inc, Toshi-gi-Ken, Japan) from

size 1-4 to create an apical opening of 1.3 mm in diameter and simulate an open/immature apex. Trevino et al. [10] suggested the organotypic model for creating immature apex wherein LSX instrument to the size of 130 was used. Since a peeso reamer size 4 corresponds to size 130, it was used to create an immature apex. The samples were then divided randomly into four groups of 20 teeth each based on the irrigant delivery system.

The recommended protocol for using apical negative pressure irrigation system includes 2 main phases namely, macroirrigation and microirrigation [12]. Since this study aimed to evaluate the apical extrusion of irrigants in open apices, the manufacturer's recommended protocol was modified. The protocol suggested by Nester Cohenca et al. was followed in this study [14].

Group I: (EndoVac Microcannula)

Irrigation with EndoVac (Discus Dental, Culver City, CA, USA) system was started by placing the microcannula at 16 mm. Then, 9.0 ml of 3% sodium hypochlorite was delivered slowly over a period of 60 seconds through the master delivery/evacuation tip that was placed above the access opening.

Group II: (EndoVac Macrocannula)

Irrigation with EndoVac (Discus Dental, Culver City, CA, USA) system was started by placing macrocannula at 16 mm. Then, 9.0 ml of 3% sodium hypochlorite was delivered slowly over a period of 60 seconds through the master delivery/evacuation tip that was placed above the access opening.

Group III: (Conventional NaviTip irrigation needle)

Irrigation with NaviTip (Ultradent products Inc. India) 29 gauge needle was done by placing the needle 2 mm short of the working length.

Then, 9.0 ml of 3% sodium hypochlorite was delivered slowly over a period of 60 seconds.

Group IV: (Conventional Max-i-Probe Irrigating needle)

Irrigation with Max-i-Probe (Dentsply India Pvt. Ltd. New Delhi, India) was done by placing the needle 2 mm short of the working length. Then, 9.0 ml of 3% sodium hypochlorite was delivered slowly over a period of 60 seconds.

Experimental model to collect the extruded irrigants

Experimental model used in this study was based on the Myers and Montgomery model [15]. A vial with a rubber stopper was taken and a hole was created with a heated instrument in the center of the rubber stopper. The tooth was then inserted under pressure into the rubber stopper which was fixed to the cementoenamel junction using cyanoacrylate glue. Another glass vial (smaller in size than the previous vial) that fits tightly into the suspended apical portion of the root was used as the collecting container.

The whole assembly of rubber stopper with the collecting container was inserted into the main vial. To equalize the pressure, a 23-gauge needle was inserted into the rubber stopper (Figure 1). The irrigation protocol was performed in each group and the irrigant extruded periapically was collected. The volume of extruded irrigant was measured by using a calibrated collection vial.

The root canal diameter was very large when compared to the needle diameter (this may be the reason why the entire irrigant fluid escaped without wetting the canal).

Statistical analysis

Presence or absence of extrusion of irrigant in each group was determined. In addition to this, the volume of irrigant extruded in each group was calculated. For the extrusion of irrigants, Fisher's exact test was used to compare the proportions. The mean values in groups I and II were statistically analyzed using independent sample t-test.

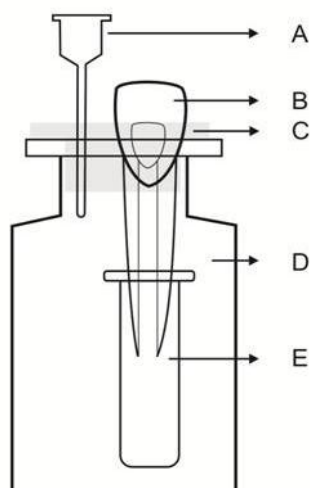


Fig 1. Experimental model to collect the extruded irrigants.

- A- Needle
- B- Teeth with an open apex
- C- Rubber stopper
- D- Vial
- E- Collecting vial

In the present study, the level of significance was set at 0.05. The statistical analysis was conducted using SPSS 17 software (SPSS Inc, Chicago, Ill., USA).

RESULTS

All the samples in group I, group III and group IV showed extrusion (100%) while only 8 samples in group II showed extrusion (40%). There was a statistically significant difference (P< 0.001) between group II and other groups (Table 1).

Regarding the volume of irrigant extrusion, group III and group IV extruded the entire volume of irrigants (9ml) and were considered the worst. Group II extruded significantly less volume of irrigant when compared to group I. There was a statistically significant difference between groups I and II (P< 0.001, Table 2).

DISCUSSION

Various stem cells that may play a role in revascularization are dental pulp stem cells (DSPSCs), stem cells from PDL or bone and stem cells from the apical papilla (SCAP) [16, 17]. Of all these stem cells, SCAP are thought to play a major role as they are in close proximity to the apical root canal [18]. It is speculated that during over instrumentation these SCAP get seeded into the root canal. These SCAP allow revascularization to occur in the presence of a blood clot which acts as a scaffold and also provides growth factors [19, 20]. Disinfection of the root canal in immature teeth during the revascularization procedure is mainly carried out by the use of irrigants and by placement of intracanal medicaments. NaOCl and triple antibiotic paste are the most commonly used irrigants and medicaments by most authors [21].

Mechanical instrumentation is usually avoided in these teeth, as it might further weaken the thin dentinal walls and also result in the formation of smear layer [4].

Table 1. The intergroup comparison for the presence or absence of extrusion of irrigants

Extrusion	Group								Total	χ ² -Value	P-Value	
	Group I		Group II		Group III		Group IV					
	N	%	N	%	N	%	N	%				
Yes	20	100.0	8	40.0	20	100.0	20	100.0	68	85.0		
No	0	0.0	12	60.0	0	0.0	0	0.0	12	15.0	42.35	<0.001
Total	20	100.0	20	100.0	20	100.0	20	100.0	80	100.0		

The SCAP are in close proximity to the root tip [18]. Any extrusion of NaOCl during irrigation is likely to damage these cells; which are vital for revascularization [10].

Nestor cohenca et al. reported that the EndoVac macrocannula was efficient in disinfecting immature teeth in dogs. They further stated that it may be safe to use EndoVac in immature teeth to prevent extrusion [14]. To date, there are no studies done on extrusion of irrigants in immature teeth using EndoVac. Hence, this study was done to compare the apical extrusion of NaOCl while using EndoVac and needle irrigation systems. In addition, this study quantified the volume of irrigant extruded in immature permanent teeth.

The model used in this study was based on the Myers and Montgomery model used for testing extrusion in case of mature roots [15]. Trevino et al. suggested the organotypic model for creating an immature apex wherein LSX instrument to the size of 130 was used [10].

In this study, we followed a modified organotypic model protocol with peeso reamers (size 1-4), which was used to prepare a parallel-walled canal space with constant 1.3 mm diameter without destroying the structural integrity of the root. The results of the present study revealed that all four groups showed extrusion of irrigants. Extrusion was seen in all samples (100%) in groups I, III and IV; whereas, in group II (EndoVac macrocannula) extrusion was seen in only 8 out of 20 samples (40%). Group II had significantly less extrusion when compared to the other groups. Our results were similar to those of an earlier study by Ross Paton et al, who reported less extrusion of irrigants with EndoVac in teeth with mature apices, where extrusion was seen in 2 out of 24 samples (8.33%) [22].

In terms of volume of extrusion, group II (EndoVac macrocannula) extruded significantly lower volume of irrigant when compared to the other groups. Group I extruded less volume of irrigants when compared to groups III and IV.

In groups III (closed ended) and IV (open ended), samples leaked the entire 9 ml of irrigants used, in spite of the needle being placed 2 mm short of the working length.

Recently, Zoi Psimma et al. used point-conductivity probe method to assess irrigant extrusion. They reported that the open ended needle caused more extrusion than closed ended needle and the extrusion of irrigants decreased as the needles were moved away from the working length [23]. In our study both open ended and closed ended needles caused extrusion of the entire volume of irrigants used. The mean volume of extrusion was 7.53 and 0.23 ml for microcannula and macrocannula groups, respectively. EndoVac macrocannula extruded only 0.23 of 9 ml delivered but it is still not clear whether this small amount will cause any significant damage to the stem cells and needs further investigation.

Both EndoVac microcannula and macrocannula are connected to the chair-side suction apparatus. Less extruded volume in macrocannula may be due to the large diameter (0.55 mm) of the opening of the macrocannula and the presence of this opening at the tip of the cannula in contrast to the microcannula which is of smaller diameter (0.10 mm) and has only side vents.

We used an open ended model to test the extrusion as the worst case scenario. However, in clinical situations some resistance to extrusion will be provided by the periapical tissue and bone.

Table 2. Using independent sample t-test to compare the mean volume (ml) of irrigants extruded between groups

Groups	N	Mean	Std. Deviation	P-Value
Group I	20	7.53	0.472	<0.001
Group II	20	0.23	0.302	

Recently, it has been established that even 1 microgram of triple antibiotic paste can be toxic to stem cells; hence, to avoid the extrusion of sodium hypochlorite it is better to use the EndoVac macrocannula for irrigation in an immature apex [24].

CONCLUSION

Within the limitations of this study, EndoVac macrocannula (apical negative pressure technique) resulted in the least extrusion of irrigant beyond the apex in immature teeth when compared to EndoVac microcannula and conventional needle irrigation.

REFERENCES

- 1- Giuliani V, Baccetti T, Pace R, Pagavino G. The use of MTA in teeth with necrotic pulps and open apices. *Dent Traumatol* 2002; 18:217-21.
- 2- Al Ansary MA, Day PF, Duggal MS, Brunton PA. Interventions for treating traumatized necrotic immature permanent anterior teeth: inducing a calcific barrier & root strengthening. *Dent Traumatol* 2009; 25:367-79.
- 3- El Meligy OA, Avery DR. Comparison of apexification with mineral trioxide aggregate and calcium hydroxide. *Pediatr Dent* 2006; 28:248-53.
- 4- Kenneth M. Hargreaves, Stephen Cohen. *Pathways of the pulp*. 10th edition.
- 5- Wigler R, Kaufman AY, Lin S, Steinbock N, Hazan-Molina H, Torneck CD. Revascularization: A treatment for permanent teeth with necrotic pulp and incomplete root development. *J Endod* 2013; 39:319-2.
- 6- Gelman R, Park H. Pulp revascularization in an immature necrotic tooth: a case report. *Pediatr Dent* 2012; 34:496-9.
- 7- Aggarwal V, Miglani S, Singla M. Conventional apexification and revascularization induced maturogenesis of two non-vital, immature teeth in same patient: 24 months follow up of a case. *J Conserv Dent* 2012; 15:68-72.
- 8- Jadhav G, Shah N, Logani A. Revascularization with and without platelet-rich plasma in nonvital, immature, anterior teeth: A pilot clinical study. *J Endod* 2012; 38:1581-87.
- 9- Hargreaves KM, Geisler T, Henry M, Wang Y. Regeneration potential of the young permanent tooth: What does the future hold? *J Endod* 2008; 34:S51-S56.
- 10- Trevino EG, Patwardhan AN, Henry MA, Perry G, Dybdal-Hargreaves N, Hargreaves KM, et al. Effect of irrigants on the survival of human stem cells of the apical papilla in a platelet-rich plasma scaffold in human root tips. *J Endod* 2011; 37:1109-15.
- 11- Desai P, Himel V. Comparative safety of various intracanal irrigation systems. *J Endod* 2009; 35:545-49.
- 12- Nielsen BA, Baumgartner JC. Comparison safety of various intracanal irrigation system. *J Endod* 2009; 35:545-49.
- 13- Fukumoto Y, Kikuchi I, Yoshioka T, Kobayashi C, Suda H. An ex vivo evaluation of a new root canal irrigation technique with intracanal aspiration. *Int Endod J* 2006; 39:93-99.
- 14- Cohenca N, Heilborn C, Johnson JD, Flores DS, Ito IY, da Silva LA. Apical negative pressure irrigation versus conventional irrigation plus triantibiotic intracanal dressing on root canal disinfection in dog teeth. *Oral Surg Oral Med Oral Pathol Oral Radiol Endod*. 2010 Jan; 109(1):e42-6.
- 15- Myers GL, Montgomery S. Comparison of weights of debris extruded apically by conventional filing and canal master techniques. *J Endod* 1991; 17:275-7.
- 16- Huang GT, Gronthos S, Shi S. Mesenchymal stem cells derived from dental tissues vs. those from other sources: their biology and role in regenerative medicine. *J Dent Res*. 2009 Sep; 88(9):792-806.
- 17- Sonoyama W, Liu Y, Yamaza T, Tuan RS, Wang S, Shi S, et al. Characterization of the apical papilla and its residing stem cells from human immature permanent teeth: A pilot study. *J Endod* 2008; 34:166-71.
- 18- Lovelace TW, Henry MA, Hargreaves KM. Evaluation of the delivery of mesenchymal stem cells into the root canal space of ne-

- crotic immature teeth after clinical regenerative endodontic procedure. *J Endod* 2011;37:133-38.
- 19- Banchs F, Trope M. Revascularization of immature permanent teeth with apical periodontitis : new treatment protocol? *J Endod* 2004 ;30:196-200.
- 20- Jung IY, Lee SJ, Hargreaves KM. Biologically based treatment of immature permanent teeth with apical pulpal necrosis : a case series. *J Endod* 2008; 34:876-87.
- 21- Kottor J, Velmurugan N. Revascularization for a necrotic immature permanent lateral incisor: a case report and literature review. *Int J Paediatr Dent* 2012; 20.
- 22- Mitchell RP, Yang SE, Baumgartner JC. Comparison of Apical Extrusion of NaOCl Using the EndoVac or Needle Irrigation of Root Canals. *J Endod* 2010; 36:338-41.
- 23- Psimma Z, Boutsoukis C, Kastrinakis E, Vasiliadis L. Effect of Needle Insertion Depth and Root Canal Curvature on Irrigant Extrusion Ex Vivo. *J Endod* 2013 ;39:521-4.
- 24- Phumpatrakom P, Srisuwan T. Regenerative capacity of human dental pulp and apical papilla cells after treatment with a 3-antibiotic mixture. *J Endod*. 2014 Mar;40(3):399-405.