



# Effect of Extent of White Spot Lesions on the Esthetic Outcome After Treatment by the Resin Infiltration Technique: A Clinical Trial

Sima Gholami<sup>1</sup>, Alireza Boruziniat<sup>2</sup>, Atoosa Talebi<sup>1</sup>, Yasaman Yazdandoust<sup>3\*</sup>

1. Department of Restorative and Cosmetic Dentistry, School of Dentistry, Mashhad University of Medical Science, Mashhad, Iran

2. Dental Research Center, Department of Restorative and Cosmetic Dentistry, School of Dentistry, Mashhad University of Medical Science, Mashhad, Iran

3. Dental Research Center, School of Dentistry, Mashhad University of Medical Science, Mashhad, Iran

## Article Info

**Article type:**  
Original Article

## Article History:

Received: 25 Oct 2022

Accepted: 20 Apr 2023

Published: 22 Oct 2023

## \* Corresponding author:

Dental Research Center, Department of Restorative and Cosmetic Dentistry, School of Dentistry, Mashhad University of Medical Science, Mashhad, Iran

Email:

[yasamanyazdandoust@gmail.com](mailto:yasamanyazdandoust@gmail.com)

## ABSTRACT

**Objectives:** This study aimed to assess the effect of extent of white spot lesions (WSLs) on the esthetic outcome (masking effect and durability) for 6 months after treatment by the resin infiltration technique.

**Materials and Methods:** In this clinical trial, 79 teeth with WSLs in 18 patients were selected. The lesions were assigned to localized and generalized groups, and were all treated by resin infiltration. The color of WSLs was assessed at baseline, immediately after treatment, and 1, 3, and 6 months after treatment by using Easy Shade spectrophotometer and taking standard digital photographs. The surface area of WSLs was calculated on the photographs using MIP4Student software. Repeated Measures ANOVA was used to compare color change ( $\Delta E$ ), and the Pearson's correlation test was applied to analyze the association between the extent of lesions and  $\Delta E$  ( $\alpha=0.05$ ).

**Results:** A significant difference was found between the two groups in  $\Delta E$  at different time points ( $P<0.05$ ). Also, in both localized and generalized lesions, the pretreatment  $\Delta E$  was significantly different from the  $\Delta E$  values at different time points after treatment ( $P<0.001$ ). However, the post-treatment  $\Delta E$  values were not significantly different ( $P>0.05$ ). The Pearson test showed an inverse correlation between the extent of lesions and  $\Delta E$  ( $P<0.05$ ).

**Conclusion:** The resin infiltration technique is successful in masking the WSLs, with a durability of at least 6 months. Color correction by this technique is more favorable in localized lesions.

**Keywords:** Dental Caries; Dental Enamel; Color

- **Cite this article as:** Gholami S, Boruziniat A, Talebi A, Yazdandoust Y. Effect of Extent of White Spot Lesions on the Esthetic Outcome After Treatment by the Resin Infiltration Technique: A Clinical Trial. *Front Dent.* 2023;20:40

## INTRODUCTION

White spot lesions (WSLs) are opaque chalky white enamel lesions without cavities that lose their translucency due to extensive porosity of the subsurface following demineralization [1]. WSLs can be categorized into two groups of pre-eruption and post-tooth eruption injuries. Pre-eruption injuries include developmental enamel lesions such as fluorosis, enamel

hypoplasia, molar-incisor hypomineralization, drug-induced enamel demineralization, traumatic hypomineralization, and infection [2]. Localized areas of demineralization/caries in non-orthodontic patients or lesions associated with the use of orthodontic appliances are classified under the category of post-tooth eruption injuries [3]. They are usually detected on the labial surface of

anterior teeth and interproximal contact areas as incipient class II lesions in posterior teeth [4].

The incidence of WSLs increased by 29.2% from 1986 to 2012 [5]. They are among the common side effects of orthodontic treatment. Also, they can cause long-lasting adverse effects on dental esthetics and quality of life [3]. In addition to esthetic problems of the anterior teeth, progression of demineralized lesions on the outer tooth surface (in case of poor oral hygiene) may increase the need for restorative procedures [6].

Two protocols may be considered for treatment of WSLs: stopping the progression of lesions through remineralization and improving their appearance [6]. Use of fluoride compounds, antimicrobial agents such as chlorhexidine, chitosan, chewing gums containing xylitol, and application of casein phosphopeptide amorphous calcium phosphate (CPP-ACP) compounds such as MI Paste and MI Paste Plus are among the suggested treatments for remineralization of lesions. Micro-abrasion and external bleaching are also recommended for improvement of the esthetic appearance of WSLs [7]. The effects of conservative treatments such as fluoride therapy are unsatisfactory due to their limited remineralizing effects and unpredictable patient cooperation [3].

Resin infiltration is another method used to prevent the progression of WSLs. This method is based on application of a low-viscosity resin with high surface tension and a small contact angle [8]. The porosities in demineralized enamel are filled with air (RI=1) and water (RI=1.33), which seem opaque in comparison to sound enamel. Since the pores are filled with resin (RI=1.52) in resin infiltration technique, the appearance of infiltrated enamel becomes similar to that of the adjacent sound enamel (RI=1.62) [9, 10].

The resin infiltration technique has several benefits, including improvement of mechanical stability of demineralized enamel, preservation of the adjacent hard tissue, permanent closure of surface micro-pores and cavities, filling of deep demineralized cavities, stopping the caries progression, reducing the

risk of secondary caries, delaying the restorative intervention for an extended period of time, no risk of postoperative sensitivity and pulpitis, reducing the risk of gingivitis and periodontitis, improving esthetics when applied to cover superficial WSLs, and high patient acceptance [11]. Several studies have demonstrated the effectiveness of the resin infiltration technique for improvement of the esthetic appearance of WSLs compared with remineralization agents such as CPP-ACP or fluoride [12-14]. However, some other studies concluded that this technique might partially mask the white appearance of WSLs, especially in developmental lesions, and has uncertain results in long-term follow-ups [9, 10].

There is a lack of evidence about the effect of surface area of WSLs on the masking effect and efficacy of the resin infiltration technique for prevention of the progression of WSLs. Therefore, this study aimed to assess the effect of extent of WSLs on the esthetic outcome (masking effect and durability) for 6 months after treatment by the resin infiltration technique. The null hypotheses tested in this study were as follows: (I) There would be no significant color change ( $\Delta E$ ) within each group over time after the application of resin infiltrant, (II) there would be no significant correlation between the extent of WSLs and  $\Delta E$ .

## MATERIALS AND METHODS

This clinical trial was conducted at the Restorative and Cosmetic Dentistry Department of Dental School of Mashhad University of Medical Sciences after it was methodologically approved by the Ethics Committee of the university (IR.MUMS.sd.REC.1393.4). The study was registered in the Iranian Registry of Clinical Trials (IRCT20180624040223N1).

### **Sample size:**

The sample size was calculated to be 57 patients to find a clinically relevant difference between the two trial groups, according to a study by Knösel et al, [15] considering the  $\Delta E$  threshold values in the treated group to be  $X=5.65$  and  $S=3.83$  ( $d = 1$ ,  $\alpha$  error = 0.05, and power of study = 85%). Eighteen patients with

79 lesions were selected among those referred to the Restorative and Cosmetic Dentistry Department of Dental School of Mashhad University of Medical Sciences.

**Inclusion criteria:**

- Patients between 14 to 21 years
- Having inactive labial WSLs with a smooth and shiny surface
- For post-orthodontic WSLs, over 3 months had to be passed since bracket removal.

**Exclusion criteria:**

- Active and cavitated lesions
- Deciduous teeth
- Restoration of teeth adjacent to WSLs
- Poor oral hygiene

**Enrollment:**

After explaining the treatment steps and ensuring proper cooperation of the patients, the patients signed informed consent forms and were enrolled.

**Intervention:**

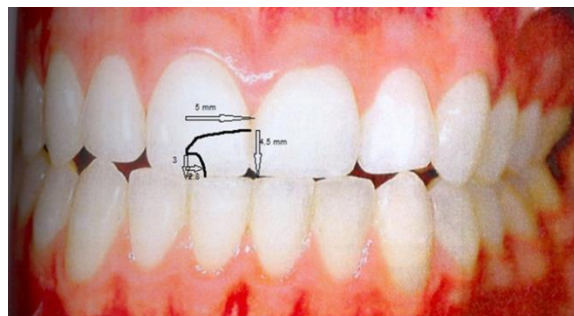
All patients initially received oral hygiene instruction and were asked to use the same toothbrush (Oral B, Classic care, India), dental floss (Oral B, Classic care, India), toothpaste (Colgate Max Fresh Cool Mint Flavor, Thailand), and mouthwash (2% NaF daily) during the treatment course. The patients were instructed to minimize the consumption of colored foods and drinks especially in the first days after treatment.

The teeth were assigned to two groups of localized and generalized lesions. Localized WSLs were defined as lesions involving only part of the buccal surface, allowing color measurement of sound adjacent enamel (to serve as control). Generalized lesions were defined as WSLs involving the entire buccal surface or most of it; therefore, color measurement of the adjacent sound enamel was not possible to serve as control.

Before the procedure, standard photographs were obtained from all samples. A cephalometric head frame was used for standardization, and the camera was placed at a certain distance (30 cm). In order to prevent the effect of moisture on tooth color, the tooth surface was air-dried for 30 seconds. Next, digital photographs were obtained using a Canon camera with a 100 mm lens with shutter

speeds of 1/100, F29, ISO 100, and auto white balance in a room with constant light. Photography was performed by a trained operator before and after treatments and at 1, 3, and 6-month follow-ups. The photographs were analyzed by Photoshop software version 8.

The characteristics of WSLs of each tooth were plotted on a dental chart for each patient by printing a magnified colored image of the lesion and specifying the extent of the lesion and its location for further precise evaluation of the same area (Fig. 1).

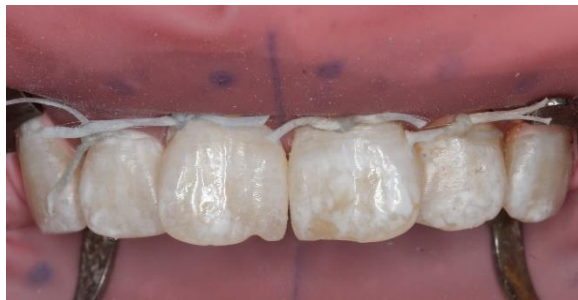

**Fig. 1.** Specifying the extent and location of white spot lesions

The color of teeth was also assessed using an Easy Shade spectrophotometer. First, the Vita Easy Shade spectrophotometer (Vident, Brea, CA, USA) was calibrated by using a calibration plate. All measurements were made under D65 standard conditions. For exact placement of spectrophotometer on WSLs, a piece of wax was placed precisely on the WSL area, and then an initial putty impression was made from the treated arch. Next, a window was created in the mold using a copper ring with the same diameter as the tip of the spectrophotometer (5 mm) over the desired area for color measurements right at the middle of the window. The tooth surface was dried with a sterile gauze. Afterwards, the tip of the spectrophotometer was placed at the window perpendicular to the labial surface of the tooth to measure the color parameters. In localized lesions, the measurements were made for both WSLs and the adjacent sound enamel. The color parameters including  $L^*$ ,  $a^*$ , and  $b^*$  were recorded. In generalized lesions, the assessment of color parameters of the adjacent sound enamel was not possible. Therefore, the  $L^*$ ,  $a^*$ ,

and b\* values before and after treatment were measured to calculate the  $\Delta E$ . Colorimetry was performed twice to minimize measurement errors in all samples, and the mean of the obtained values was calculated and recorded as the colorimetric results.

Next, the patients received protective glasses. The tooth surface was cleaned with a rubber cup, and OpalDam (Ultradent, South Jordan, UT, USA) was placed to isolate the teeth (Fig. 2). Then, resin infiltrant (Icon, DMG, Hamburg, Germany) was applied according to the manufacturer's instructions.

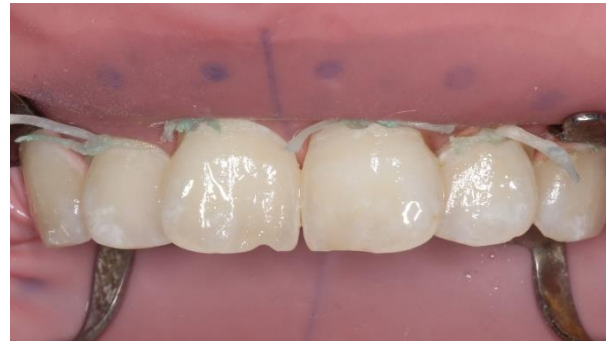

**Fig. 2.** Generalized white spot lesions in maxillary incisors

The teeth were etched by Icon Etch (15% hydrochloric acid) for 2 minutes, rinsed for 30 seconds, and air-dried for 10 seconds. Afterwards, Icon Dry (99% ethanol) was applied for 30 seconds and dried with an air syringe for 10 seconds. Subsequently, Icon Infiltrant was applied on WSLs by a sponge applicator provided in the kit for 3 minutes followed by light-curing by a LED light-curing unit (Elipar S10, 3M ESPE, USA) with a light intensity of 1200 mW/cm<sup>2</sup> for 40 seconds. For standardized application of Icon Etch, Dry, and Infiltrant for each WSL, each syringe screw was rotated by half a turn for each application (Fig. 3). After applying resin, excess resin was removed with a No. 12 scalpel. The patients were asked not to eat colored foods or drinks for up to 24 hours.

**Patient follow-up:**

The patients were followed-up for 1, 3, and 6 months after treatment [15-17]. At each follow-up session, standard photographs were obtained for evaluation in Photoshop software, and colorimetry was also performed by using Easy Shade spectrophotometer.



**Fig. 3.** White spot lesions were masked immediately after resin application

**Evaluation of  $\Delta E$  by Easy Shade spectrophotometer:**

Localized lesions: After measuring the L\*, a\*, and b\* color parameters of WSLs and the control area, the  $\Delta E$  was calculated using the formula below:

$$\Delta E = \sqrt{(\Delta L)^2 + (\Delta a)^2 + (\Delta b)^2}$$

$\Delta E$  was calculated at the aforementioned time points.

Data were statistically analyzed by repeated measures ANOVA. Level of statistical significance was set at P<0.05.

**Generalized lesions:**

Since measurement of color parameters of the adjacent sound dentin was not possible, the L\*, a\*, and b\* color parameters measured before and after treatment were placed in the formula to calculate the  $\Delta E$  caused by the application of ICON (E1). At 1, 3, and 6 months, the color coordinates were measured again and placed in the formula to evaluate the color stability. Accordingly, E2, E3 and, E4 were calculated and analyzed by repeated measures ANOVA.

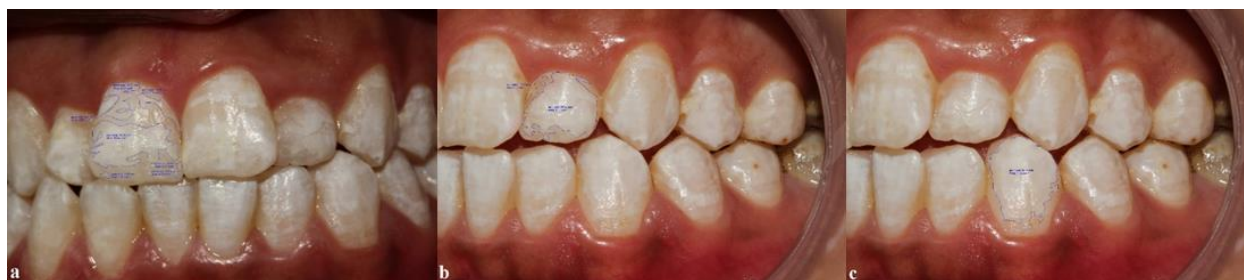**Photographic evaluation:**

In both localized and generalized groups, the L\*, a\*, and b\* values were measured using Photoshop software version 8 and analyzed as explained for the spectrophotometric data.

**Measuring the extent of WSLs:**

The extent of WSLs as the demineralized surface area of the tooth [18] was measured by using MIP4Student software. This software is an image processor software with the full name of "automatic system for detecting and measuring quantitative parameters of metallographic images" (Fig. 4).

Calibration of this software was performed by entering the mean mesiodistal width of each



**Fig. 4a-c:** Measurement of the extent of white spot lesions by using MIP4Student software

tooth that was clinically measured. Afterwards, the relationship between the extent of lesions and the amount of  $\Delta E$  was analyzed by the Pearson's correlation test at 0.05 level of significance.

## RESULTS

Fifty-nine localized lesions of 16 patients were treated (6 males and 10 females). Thirty-seven lesions had been caused by orthodontic treatment, 14 lesions by hypoplasia, and 8 lesions by fluorosis. Two patients (one female and one male, three hypoplastic lesions, and four fluorosis lesions) were lost to follow-up. Therefore, the number of analyzed teeth was reduced to 52 in 14 patients.

The number of treated generalized lesions was 20 in two female patients. These lesions had been caused by fluorosis. The Kolmogorov-Smirnov test showed normal distribution of data.

The results were similar in both techniques for localized and generalized lesions. Tables 1-4 show the mean, standard error, and standard deviation of  $\Delta E$ . Repeated measures ANOVA demonstrated that after resin application, the  $\Delta E$  in both groups at all follow-up times was  $< 3.7$ . There was no significant difference when  $\Delta E$  was compared at different follow-up times ( $P > 0.05$ ). However,  $\Delta E$  differed significantly between the baseline and the follow-up times (1, 3, and 6 months) ( $P < 0.001$ ; Figs. 5-and 6).

**Table 1.** Mean, standard error, and standard deviation of  $\Delta E$  in localized lesions as measured by a spectrophotometer (N=52)

Group	Maximum	Minimum	Mean	Standard error	Standard deviation
E0	21	1.7	5.875 <sup>a</sup>	0.6	4.33
Ea	5.1	0.23	1.8750 <sup>b</sup>	0.18	1.3
E1	4.3	0.23	1.7627 <sup>b</sup>	0.14	1.01
E3	4.3	0.1	1.5131 <sup>b</sup>	0.13	0.98
E6	3	0.1	1.5477 <sup>b</sup>	0.1	0.72

E0: before treatment and sound enamel; Ea: immediately after treatment and sound enamel; E1: one month after treatment and sound enamel; E3: three months after treatment and sound enamel; E6: six months after treatment and sound enamel. The  $\Delta E$  mean values were significantly different between the a and b groups, but were not significantly different within the b group

**Table 2.** Mean, standard error, and standard deviation of  $\Delta E$  in localized lesions (N=52) as measured by Photoshop software

Group	Maximum	Minimum	Mean	Standard error	Standard deviation
EP0	10	1.3	4.3346 <sup>a</sup>	0.27	1.95
EPa	6.7	0.11	2.0535 <sup>b</sup>	0.19	1.43
EP1	5.1	0.12	1.8529 <sup>b</sup>	0.17	1.29
EP3	4	0.11	1.9813 <sup>b</sup>	0.12	0.91
EP6	8.2	0.2	2.3410 <sup>b</sup>	0.26	1.89

EP0: before treatment and sound enamel; EPa: immediately after treatment and sound enamel; EP1: one month after treatment and sound enamel; EP3: three months after treatment and sound enamel; EP6: six months after treatment and sound enamel. The  $\Delta E$  mean values were significantly different between the a and b groups but were not significantly different within the b group.

**Table 3.** Mean, standard error, and standard deviation of  $\Delta E$  in generalized lesions as measured by a spectrophotometer

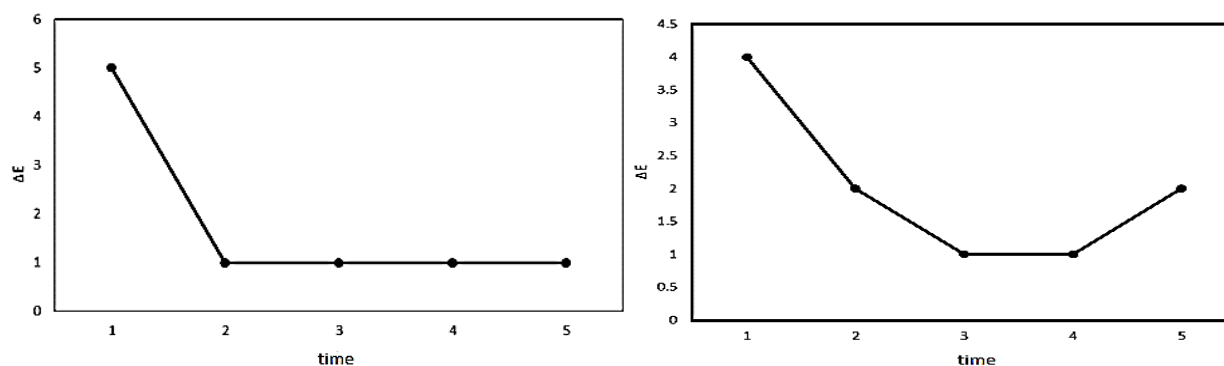
Group	Number	Maximum	Minimum	Mean	Standard error	Standard deviation
EG0	20	9.30	1.10	4.5590 a	0.53290	2.38318
EG1	20	3.40	0.11	1.4590 b	0.20772	0.92896
EG3	20	3.30	0.32	1.4080 b	0.19241	0.86046
EG6	20	3.00	0.12	1.2846 b	0.19660	0.87923

EG0: Before and immediately after treatment; EG1: One month after treatment and immediately after treatment; EG3: Three months after treatment and immediately after treatment; EG6: Six months after treatment and immediately after treatment. The  $\Delta E$  mean values were significantly different between the a and b groups, but were not significantly different within the b group

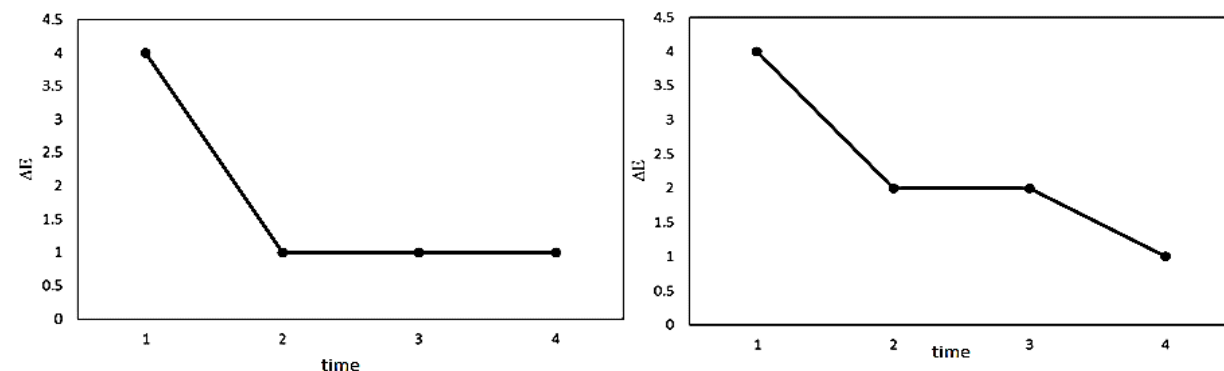
**Table 4.** Mean, standard error, and standard deviation of  $\Delta E$  in generalized lesions as measured by Photoshop software

Group	Number	Maximum	Minimum	Mean	Standard error	Standard deviation
EGP0	20	9.00	1.70	4.3940 a	0.50717	2.26815
EGP1	20	5.10	0.50	2.1200 b	0.27555	1.23232
EGP3	20	5.10	0.23	2.2025 b	0.29373	1.31360
EGP6	20	3.80	0.25	1.9720 b	0.20018	0.89522

EGP0: Before and immediately after treatment; EGP1: One month after treatment and immediately after treatment; EGP3: Three months after treatment and immediately after treatment; EGP6: Six months after treatment and immediately after treatment. The  $\Delta E$  mean values were significantly different between the a and b groups but were not significantly different within the b group.



**Fig. 5.** Left:  $\Delta E$  of localized lesions evaluated by Easy Shade Spectrophotometer. Right:  $\Delta E$  of localized lesions evaluated by Photoshop software



**Fig. 6.** Left:  $\Delta E$  of generalized lesions evaluated by Easy Shade spectrophotometer, Right:  $\Delta E$  of generalized lesions evaluated by Photoshop software

### **Relationship between the extent of WSLs and $\Delta E$ :**

The Pearson's correlation test showed an inverse correlation between the extent of WSLs and  $\Delta E$  ( $P < 0.001$ ). In other words, larger (generalized) WSLs showed lower color improvement ( $\Delta E$ ).

## **DISCUSSION**

This study assessed the effect of extent of WSLs on the esthetic outcome (masking effect and durability) for 6 months after treatment by the resin infiltration technique using spectrophotometry and digital photography. The results showed significant color correction during the follow-up period and an inverse correlation between the extent of WSLs and  $\Delta E$ ; therefore, both hypotheses were rejected.

The present results were in agreement with the finding of Senestraro et al, [19] who used Image J software to measure the extent of lesions and compared them during the follow-up period. Torres and Borges [20] and Neuhaus et al. [21] demonstrated an inverse correlation between the depth of WSLs and improvement of the esthetic appearance of lesions by the resin infiltration technique. Resin can be infiltrated to the depth of 620  $\mu\text{m}$ ; if the lesion depth exceeds 620  $\mu\text{m}$ , less esthetic improvement would occur [21]. The depth of resin penetration in the resin infiltration technique highly depends on the depth and morphology of the lesions, especially in traumatic hypomineralization discoloration. In cases with round lesions with an acute angle with the enamel surface, resin penetration at the margins is often impaired, causing the edges to show, known as the edge effect. This phenomenon occurs because hydrochloric acid leads to more resin penetration into the central parts of the lesions. In WSLs due to fluorosis and caries, the angle formed between the lesion and the enamel surface is obtuse, allowing more resin to penetrate [22].

This study showed the stability of improved esthetic results during the six-month follow-up, which was in line with previous studies on fluorosis, post-orthodontic WSLs, and enamel

developmental defects with follow-up times from 6 to 45 months [23-25]. However, the results of some in vitro studies were in contrast to the present findings. In these in vitro studies, the samples were immersed entirely in coffee or wine [26, 27], while in the present study, the patients were instructed not to consume colored foods and drinks as much as possible, especially in the first days after ICON application.

In several studies,  $\Delta E \leq 3.7$  is considered as clinically acceptable color difference. However, when this value is higher than 1, it can be observable by the laypeople in 50% of the cases. From this viewpoint, the current results demonstrated that the resin infiltration technique was relatively successful in esthetic improvement of WSLs because the  $\Delta E$  values in both groups were higher than 1. Although all lesions were not masked completely, all patients were satisfied with the esthetic results of resin infiltration. The same results were reported about patient satisfaction by Youssef et al [12].

Applying remineralizing agents such as fluoride or CCP-ACP is the most common method used to treat WSLs. It should be noted that remineralization of incipient caries by the afore-mentioned agents is superficial, and the body of lesions still remains decalcified [28]. Therefore, the refraction rate of light in the body part of WSLs is different from that in the intact enamel, and the esthetic appearance of WSLs does not improve. However, caries progression may stop or decelerate, and the depth and width of lesions may decrease [29]. Resin infiltration stops the progression of enamel lesions and improves the esthetic appearance of WSLs on the labial surface of the teeth [13]. Meyer-Lueckel and Paris [8], and Paris and Meyer-Lueckel [30] highlighted the cariostatic effects of resin infiltration. Compared to the remineralization techniques which require several follow-up sessions, resin infiltration treatment is completed within one session, which is favorable for patients [12].

The micro-abrasion techniques and conservative composite restorations are

other approaches for management of WSLs; however, the resin infiltration technique is far less invasive than these techniques [31]. In the resin infiltration technique, only 30 to 40  $\mu\text{m}$  of enamel is eroded by etching with hydrochloric acid [31], compared to 630  $\mu\text{m}$  of erosion in the micro-abrasion technique [32]. Also, teeth infiltrated with resin indicate lower roughness values and complete sealing of the porosities compared with micro-abraded teeth [33]. It has been mentioned that the resin infiltration technique brings about better esthetic results than the micro-abrasion technique after 12 months of follow-up [34].

The topographic characteristics of caries-induced WSLs are similar to mild and moderate fluorosis-induced hypomineralization, traumatic hypomineralization, and molar-incisor hypomineralization; thus, the resin infiltration treatment has been suggested for the above-mentioned cases [35, 36]. Gencer and Kirzioğlu [37] evaluated resin infiltration, and application of tricalcium phosphate, and CPP-ACP on micro-abraded teeth with fluorosis and hypomineralization and reported that resin infiltration yielded the most favorable results in all cases, especially fluorosis cases.

One disadvantage of resin infiltration is the possibility of staining of the area. Restorative resins are prone to pigmentation due to internal and external factors over time. Pigmentation, bond degradation, and material wear depend on the water sorption rate of the material, degree of conversion of monomers, and the adopted surface polishing technique [38].

Plaque accumulation with subsequent pigmentation causes the penetration of stains into the resin [39]. Icon infiltrant is a light-cure resin mainly consisting of TEGDMA, which is susceptible to accelerated aging [40]. According to Sideridou et al, [41] TEGDMA is a monomer with the highest water sorption capacity. BIS-GMA and UDMA rank next. However, Rey et al. [42] showed that ICON has the least potential for discoloration compared with other adhesives.

Application of an adhesive system for

composite restoration is another concern. It does not weaken the resin bond and increases the adhesion of self-etching agents [43]. It also has a protective effect against demineralization [44]. Furthermore, both self-etch and etch-and-rinse adhesive systems can be used for future composite restoration in resin infiltrated enamel [45]. Also, Simunovic Anicic et al. [46] evaluated the effect of resin infiltration pretreatment on orthodontic bonding, and showed that resin infiltration technique did not decrease the shear bond strength of orthodontic brackets. In the present study, several post-orthodontic WSLs were evaluated in patients that over 3 months had passed since their bracket removal. The time period of 3 months was selected because the WSLs often decrease in size and number from a few weeks to 3 months following bracket removal in case of strict adherence to oral hygiene measures [47].

To measure the color change caused by resin infiltration treatments, a reproducible and reliable instrument for colorimetry is required. According to Browning [48] spectrophotometer is the most accurate instrument for colorimetry. Therefore, Vita Easy Shade compact spectrophotometer was used in the current study, which is a small, cordless, battery-powered, affordable portable spectrophotometer [49]. This device is extensively used to evaluate color change and improvement in esthetic appearance of the teeth [17]. Easy Shade spectrophotometer requires precise measuring to reduce errors during its operation. Tooth surface convexity and teeth with higher translucency may affect the accuracy of spectrophotometry [50]. Hence, two measurements were made for each tooth in the present study, and the mean values were calculated and reported.

Standardized clinical photography is a simple and valid method for quantitative assessment of the extent and color of lesions. According to Edward Benson et al, [51] photography is an objectively (visually) reproducible, reliable, and accurate method. Photography is commonly used for assessment of color



change [12, 23, 24]. Therefore, in the current study, this method was used under standard conditions for color evaluation. The results obtained from Easy Shade spectrophotometer and photography were similar.

One limitation of this study was short duration of follow-up. Longer follow-up periods would yield more reliable results regarding the durability of treatment results. Also, the response of WSLs to this treatment may be different according to their various etiologies (orthodontic treatment, trauma, caries, etc.). Thus, separate evaluation of lesions based on their etiology is recommended in future studies. Another notable point is that patients' diet can affect the level of staining of lesions. Although patients were asked not to consume colored foods and drinks in the first days of treatment, it was not possible to standardize the diet of patients or monitor their compliance. Further studies are recommended on deeper lesions with longer duration of erosion, and more frequent use of resin infiltration with longer follow-ups to study the aging phenomenon considering the hydrophilicity of TEGDMA monomer.

## CONCLUSION

The resin infiltration technique improved the esthetic appearance of demineralized teeth with sufficient durability for 6 months. Furthermore, there was an inverse correlation between the extent of lesions and the level of their esthetic improvement.

## ACKNOWLEDGMENT

The article grant number is 930116, carried out at the Dental School of Mashhad University of Medical Sciences, Iran, under the advisory guidance of Dr. Boruziniat. The authors would like to extend their gratitude to the Vice-Chancellor of Research of Mashhad University of Medical Sciences for providing financial support for this project.

## CONFLICT OF INTEREST STATEMENT

None declared.

## REFERENCES

- Ritter AV, Boushell LW, Walter R. Sturdevant's art and science of operative dentistry-e-book. 7th edition; Elsevier Health Sciences; 2019; Chapter 2:p62.
- Stoll R, Urban-Klein B, Giacomini P, Loukas A, Jablonski-Momeni A. In vivo assessment of caries excavation with a fluorescence camera compared to direct bacteriological sampling and quantitative analysis using flow cytometry. *Lasers Med Sci.* 2015 Feb;30(2):843-9.
- Heymann GC, Grauer D. A contemporary review of white spot lesions in orthodontics. *J Esthet Restor Dent.* 2013 Apr;25(2):85-95.
- Perdigão J. Resin infiltration of enamel white spot lesions: An ultramorphological analysis. *J Esthet Restor Dent.* 2020 Apr;32(3):317-324.
- Sampson V, Sampson A. Diagnosis and treatment options for anterior white spot lesions. *Br Dent J.* 2020 Sep;229(6):348-352.
- Knösel M, Attin R, Becker K, Attin T. External bleaching effect on the color and luminosity of inactive white-spot lesions after fixed orthodontic appliances. *Angle Orthod.* 2007 Jul;77(4):646-52.
- Tufekci E, Dixon JS, Gunsolley JC, Lindauer SJ. Prevalence of white spot lesions during orthodontic treatment with fixed appliances. *Angle Orthod.* 2011 Mar;81(2):206-10.
- Meyer-Lueckel H, Paris S. Progression of artificial enamel caries lesions after infiltration with experimental light curing resins. *Caries Res.* 2008;42(2):117-24.
- Kim S, Kim EY, Jeong TS, Kim JW. The evaluation of resin infiltration for masking labial enamel white spot lesions. *Int J Paediatr Dent.* 2011 Jul;21(4):241-8.
- Borges AB, Caneppele TM, Masterson D, Maia LC. Is resin infiltration an effective esthetic treatment for enamel development defects and white spot lesions? A systematic review. *J Dent.* 2017 Jan;56:11-18.
- Kielbassa AM, Muller J, Gernhardt CR. Closing the gap between oral hygiene and minimally invasive dentistry: a review on the resin infiltration technique of incipient (proximal) enamel lesions. *Quintessence Int.* 2009 Sep;40(8):663-81.
- Youssef A, Farid M, Zayed M, Lynch E, Alam MK, Kielbassa AM. Improving oral health: a short-term split-mouth randomized clinical trial revealing the superiority of resin infiltration over remineralization of white spot lesions. *Quintessence Int.* 2020;51(9):696-709.

13. Rocha Gomes Torres C, Borges AB, Torres LM, Gomes IS, de Oliveira RS. Effect of caries infiltration technique and fluoride therapy on the colour masking of white spot lesions. *J Dent.* 2011 Mar;39(3):202-7.
14. Yuan H, Li J, Chen L, Cheng L, Cannon RD, Mei L. Esthetic comparison of white-spot lesion treatment modalities using spectrometry and fluorescence. *Angle Orthod.* 2014 Mar;84(2):343-9.
15. Knösel M, Eckstein A, Helms HJ. Durability of esthetic improvement following Icon resin infiltration of multibracket-induced white spot lesions compared with no therapy over 6 months: a single-center, split-mouth, randomized clinical trial. *Am J Orthod Dentofacial Orthop.* 2013 Jul;144(1):86-96.
16. Hammad SM, El-Wassefy NA, Alsayed MA. Evaluation of color changes of white spot lesions treated with three different treatment approaches: an in-vitro study. *Dental Press J Orthod.* 2020 Jan-Feb;25(1):26-27.
17. Kannan A, Padmanabhan S. Comparative evaluation of Icon® resin infiltration and Clinpro™ XT varnish on colour and fluorescence changes of white spot lesions: a randomized controlled trial. *Prog Orthod.* 2019 Jun 17;20(1):23.
18. Knösel M, Bojes M, Jung K, Ziebolz D. Increased susceptibility for white spot lesions by surplus orthodontic etching exceeding bracket base area. *Am J Orthod Dentofacial Orthop.* 2012 May;141(5):574-82.
19. Senestraro SV, Crowe JJ, Wang M, Vo A, Huang G, Ferracane J, et al. Minimally invasive resin infiltration of arrested white-spot lesions: a randomized clinical trial. *J Am Dent Assoc.* 2013 Sep;144(9):997-1005.
20. Torres CR, Borges AB. Color masking of developmental enamel defects: a case series. *Oper Dent.* 2015 Jan-Feb;40(1):25-33.
21. Neuhaus KW, Schlafer S, Lussi A, Nyvad B. Infiltration of natural caries lesions in relation to their activity status and acid pretreatment in vitro. *Caries Res.* 2013;47(3):203-10.
22. Denis M, Atlan A, Vennat E, Tirlet G, Attal JP. White defects on enamel: diagnosis and anatomopathology: two essential factors for proper treatment (part 1). *Int Orthod.* 2013 Jun;11(2):139-65. English, French.
23. Garg SA, Chavda SM. Color Masking White Fluorotic Spots by Resin Infiltration and Its Quantitation by Computerized Photographic Analysis: A 12-month Follow-up Study. *Oper Dent.* 2020 Jan/Feb;45(1):1-9.
24. STRY RD. Quantitative evaluation of masking effect of resin infiltration on developmental defects of enamel. *Quintessence Int.* 2020 Jun;51(6):448.
25. Knösel M, Eckstein A, Helms HJ. Long-term follow-up of camouflage effects following resin infiltration of post orthodontic white-spot lesions in vivo. *Angle Orthod.* 2019 Jan;89(1):33-39.
26. Borges A, Caneppele T, Luz M, Pucci C, Torres C. Color stability of resin used for caries infiltration after exposure to different staining solutions. *Oper Dent.* 2014 Jul-Aug;39(4):433-40.
27. Cohen-Carneiro F, Pascareli AM, Christino MR, Vale HF, Pontes DG. Color stability of carious incipient lesions located in enamel and treated with resin infiltration or remineralization. *Int J Paediatr Dent.* 2014 Jul;24(4):277-85.
28. Anderson P, Elliott JC. Rates of mineral loss in human enamel during in vitro demineralization perpendicular and parallel to the natural surface. *Caries Res.* 2000 Jan-Feb;34(1):33-40.
29. Jones RS, Fried D. Remineralization of enamel caries can decrease optical reflectivity. *J Dent Res.* 2006 Sep;85(9):804-8.
30. Paris S, Meyer-Lueckel H. Inhibition of caries progression by resin infiltration in situ. *Caries Res.* 2010;44(1):47-54.
31. Meyer-Lueckel H, Paris S, Kielbassa AM. Surface layer erosion of natural caries lesions with phosphoric and hydrochloric acid gels in preparation for resin infiltration. *Caries Res.* 2007;41(3):223-30.
32. Tong LS, Pang MK, Mok NY, King NM, Wei SH. The effects of etching, micro-abrasion, and bleaching on surface enamel. *J Dent Res.* 1993 Jan;72(1):67-71.
33. Yazkan B, Ermis RB. Effect of resin infiltration and microabrasion on the microhardness, surface roughness and morphology of incipient carious lesions. *Acta Odontol Scand.* 2018 Oct;76(7):473-481.
34. Gu X, Yang L, Yang D, Gao Y, Duan X, Zhu X, et al. Esthetic improvements of postorthodontic white-spot lesions treated with resin infiltration and microabrasion: A split-mouth, randomized clinical trial. *Angle Orthod.* 2019 May;89(3):372-377.
35. Muñoz MA, Arana-Gordillo LA, Gomes GM, Gomes OM, Bombarda NH, Reis A, et al. Alternative esthetic management of fluorosis and hypoplasia stains: blending effect obtained with resin infiltration techniques. *J Esthet Restor Dent.* 2013 Feb;25(1):32-9.
36. Shahroom NSB, Mani G, Ramakrishnan M. Interventions in management of dental fluorosis, an endemic disease: A systematic review. *J Family Med Prim Care.* 2019 Oct 31;8(10):3108-3113.

37. Gençer MDG, Kirzioglu Z. A comparison of the effectiveness of resin infiltration and microabrasion treatments applied to developmental enamel defects in color masking. *Dent Mater J*. 2019 Mar 31;38(2):295-302.
38. Ertaş E, Güler AU, Yücel AC, Köprülü H, Güler E. Color stability of resin composites after immersion in different drinks. *Dent Mater J*. 2006 Jun;25(2):371-6.
39. Nasim I, Neelakantan P, Sujeer R, Subbarao CV. Color stability of microfilled, microhybrid and nanocomposite resins--an in vitro study. *J Dent*. 2010;38 Suppl 2:e137-42.
40. Chen M, Li JZ, Zuo QL, Liu C, Jiang H, Du MQ. Accelerated aging effects on color, microhardness and microstructure of ICON resin infiltration. *Eur Rev Med Pharmacol Sci*. 2019 Sep;23(18):7722-7731.
41. Sideridou I, Tserki V, Papanastasiou G. Study of water sorption, solubility and modulus of elasticity of light-cured dimethacrylate-based dental resins. *Biomaterials*. 2003 Feb;24(4):655-65.
42. Rey N, Benbachir N, Bortolotto T, Krejci I. Evaluation of the staining potential of a caries infiltrant in comparison to other products. *Dent Mater J*. 2014;33(1):86-91.
43. Jia L, Stawarczyk B, Schmidlin PR, Attin T, Wiegand A. Effect of caries infiltrant application on shear bond strength of different adhesive systems to sound and demineralized enamel. *J Adhes Dent*. 2012 Dec;14(6):569-74.
44. Yetkiner E, Wegehaupt FJ, Attin R, Attin T. Caries infiltrant combined with conventional adhesives for sealing sound enamel in vitro. *Angle Orthod*. 2013 Sep;83(5):858-63.
45. Borges AB, Abu Hasna A, Matuda AGN, Lopes SR, Mafetano APVP, Arantes A, et al. Adhesive systems effect over bond strength of resin-infiltrated and de/remineralized enamel. *F1000Res*. 2019 Oct 11;8:1743.
46. Simunovic Anicic M, Goracci C, Juloski J, Miletic I, Mestrovic S. The influence of resin infiltration pretreatment on orthodontic bonding to demineralized human enamel. *Appl. Sci*. 2020 May 23;10(10):3619.
47. Artun J, Thylstrup A. A 3-year clinical and SEM study of surface changes of carious enamel lesions after inactivation. *Am J Orthod Dentofacial Orthop*. 1989 Apr;95(4):327-33.
48. Browning WD. Use of shade guides for color measurement in tooth-bleaching studies. *J Esthet Restor Dent*. 2003;15 Suppl 1:S13-20.
49. Chu SJ, Trushkowsky RD, Paravina RD. Dental color matching instruments and systems. Review of clinical and research aspects. *J Dent*. 2010;38 Suppl 2:e2-16.
50. van der Burgt TP, ten Bosch JJ, Borsboom PC, Kortsmid WJ. A comparison of new and conventional methods for quantification of tooth color. *J Prosthet Dent*. 1990 Feb;63(2):155-62.
51. Benson PE, Shah AA, Willmot DR. Measurement of white lesions surrounding orthodontic brackets: captured slides vs digital camera images. *Angle Orthod*. 2005 Mar;75(2):226-30.