



# Comparative Antifungal Efficacy of Curcumin Plus Nystatin Versus Nystatin Monotherapy for Treatment of Denture Stomatitis: A Clinical Trial

Haniye Meftahpour<sup>1</sup>, Simin Leasan<sup>2\*</sup>, Zahra Jafariazar<sup>3</sup>, Taraneh Farrokhnia<sup>2</sup>

1. Private practice, Tehran, Iran

2. Oral Medicine Department, Faculty of Dentistry, Tehran Medical Sciences, Islamic Azad University, Tehran, Iran

3. Department of Pharmaceutics, Pharmacy, Pharmaceutical Sciences Branch, Islamic Azad University, Tehran, Iran

Article Info	ABSTRACT
<p><b>Article type:</b> Original Article</p>	<p><b>Objectives:</b> This study compared the antifungal efficacy of curcumin plus nystatin versus nystatin monotherapy for treatment of denture stomatitis.</p> <p><b>Materials and Methods:</b> This single-blind clinical trial evaluated 32 patients with types II and III denture stomatitis. Microbial samples were collected from the patients' palate to count the <i>Candida albicans</i> (<i>C. albicans</i>) colonies. Erythema of the palate was quantified by measuring the surface area of the erythematous sites. The patients were randomly assigned to two groups (n=16). The control group received nystatin suspension while the test group received a curcumin mouthwash plus nystatin suspension. The number of <i>C. albicans</i> colony forming units (CFUs) and the surface area of the erythematous sites were calculated again after 14 days. Data were analyzed using t-test and Wilcoxon signed-rank test (alpha=0.05).</p>
<p><b>Article History:</b> Received: 25 Jan 2023 Accepted: 01 Jul 2024 Published: 15 Feb 2025</p>	<p><b>Results:</b> Both groups experienced a significant reduction in <i>C. albicans</i> colony count after the intervention (P&lt;0.001). There was no significant difference in reduction of colony count between the two groups (P=0.341). Both groups experienced a significant reduction in the size of erythema (P=0.001 for the nystatin and P&lt;0.001 for the nystatin plus curcumin). The two groups were not significantly different regarding the size of erythema at baseline (P=0.956) or after the intervention (P=0.491).</p> <p><b>Conclusion:</b> Addition of curcumin to nystatin suspension did not add any significant advantage with regard to reduction of <i>C. albicans</i> colony count or erythema of the palate, and both interventions were equally effective.</p>
<p><b>* Corresponding author:</b> Oral Medicine Department, Faculty of Dentistry, Tehran Medical Sciences, Islamic Azad University, Tehran, Iran Email: <a href="mailto:siminlesan@yahoo.com">siminlesan@yahoo.com</a></p>	<p><b>Keywords:</b> <i>Candida albicans</i>; Curcumin; Erythema; Nystatin; Stomatitis, Denture</p> <p>➤ <b>Cite this article as:</b> Meftahpour H, Leasan S, Jafariazar Z, Farrokhnia T. Comparative Antifungal Efficacy of Curcumin Plus Nystatin Versus Nystatin Monotherapy for Treatment of Denture Stomatitis: A Clinical Trial. <i>Front Dent.</i> 2025;22:08.</p>

## INTRODUCTION

Oral candidiasis is the most common opportunistic infection of the oral cavity caused by *Candida albicans* (*C. albicans*) [1]. *C. albicans*, as a member of the normal oral flora, has a mean prevalence rate of 35%, and can become pathogenic under certain circumstances. A direct correlation has been reported between oral candidiasis and the effect of local predisposing factors (such as the use of

denture, smoking, use of steroid inhalators, or topical application of steroids) and systemic factors (such as the immune system status and endocrine status) [1]. These parameters may play a role in the pathogenic transformation of *C. albicans* [1].

*Candida*-containing biofilms have a role in development of denture stomatitis. Denture stomatitis is the most common and most important clinical condition developed in

denture wearers [2]. It is an inflammatory disease, and the palatal mucosa is the most common site of involvement [3]. Approximately 15% to 70% of denture wearers are affected by denture stomatitis [4]. Denture stomatitis has a multifactorial etiology. Long-term use of denture and poor denture hygiene [3] are the most important risk factors for colonization of *Candida* species on denture-bearing mucosa and development of oral candidiasis, which is affected by a number of endogenous and exogenous factors [5]. *C. albicans* is capable of penetrating into the resin structure and creating a microbial reservoir [4]. According to the Newton's criteria, denture stomatitis is classified into three types: (I) small localized erythematous areas or pinpoint hyperemia, (II) generalized simple inflammation of the mucosa under the denture base, and (III) inflammatory papillary hyperplasia of the palate in addition to the clinical manifestations of type II [6].

At present, use of antifungal agents is the first-line treatment for denture stomatitis. However, intake of antifungal medications is associated with some side effects and high recurrence rate [2]. The commonly used antifungal agents belong to the family of azoles or polyenes. Polyenes such as nystatin are the first-choice medications for treatment of primary oral candidiasis [2]. However, nystatin has side effects such as a bitter taste, non-acceptance by patients, mucosal irritation, and nausea [7].

Nowadays, there is a growing interest in alternative medicine and medicinal herbs [8,9]. Use of medicinal herbs has gained increasing popularity worldwide due to their low cost, availability, insignificant side effects, optimal effect on drug-resistant species, and high efficacy [10]. Scientific evidence has confirmed the optimal anti-inflammatory and antifungal properties of turmeric, and particularly curcumin, as its main constituent. Several mechanisms have been suggested for such effects of curcumin [11]. Turmeric and curcumin have been widely used for treatment of many conditions [12]. The antibacterial, antiviral, antifungal, and antimalarial activities of curcumin have been previously reported [13]. It can also inhibit the proliferation of *C. albicans*

[14-16]. Curcumin can reduce the metabolic activity of *C. albicans* biofilm as well [17].

Denture stomatitis is a refractory and recurrent inflammatory condition that occurs as the result of host immune response to trauma, or chemical or microbial damage that causes vasodilation, increases the microvascular permeability, and causes tissue edema. Curcumin may be able to decrease erythema due to its anti-inflammatory activity [6,18]. Also, the antifungal effect of curcumin on *C. albicans* has been previously documented in many studies [14-16]. However, some others failed to show significant inhibitory effect of curcumin on *C. albicans* [19]. Considering the controversy in the results of studies on this topic, and lack of studies comparing the antifungal efficacy of curcumin with synthetic antifungal agents, this study aimed to compare the antifungal efficacy of curcumin plus nystatin versus nystatin monotherapy for treatment of types II and III denture stomatitis.

## MATERIALS AND METHODS

This single-blind clinical trial was conducted on denture wearers at the Faculty of Dentistry, Tehran Islamic Azad University in 2019 and 2020. The study protocol was approved by the ethics committee of the university (IR.IAU.DENTAL.REC.1399.007), and registered in the Iranian Registry of Clinical Trials (IRCT20200519047516N1). The criteria used for reporting the results were derived from the Consolidated Standards of Reporting Trials.

A total of 32 eligible patients were selected by convenience sampling, and signed consent forms prior to participation in the study. The sample size was calculated to be 16 in each group according to a study by Amanlou et al, [20] assuming  $\alpha=0.05$ ,  $\beta=0.2$ , and standard deviation of the mean to be 0.475 to detect a 0.5-unit significant difference between the two groups.

The patients were randomly divided into two groups by the stratified block randomization method (some patients had type II and some had type III denture stomatitis based on the Newton's classification of denture stomatitis)

[6]. For this purpose, 32 envelopes were randomly distributed among the test and control group participants. Each envelope contained a piece of paper that indicated the group allocation of each patient (test or control). The examiners who evaluated the results after the treatment were not aware of the group allocation of patients. Thus, the study had a single-blind design.

The inclusion criteria for this study were denture wearers over 18 years with type II or III denture stomatitis. The lesions and their type were diagnosed by a post-graduate student of oral medicine and confirmed by an oral medicine specialist; finally, the diagnosis of the lesions was verified by counting the *C. albicans* colony forming units per milliliter (CFUs/mL). The exclusion criteria were allergy to curcumin, pregnancy and nursing, immunocompromised patients, chemotherapy or radiotherapy, and intake of antibiotics or antifungal agents in the past 4 weeks [14].

After patient selection, they were asked about the duration of using removable denture, method of cleaning it (water, toothbrush, cleansing agents), frequency of cleaning the denture (never, once a week, twice a week, thrice a week, more than thrice a week), and removing the denture before sleeping at night. Next, the patients underwent oral examination to determine the presence/absence of erythema on their palate. For this purpose, the patients' palate was photographed, and the surface area of the erythematous region was calculated and reported in square millimeters (mm<sup>2</sup>) using Adobe Photoshop Middle Eastern version 8.0 (Adobe Systems Inc.,). Eventually, the patients were asked to rinse their mouth with water and then a microbial sample was collected from the palate of patients by using a sterile swab. The number of *C. albicans* colonies in the collected samples was counted and recorded as colony forming units per milliliter (CFUs/mL) [14]. Next, the patients were randomly divided into two groups (n=16).

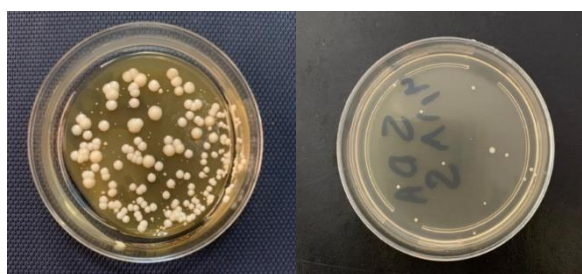
In group 1, the patients were asked to rinse their mouth with a nystatin suspension (100,000 units; Emad Iran, Iran) 4 times a day, 40 drops each time, for 5 minutes as a mouthwash for a period of 2 weeks [21].

In group 2, the patients were asked to rinse their mouth with 40 drops of a curcumin mouthwash (synthesized at the School of Pharmacy of Islamic Azad University) along with 40 drops of a nystatin suspension 4 times a day, each time for 5 minutes, for a period of 2 weeks [14].

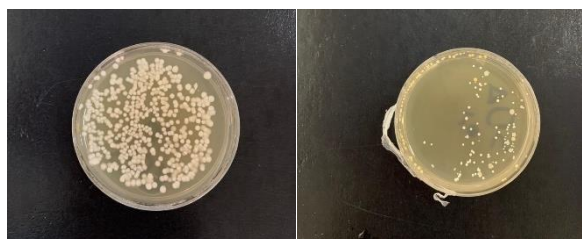The formulation of the curcumin mouthwash was adopted from the studies by Mustafa et al, [14] and Sahlan et al, [21] using propylene glycol for solubilization of curcumin. After determining the concentration of the active substance to be 0.5mg/mL, the mouthwash was prepared under the supervision of a pharmacist. To prepare the solvent, 25g of propyl paraben and 9g of methyl paraben were weighed and added to 20mL of propylene glycol, 5.7mL of sorbitol, 3cc of Tween80, and 3 drops of 10% sodium hydroxide. Distilled water was used to reach the desired volume [14, 21]. The curcumin powder was added to the solvent and stirred on a magnetic stirrer until a clear homogenous suspension was obtained.

The patients were instructed to remove their denture prior to using the mouthwash, rinse their mouth with water, and then rinse their mouth with the mouthwash. They were also requested to only use their denture during the day and remove it at night. Also, the patients received instructions on how to clean their denture after meals (with a soft toothbrush and no toothpaste), and to take it out at night and store it in water [14,22]. They were requested not to immerse their denture in chlorhexidine (since chlorhexidine would interfere with nystatin) [23].

At the end of day 14, the patients were examined again. Microbial samples were collected again from the palate of the patients by sterile swabs, and presence/absence of erythema and its size were also recorded as described earlier. The number of *C. albicans* colonies was also counted. For this purpose, the microbial samples were streak-cultured on the Sabouraud dextrose agar culture medium near the flame and were transferred to a microbiology laboratory within 30 minutes where they were incubated at 37°C for 24 hours. The number of *C. albicans* colonies was then counted (Figs 1 and 2) [24].



**Fig 1.** Number of *C. albicans* CFUs before (left) and 2 weeks after (right) the treatment with nystatin



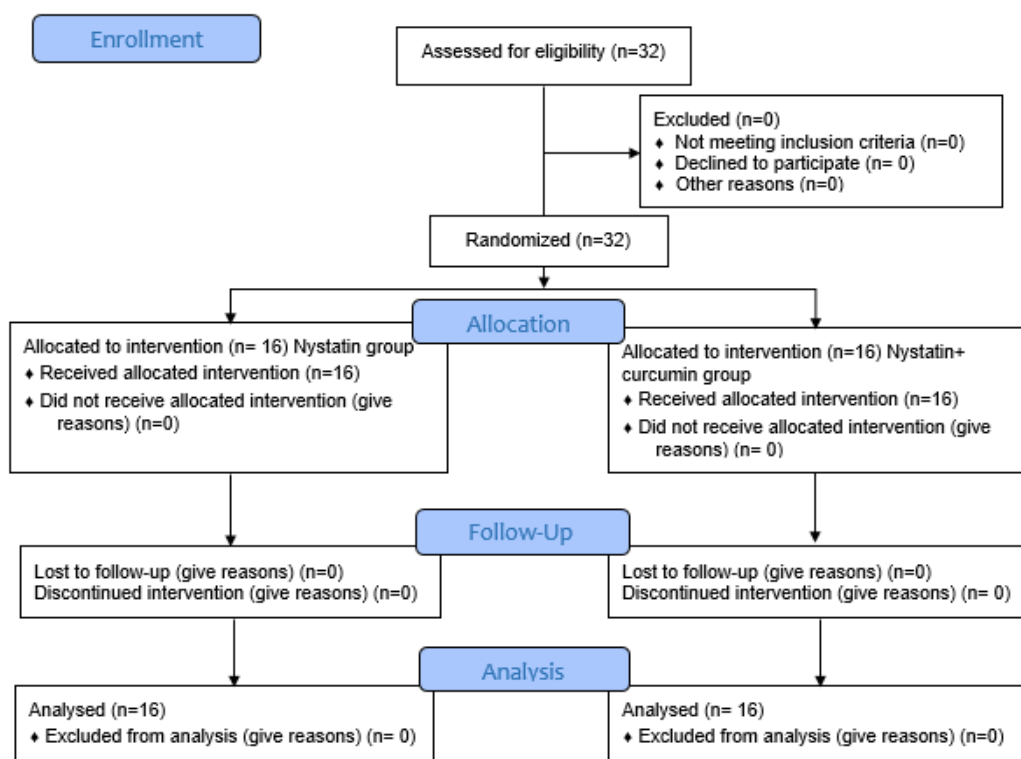
**Fig 2.** Number of *C. albicans* CFUs before (left) and 2 weeks after (right) the treatment with nystatin plus curcumin

**Statistical analysis:**

Within-group and between-group comparisons of colony count were performed by t-test with type of intervention as the between-subject factor. Changes in erythema after the intervention compared with baseline were analyzed by the Wilcoxon signed-rank test by considering the method of intervention as the between-subject factor. All statistical analyses were performed at 0.05 level of significance.

**RESULTS**

A total of 32 patients including 6 females (18.75%) and 26 males (81.25%) participated in this study. There were 2 females and 14 males with a mean age of 57.69±15.23 years (range 35 to 79 years) in the nystatin plus curcumin group, and 4 females and 12 males with a mean age of 58.63±12.90 years (range 39 to 81 years) in the nystatin group. Figure 3 shows the flow-diagram of the study.



**Fig 3.** Flow diagram of the study

Table 1 shows the demographic and other characteristics of patients in the two groups. No patients were harmed during the study.

**Table 1.** Demographic and other characteristics of patients in the two groups

Parameter	Group	
	Nystatin+ curcumin	Nystatin
<b>Age(yrs.)</b>		
Mean± SD	57.69±15.23	58.63±12.90
Median (range)	38-82	37-67
<b>Gender</b>		
Female	2 (12.5%)	4 (25%)
Male	14 (87.5%)	12 (75%)
<b>Denture stomatitis type</b>		
II	14(87.5 %)	14 (87.5 %)
III	2 (12.5 %)	2 (12.5 %)
<b>Duration of use</b>		
<5 (yrs.)	2(12.5%)	4(25%)
>5 (yrs.)	14(87.5%)	12(75%)
<b>Cleaning method</b>		
Water	7(43.8%)	6(37.5%)
Toothbrush	6(37.5%)	6(37.5%)
Cleaning agent	3(18.8%)	4(25%)
<b>Frequency of cleaning</b>		
None	0(0%)	0(0%)
Once/week	2(12.5%)	2(12.5%)
Twice/week	3(18.8%)	3(18.8%)
Thrice/week	3(18.8%)	5(31.3%)
>thrice/week	8(50%)	6(37.5%)
<b>Nocturnal denture use</b>		
No	3(18.8%)	2(12.5%)
Yes	13(81.3%)	14(87.5%)

SD: Standard deviation

As shown in Table 2, the two groups were compared regarding the *C. albicans* colony count before (baseline) and after the treatment (day 14) and also for the reduction in colony count after the treatment. The results showed that both nystatin and nystatin plus curcumin were equally effective and significantly decreased the *C. albicans* colony count after the intervention with no significant difference between them ( $P<0.001$ ). The two groups were not significantly different regarding the colony count at baseline ( $P=0.632$ ) or after the intervention ( $P=0.463$ ), and the difference in

colony count reduction was not significant between the two groups either ( $P=0.341$ ).

**Table 2.** Colony count (CFUs/mL) before and after the treatment in the two groups

Colony count (CFUs/mL)	Groups		P
	Nystatin+ curcumin	Nystatin	
<b>Before</b>			0.632
Min	30	55	
Max	330	410	
Mean± SD	163.13± 99.14	181.25± 112.16	
<b>After</b>			0.463
Min	0	8	
Max	54	145	
Mean± SD	27.88± 17.35	30.06± 40.49	
<b>Reduction</b>			0.341
Min	58.3	73.3	
Max	95.3	100	
Mean± SD	84.04± 7.59	80.2922± 13.52	
<b>P</b>	<0.001	<0.001	-

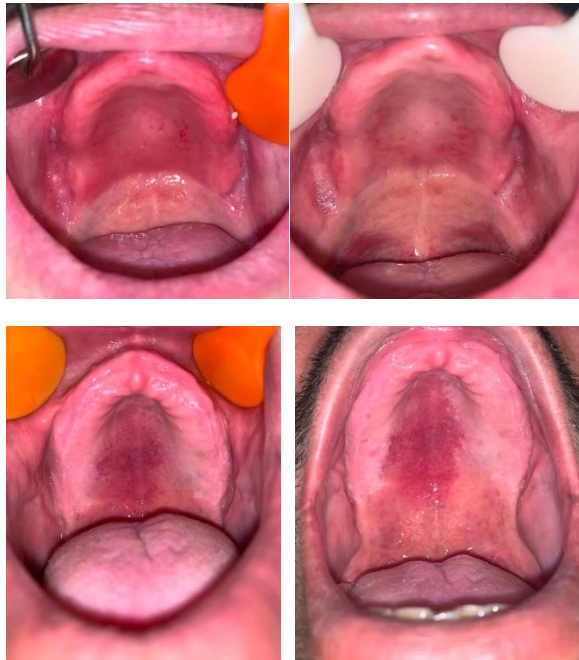
CFU: Colony forming unit, Min: Minimum, Max: Maximum, SD: Standard deviation

As shown in Table 3, both nystatin ( $P=0.001$ ) and nystatin plus curcumin ( $P<0.001$ ) significantly decreased the size of erythema of the palate after 14 days. However, the two groups were not significantly different regarding the size of erythema at baseline ( $P=0.956$ ) or after the intervention ( $P=0.491$ ).

**Table 3.** Erythema before and after the intervention in the two groups (mm<sup>2</sup>)

Time	Groups		P
	Nystatin + curcumin	Nystatin	
<b>Erythema (before) (mm<sup>2</sup>)</b>			0.956
Min	10	5	
Max	84	94	
Mean ± SD	37.44±22.88	38.06±25.69	
<b>Erythema (after) (mm<sup>2</sup>)</b>			0.491
Min	0.00	0.00	
Max	30.00	30.00	
Mean ± SD	10.12±8.89	12.87±9.89	
<b>P</b>	<0.001	0.001	-

Min: Minimum, Max: Maximum, SD: Standard deviation  
Figure 4 shows the erythema of the palate in the two groups before and after the treatment.



**Fig 4.** Erythema before (left) and 2 weeks after (right) the treatment with nystatin plus curcumin

## DISCUSSION

This study compared the antifungal efficacy of curcumin plus nystatin, and nystatin monotherapy for treatment of types II and III denture stomatitis. The results indicated that both nystatin and nystatin plus curcumin were equally effective and both significantly decreased the *C. albicans* colony count and improved the erythema with no significant difference with each other (neither at baseline nor after the intervention).

The present results were in agreement with those of Mustafa et al, [14] Babaii et al, [15] Garcia-Gomes et al, [16] and Alalwan et al [17]. Mustafa et al. [14] compared the efficacy of an alcohol-free chitosan-curcuminoid mouthwash and chlorhexidine for treatment of denture stomatitis in a clinical trial. The formulation of the curcuminoid mouthwash in their study was similar to that used in the present study, and they used an aqueous solvent to minimize the side effects. In this study, propylene glycol was used instead of polyethylene glycol to preserve the buffering

capacity of the solution. They reported significant improvement of erythema in all groups; however, its improvement was greater in the curcumin group. But no significant difference was found in this regard between the two groups in the present study. Babaii et al. [15] evaluated the inhibitory effect of curcumin and nystatin on *C. albicans*. They evaluated different concentrations of curcumin, and showed that increasing the concentration of curcumin increased its antifungal effects. However, nystatin was more effective than curcumin. They used dimethyl sulfoxide as a solvent for curcumin. However, they found that dimethyl sulfoxide had antifungal effects as well, and thus, served as a confounding factor, affecting the results. Water was used as the solvent in the present study to ensure no confounding effect of solvent on the results. Their results were generally in line with the present findings. Garcia-Gomes et al. [16] evaluated the synergistic effects of curcumin and fluconazole on fluconazole-resistant *C. albicans*. They showed that curcumin significantly prevented the resistance of *C. albicans* to fluconazole. Their results regarding the antifungal effects of curcumin were in agreement with our findings. Alalwan et al. [17] demonstrated that curcumin at 50µg/mL concentration inhibited the adhesion of *C. albicans* to the surface of prosthesis. The present results were in contrast to those of Sharma et al, [25] and Golpour et al [19]. Sharma et al. [25] evaluated the synergistic effects of pure curcumin polyphenol in combination with azoles and polyenes on the generation of reactive oxygen species, causing apoptosis. The preparation process and formulation of the mouthwash in their study were different from those in the current study. However, they used water as the solvent, similar to the present study. They compared the effects of curcumin with five azoles (miconazole, fluconazole, ketoconazole, itraconazole, and voriconazole) and two polyenes (nystatin and amphotericin B). The results showed that pure curcumin polyphenol had synergistic effects with antifungal agents with phenol and azole

moieties. The current results failed to show the synergistic effect of nystatin and curcumin. Golpour et al. [19] evaluated the antifungal effect of curcumin encapsulated in nano-micelle particles on expression of CDR1 gene by fluconazole-resistant *C. albicans*. They showed the synergistic effects of azoles with curcumin. Their results were different from the current findings, which may be due to the use of different *C. albicans* strains, and use of polyenes in comparison with azoles. Mugilan et al. [26] reported significant efficacy of curcumin for reduction of socket width and pain after tooth extraction in patients with type II diabetes mellitus. They concluded that curcumin can enhance wound healing due to its anti-inflammatory, disinfecting, antioxidant, and apoptotic effects. Raman et al. [27] indicated that curcumin decreased pain and size of aphthous ulcers, and Malekzadeh et al. [28] demonstrated that oral intake of nano-curcumin effectively decreased inflammation and gingival bleeding in patients with mild periodontitis. The present study was similar to the study by Gonoudi et al, [29] in the technique of using the mouthwash. They compared Zataria multiflora mouthwash with nystatin, and showed that it decreased the *C. albicans* colony count and improved erythema, as did curcumin in the present study.

Evidence shows that curcumin has a wide range of pharmacological activities including antioxidant, anti-inflammatory, antimicrobial, and anti-cancer properties. Curcumin affects all phases of wound healing. In the inflammatory phase, curcumin decreases the production of interleukin-1 and tumor necrosis factor-alpha pro-inflammatory cytokines, which leads to long-term reduction in the activity of macrophages and monocytes, and subsides the inflammation as such [18,26]. Curcumin also decreases the synthesis of matrix metalloproteinases 2 and 7, and inhibits matrix degradation mediated by inflammation. In the proliferative phase, by an increase in concentration of hydroxyproline, which indicates an organized increase in collagen synthesis, the granulation tissue production and angiogenesis increase as well [28,26]. In the wound contraction

phase, curcumin increases the accumulation of myofibroblasts, and enhances the conversion of fibroblasts to myofibroblasts, which help in wound contraction due to the activity of actin proteins [18,26]. In the remodeling phase, curcumin increases the production of antioxidant molecules, superoxide dismutase, and catalase, and eliminates reactive oxygen species as such. Moreover, the proliferated keratinocytes in the newly formed epithelium protect against the destructive effects of xanthine oxide [18,26]. Furthermore, in the early phase of wound healing, curcumin causes the apoptosis of damaged or unwanted cells at the wound site [18,26]. Nystatin exerts its antifungal effects by binding to sterol in the cell membrane of fungi and changing their permeability, resulting in eventual cell death [30].

Future studies with a larger sample size are required to assess the pure effect of curcumin mouthwash with different concentrations on *C. albicans* colony count and erythema. Also, the efficacy of other forms of curcumin should be investigated in further studies.

## CONCLUSION

Addition of curcumin to nystatin suspension did not add any significant advantage with regard to reduction of *C. albicans* colony count or erythema of the palate, and both interventions were equally effective.

## CONFLICT OF INTEREST STATEMENT

None declared.

## REFERENCES

1. Di Stasio D, Lauritano D, Minervini G, Paparella RS, Petrucci M, Romano A, Candotto V, Lucchese A. Management of denture stomatitis: a narrative review. *J Biol Regul Homeost agents*. 2018 Jan;32(2 Suppl. 1):113-6.
2. de Souza RF, Khiyani MF, Chaves CAL, Feine J, Barbeau J, Fuentes R, et al. Improving practice guidelines for the treatment of denture-related erythematous stomatitis: a study protocol for a randomized controlled trial. *Trials*. 2017 May;18(1):1-8.
3. Badaró MM, Bueno FL, Arnez RM, Oliveira VC, Macedo AP, Souza RF, et al. The effect of three disinfection protocols on candida spp., denture stomatitis, and biofilm: A parallel group

- Randomized Controlled Trial. *J Prosthet Dent.* 2020 Dec;124(6):690-8.
4. P, Kouadio AA, Bandiaky ON, Le Guehenec L, La Cochetière M-F. Host's immunity and *Candida* species and associated with denture stomatitis: A narrative review. *Microorganisms.* 2022 Jul; 10(7):1437.
  5. Gauch LM, Pedrosa SS, Silveira-Gomes F, Esteves RA, Marques-da-Silva SH. Isolation of *Candida* spp. from denture-related stomatitis in Pará, Brazil. *Braz J Microbiol.* 2018 Jan;49(1):148-51.
  6. Pinelli LAP, Montandon AAB, Corbi SCT, Moraes TA, Fais LMG. Ricinus communis treatment of denture stomatitis in institutionalised elderly. *J Oral Rehabil.* 2013 May;40(5):375-80.
  7. Lyu X, Zhao C, Yan ZM, Hua H. Efficacy of nystatin for the treatment of oral candidiasis: a systematic review and meta-analysis. *Drug Des Devel Ther.* 2016 Mar;10:1161-71.
  8. Jamalpour P, Lesan S, Ghodarzi M. Investigate the antifungal effect of three type of honey on *Candida albicans*, an in vitro study. *J Res Dent Sci* 2021 Jan;18:99-108.
  9. Lesan S, Haji Fattahi F, Rahbar M, Mohammadi S. The effect of probiotic yoghurt on the frequency of salivary *Candida*. *J Res Dentomaxillofac Sci* 2017 Jul;2(2):1-7.
  10. Bhat N, Mitra R, Reddy J, Oza S, Vinayak M. Evaluation of the efficacy of chlorhexidine and an herbal mouthwash on dental plaque: an invitro comparative study. *Int J Pharm Bio Sci.* 2013;4:625-32.
  11. Joe B, Lokesh B. Dietary n-3 fatty acids, curcumin and capsaicin lower the release of lysosomal enzymes and eicosanoids in rat peritoneal macrophages. *Mol Cell Biochem.* 2000 Jan;203(1):153-61.
  12. Lantz RC, Chen GJ, Sarihan M, Solyom AM, Jolad SD, Timmermann BN. The effect of extracts from ginger rhizome on inflammatory mediator production. *Phytomedicine.* 2007 Feb;14(2-3):123-8.
  13. Anand P, Kunnumakkara AB, Newman RA, Aggarwal BB. Bioavailability of curcumin: Problems and promises. *Mol Pharm* 2007 Dec;4(6):807-18.
  14. Mustafa MW, Ungphaiboon S, Phadoongsombut N, Pangsomboon K, Chelae S, Mahattanadul S. Effectiveness of an alcohol-free chitosan-curcuminoid mouthwash compared with chlorhexidine mouthwash in denture stomatitis treatment: a randomized trial. *J Altern Complement Med.* 2019 May;25(5):552-8.
  15. Babaii N, Zamaninejad S. Inhibitory effect of curcumin on *Candida-albicans* compared with nystatin: an in-vitro study. *J Dent Mater Tech.* 2016 Dec;5(4):196-201.
  16. Garcia-Gomes AS, Curvelo JA, Soares RA, Ferreira-Pereira A. Curcumin acts synergistically with fluconazole to sensitize a clinical isolate of *Candida albicans* showing a MDR phenotype. *Med Mycol.* 2012 Jan;50(1):26-32.
  17. Alalwan H, Rajendran R, Lappin DF, Combet E, Shahzad M, Robertson D, et al. The anti-adhesive effect of curcumin on *Candida albicans* biofilms on denture materials. *Front Microbiol.* 2017 Apr;8:659.
  18. Maheshwari RK, Singh AK, Gaddipati J, Srimal RC. Multiple biological activities of curcumin: a short review. *Life Sci.* 2006 Mar;78(18):2081-7.
  19. Golpour H, Ranji N, Sharami SH. Investigation of antifungal effect of nanoparticle-encapsulated curcumin on CDR1 gene expression in fluconazole-resistant isolates of *Candida albicans*. *J Microb World.* 2017;10(3):222-30.
  20. Amanlou M, Beitollahi JM, Abdollahzadeh S, Tohidast-Ekard Z. Miconazole gel compared with *Zataria multiflora* Boiss. gel in the treatment of denture stomatitis. *Phytother Res.* 2006 Nov;20(11):966-9.
  21. Sahlan M, Ardiellaputri AP, Hermasnyah H, Wijanarko A, Darwita RR. Anti oral biofilm mouthwash nanoemulsion containing extract propolis and curcumin. In AIP Conference Proceedings 2018 Nov 7 (Vol. 2024, No. 1, p. 020059). AIP Publishing LLC.
  22. Tanaka S, Yoshida M, Murakami Y, Ogiwara T, Shoji M, Kobayashi S, et al. The relationship of *Prevotella intermedia*, *Prevotella nigrescens* and *Prevotella melaninogenica* in the supragingival plaque of children, caries and oral malodor. *J Clin Pediatr Dent.* 2008 Apr;32(3):195-200.
  23. E, da Silva RM, Leite CE, Campos MM, Figueiredo MA, Salum FG, et al. Stability and efficacy of combined nystatin and chlorhexidine against suspensions and biofilms of *Candida albicans*. *Arch Oral Biol.* 2018 May;89:70-6.
  24. Alazzawi H, Ahmed JN. Assessment of oral sample collection technique for the isolation of *Candida albicans* from patients having denture stomatitis. *Int J Sci Res.* 2017 Apr;6(4):1100-3.
  25. Sharma M, Manoharlal R, Negi AS, Prasad R. Synergistic anticandidal activity of pure polyphenol curcumin I in combination with azoles and polyenes generates reactive oxygen species leading to apoptosis. *FEMS yeast Res.* 2010 Aug;10(5):570-8.
  26. Mugilan R, Jayaswal R, Sowmya R, Vincent SS, Vaishali K, Prasad K. Effect of curcumin on healing of extraction sockets in type II diabetic



patients-A pilot study. *J Evol Med Dent Sci.* 2020 Mar;9(13):1045-50.

27. Raman P, Pitty R, Krithika CL, Anand SN, Subramani GP. Topical curcumin and triamcinolone acetonide in recurrent minor aphthous ulcers: A pilot trial. *J Contemp Dent Pract.* 2020 Aug;21(8):885-90.

28. Malekzadeh M, Kia SJ, Mashaei L, Moosavi MS. Oral nano-curcumin on gingival inflammation in patients with gingivitis and mild periodontitis. *Clin Exp Dent Res.* 2021 Feb;7(1):78-84.

29. Gonoudi E, Rezai M, Farrokhnia T, Goudarzi M, Sima A. Comparison of antifungal efficacy of *Zataria multiflora* and nystatin for treatment of denture stomatitis: A randomized clinical trial. *J Dent (Shiraz)* 2021 Mar;22(1):60-6.

30. Dos Santos AG, Marquês JT, Carreira AC, Castro IR, Viana AS, Mingeot-Leclercq MP, et al. The molecular mechanism of nystatin action is dependent on membrane biophysical properties and lipid composition. *Phys Chem Chem Phys.* 2017 Nov;19(44):30078-88.