

Mandibular First Molar with a Radix Entomolaris: An Endodontic Dilemma

Priyanka Sarangi^{✉1} Veerendra M Uppin²

¹Department of Conservative Dentistry and Endodontics, SCB Dental College & Hospital, Cuttack, Odisha, India

²Professor, Department of Conservative Dentistry & Endodontics, KLE Dental College & Hospital, Belgaum, Karnataka

Abstract

It is known that the mandibular first molar can display significant anatomical variations namely the number of root canals, the number of roots and morphology. Mandibular molars may sometimes have an additional root located lingually (the radix entomolaris) or buccally (the radix paramolaris). If encountered, an awareness and understanding of this unusual root and its canal morphology can contribute to the successful outcome of root canal treatment. This case report discusses endodontic treatment of a mandibular first molar with a radix entomolaris, which is a rare entity and poses as an endodontic dilemma for the clinician with respect to diagnosis and subsequent treatment. Clinicians should be aware of these unusual root morphologies in the mandibular first molar which needs strategic treatment as unfilled canals remain a nidus for infection and can compromise treatment outcome.

Key words: Radix Entomolaris; Mandibular Molars; Endodontics

Journal of Dentistry, Tehran University of Medical Sciences, Tehran, Iran (2014; Vol. 11, No. 1)

✉ Corresponding author:

P. Sarangi, Department of Conservative Dentistry & Endodontics, SCB Dental College & Hospital, Cuttack, Odisha and designation as Senior Resident Cuttack, Odisha, India

priyankasarangi@yahoo.co.in

Received: 22 August 2013

Accepted: 27 November 2013

INTRODUCTION

The success of endodontic treatment depends on the eradication of microbes from the root-canal system and prevention of re-infection [1]. It is known that the mandibular first molar can display several anatomical variations; endodontic therapy of mandibular molars has always been an endodontic dilemma [2]. Carabelli [3] in 1844 first mentioned a major anatomical variant of the two rooted mandibular first molar; a tooth with a third root that is a distolingual root named as the Radix Entomolaris (RE)[4]. If this root is placed buccally then it is called Radix Paramolaris [5, 6]

which is even a rarer entity described by Bolk [4]. When found, complete diagnosis and treatment are necessary just like other canals [7]. This article describes the diagnosis and management of a case with a Radix Entomolaris.

CASE REPORT

A 22 year-old female patient was referred to the Department of Conservative Dentistry and Endodontics complaining of pain. Pain was moderate and intermittent. Sensitivity to hot and cold items was present.

The pain had been present for 2 weeks.

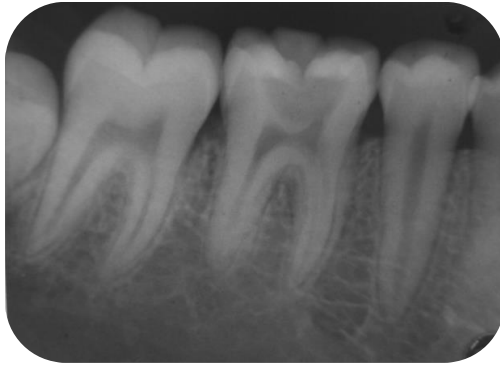


Fig 1. Pre-operative radiograph where radix is not visible

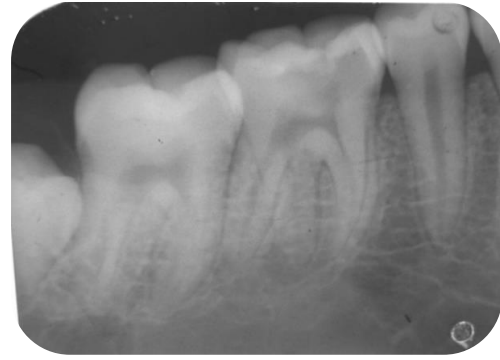


Fig 2. A second preoperative radiograph of tooth 46 taken with a more mesial angulation and revealing the presence of a lingually located additional distal root.

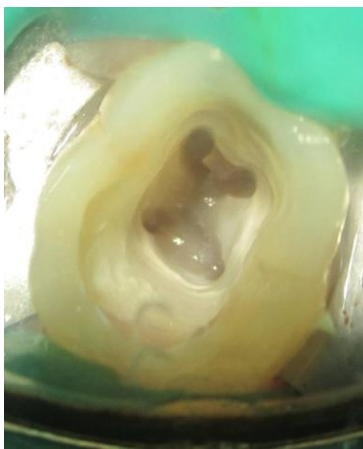


Fig 3. Access opening showing the distolingual orifice in the mandibular right first molar.

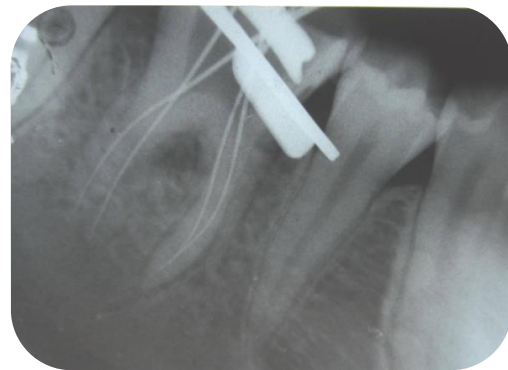


Fig 4. Working-length radiograph

The pain persisted for at least 5 min after intake of any hot or cold liquid. Clinical examination revealed a deep carious lesion of the right permanent first mandibular molar. The involved tooth showed a delayed response upon electric pulp testing (Digitest, zeta dental, UK). Thermal testing with cold application (Endo Ice) induced pain that persisted for 5 min. Radiographically, a carious lesion was seen encroaching on the pulp space. A diagnosis of symptomatic irreversible pulpitis was made. The radiograph also revealed an indistinct root canal outline in the distal root which appeared thick. Two other radiographs with different horizontal angulations were made that showed the presence of an additional lingual root (Figures 1 and 2).

Inferior alveolar nerve block anesthesia (2% Lignocaine with 1:200000 epinephrines) was given and access cavity preparation was done via endo-access bur (Dentsply, USA) and canal orifices were found with a DG 16 endodontic explorer. The access cavity which was triangular in shape was modified into a more trapezoidal cavity in order to locate the orifice distolingually. Initial negotiation of the root canals was confirmed with ISO size #10 file. Farther away from distal root canal orifice a fourth disto-lingual canal orifice was found (Figure 3).

The canal lengths were determined radiographically with K file ISO size #15 (Figure 4) and electronically with Root ZX, (J. Morita, Kyoto USA).

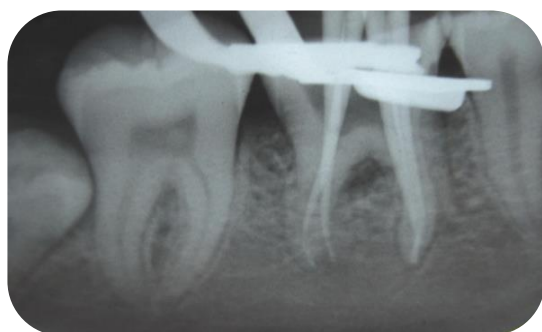


Fig 5. Master-cone radiograph

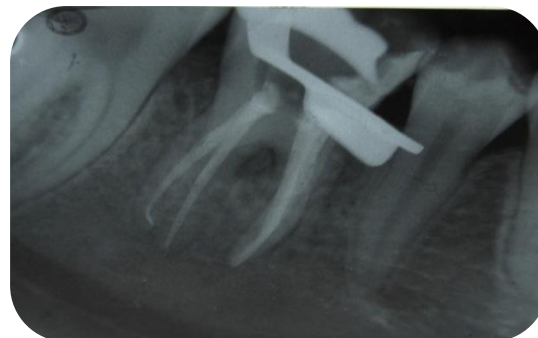


Fig 6. Post-obturation radiograph

Sodium hypochlorite 3% (Vista Dental Product, India) along with EDTA (Glide, Dentsply, USA) was used to clean the canals; shaping was done with ProTaper (Dentsply, USA) rotary system until a size of F2 after which a dressing of calcium hydroxide paste was placed and the patient was recalled 7 days later. At the subsequent appointment, the patient was totally relieved from pain. Proper fitting of cones was evaluated by the master cone radiograph (Figure 5).

Canals were thoroughly dried with paper points (DiaDent, BC, Canada) and obturation (using single cone technique) was done by using zinc oxide eugenol based sealer (Kerr, Orange, CA, USA) (Figure 6).

DISCUSSION

External factors during dentin formation or presence of an atavistic gene could affect the formation of dysmorphic supernumerary roots. Racial genetic factors affect the more profound expression of a particular gene that gives rise to the more pronounced phenotypic manifestation in roots which are eumorphic [8]. The genetic penetrance of the 'three rooted molar' is high as per Curzon [9]. The fact that highlighted the dominance of Radix Entomolaris is that the prevalence of the genetic penetrance was similar in both pure Eskimo and Eskimo/Caucasians [9].

In the African populations [9] the prevalence of the three-rooted lower first molars is around 3%, and in Caucasians [9] it does not go beyond 4%.

In populations with Mongolian [9] traits it ranges between 5-40% and in Eurasian and Asian populations [9] it is less than 5% [8]. In the Indian [10] population the prevalence of RE is less (2.16%) than what was cited for any other Asian populations and had a greater occurrence on the right side of the jaw and in women. Bilateral occurrence of RE was found to be around 60%. Carlsen and Alexandersen [4] explained the morphological and anatomical variations of such root systems with an extra lingual or buccal root. Such a high frequency of a third root in lower first molars makes it mandatory to carefully examine radiographs, to have knowledge about the anatomy, modify the access opening and find missed canals [5, 10]. Ribeiro & Consolaro [6] (1997) gave a classification for RE as follows: the type I refers to a straight root/root canal, the type II refers to an initially curved entrance and the continuation as a straight root/root canals, the type III as an initial curve in the coronal third of the root canal and a second buccally orientated curve starting from the middle to apical third. Four different types of RE according to the location of the cervical part of the RE: types A, B, C and AC were described by Carlsen and Alexandersen [11]. The type A depicts a lower first molar with two normal distal roots along with a radix which is distally located and type B depicts molars with one normal distal root and a distally situated cervical part of the Radix. If the cervical part is located mesially it is depicted as type C, while a more or less central

location between the distal and mesial roots is referred to as type AC. This classification helps in the identification of separate and non-separate RE. The presence of an RE or an RP is of paramount importance in endodontics. A proper diagnosis of these supernumerary roots can prevent complications or missing a canal during the root canal treatment. An inaccurate diagnosis may occur on the radiograph due to superimposition of the distobuccal root over the radix as they are mostly located in the same plane. A detailed inspection of the pre-operative radiograph and interpretation of particular marks or characteristics, such as an obscured view in outline of the distal root or the root canal, can indicate the presence of a 'hidden' RE. To see the RE on the intraoral periapical radiograph, a second radiograph should be taken with a different angle [5]. Thorough clinical examination of the tooth crown and inspection of the cervical morphology of the roots can give us a hint of an additional root. It can be identified by periodontal probing, and use of instruments like an endodontic explorer, JW-17 explorer, pathfinder and micro-opener. A technique can be used like, using sodium hypochlorite in the pulp chamber to see if bubbles are produced by remaining pulp tissue in the canal called as the "champagne effect". Sometimes an additional cusp (tuberculin paramolaris) may hint an extra root. Extending the triangular access cavity to a rectangular or trapezoidal form along with the complete removal of roof of pulp chamber may help in finding the distolingual orifice. Visual aids such as a loupe, intraoral camera or dental microscope can also be useful.

A dark line on the pulp chamber floor can hint towards the precise location of the RE canal orifice [12]. Once relocation and enlargement of the orifice of the RE are done, initial root canal exploration with small files (size 10 or 8) should be done along with radiographic assessment of root canal length and curvature determination [13, 14].

CONCLUSION

During molar endodontic treatment, it is essential to find all the canals as there may be a fourth canal present. Proper mesial and distal angulation and interpretation of radiographs help to identify the root canal anatomy and any variations that are present in it. In the case of a Radix Entomolaris, the conventional triangular access cavity opening must be modified to a trapezoidal form in order to properly locate the distolingually located canal orifice of the extra root. Due to the curvature seen in majority of radices a straight-line access and glide path must be given attention.

REFERENCES

- 1- Haapasalo M, Shen Y, Qian W, Gao Y. Irrigation in endodontics. *Dent Clin North Am.* 2010 Apr;54(2):291-312. doi: 10.1016/j.cden.2009.12.001.
- 2- Calberson FL, De Moor RJ, Deroose CA. The radix entomolaris and paramolaris: clinical approach in endodontics. *J Endod.* 2007 Jan;33(1):58-63. Epub 2006 Jul 26.
- 3- Carabelli G. *Systematisches Handbuch der Zahnheilkunde*, 2nd ed. Vienna: Braumuller und Seidel, 1844:114.
- 4- Bolk L. Bemerkungen über Wurzelvariationen am menschlichen unteren Molaren. *Zeitung für Morphologie und Anthropologie* 1915;17:605-10.
- 5- Calberson FL, De Moor RJ, Deroose CA. The radix entomolaris and paramolaris: clinical approach in endodontics. *Anatomic variations of lower first permanent molar roots in endodontics. J Endod* 2007 Jan;33(1):58-63.
- 6- Carlsen O, Alexandersen V. Radix paramolaris in permanent mandibular molars: identification and morphology. *Scan J Dent Res* 1991;99:189-95.
- 7- Pattanshetti N, Gaidhane M, Al Kandari A. M. Root and canal morphology of the mesiobuccal and distal roots of permanent first molars in a Kuwait population – a clinical study. *Int Endod J.* 2008; 41:755-62.

- 8- RJG De Moor. The radix entomolaris in mandibular first molars: an endodontic challenge. *Int Endo J* 2004; 37: 789-99.
- 9- Curzon ME. Three rooted lower molars in man and their racial distribution. *Br. Dent J.* 1973; 52:181-3.
- 10- Gupta S, Raisingani D, Yadav R. The radix entomolaris and paramolaris: a case report. *J Int Oral Health* 2011;3:43-49.
- 11- Carlsen O, Alexandersen V. Radix entomolaris: identification and morphology. *Scan J Dent Res* 1990;98:363-73.
- 12- Ingle JI, Bakland LK, Baumgartner JC. *Ingle's Endodontics Six*. PMPH-USA.2008
- 13- Sperber GH, Moreau JL. Study of the number of roots and canals in Senegalese first permanent mandibular molars. *Int Endod J.* 1998; 31:117-22
- 14- Weine FS. Access cavity preparation and initiating treatment. In: Weine FS, ed *Endodontic Therapy*, 6th edition. St. Louis, USA; The C. V. Mosby Company. 2004; p.104-63.