

Measuring the Reliability of Sagittal Facial Anthropometric Measurements Under Soft Tissue Displacement Using a Modified Ruler

Faramarz Mojtahedzadeh^{1✉}, Saeed Alizadeh², Bahareh Riazi², Ahmad Reza Shamshiri³

¹Assistant Professor, Dental Research Center, Dentistry Research Institute and Department of Orthodontics, Tehran University of Medical Sciences, Tehran, Iran

²Dentist

³Epidemiologist, Dental Research Center, School of Dentistry, Tehran University of Medical Sciences, Tehran, Iran

Abstract

Objective: Despite the current use of radiography for quantifying sagittal skeletal measurements, it is an unsuitable way for screening or epidemiologic purposes. Although not fully approved, anthropometric measurements have been suggested as a substitute, and considering displacement of soft tissues, could possibly lead to more consistent results. The purpose of this study was to evaluate the reliability of anthropometric anteroposterior facial measurements under soft tissue compression using a special ruler.

Material and Methods: Anthropometric measurements were done with a specifically designed sliding ruler twice on 36 adult patients with a 14 day lag between two measurements. The ruler measured the distance between the external acoustic meatus and the nasion (Na), subnasal (Sn) point and the soft tissue pogonion (Pog). The soft tissue was displaced during measurements only to the extent that the underlying hard tissue resistance was felt subjectively by each assessor. The intraclass correlation coefficient (ICC) was calculated for both inter- and intra-rater measurements using SPSS software.

Results: All measurements had inter- and intrarater agreements above 0.9, with only a few parameters having lower bound confidence intervals below 0.9, but more than 0.8.

Conclusion: Sagittal facial anthropometric measurements under soft tissue displacement using the specific ruler are valid and reliable and could possibly aid orthodontists in chairside craniofacial assessments.

Key Words: Anthropometry; Face; Anatomy; Reproducibility of Measurements

Journal of Dentistry, Tehran University of Medical Sciences, Tehran, Iran (2013; Vol. 10, No.2)

✉ Corresponding author:

F. Mojtahedzadeh, Department of Orthodontics, School of Dentistry, Tehran University of Medical Sciences, Tehran, Iran

mojzad@tums.ac.ir

Received: 3 December 2012

Accepted: 20 February 2013

INTRODUCTION

Although the current trend in orthodontics is to plan treatment generally based on extraoral

soft tissue dimensions, it is certainly impossible to ignore the limitations caused by bony structures. Growth modification procedures

which aim at skeletal discrepancies at younger ages also require an appraisal of maxillary and mandibular dimensions. This could be the reason why orthodontists still have to base diagnostic and treatment decisions on radiographic assessments such as cephalometric measurements.

On the other hand, it is also evident that radiographic assessment methods cannot be considered practical for screening purposes in routine dental settings or wide-scale epidemiologic surveys. Two major limitations exist: concerns about exposing individuals to even minimal amounts of radiation, and the relatively costly and time consuming hardware requirements. These drawbacks could be good excuses why currently used orthodontic indexes rely mostly on dental findings and lack of skeletal components.

Therefore, it would be desirable to develop a brief yet acceptable chairside alternative for such measurements in order to determine the underlying skeletal relationships in a reliable manner; and to eliminate the need for cephalograms in such occasions.

Reviewing the orthodontic literature shows that attempts have been made toward introducing alternatives for cephalometric analyses that are mainly based on soft tissue measurements.

The underlying assumption in this domain is that the overlying facial soft tissue appearance is more or less influenced by its underlying bone structure [1-3].

This concept has been employed in the craniofacial superimposition method by forensics [4] and is still in use [5].

Based on this concept, studies have been conducted that mainly deal with either photogrammetric or anthropometric methods.

Although photographic measurements have been reported as highly reproducible [6,7], the correlation between cephalometric and photographic measurements has not been high enough to consider it a consistent substitute to cephalometric measurements.

The reason is variation in soft tissue thickness. In other words, the variable thickness of the overlying soft tissue does not allow for an accurate prediction of underlying bone dimensions. Acknowledging this variation, displacing the soft tissues, as observed in some anthropometric studies could be a solution to the problem. Farkas suggests application of force during anthropometric measurements as aid to determine "bony landmarks" [8]. It appears that this concept has not been verified with the aid of radiographic assessments, but if proved, it can be proposed that this method could result in even better correlations with cephalometric measurements. At the same time it may be questioned that the amount of soft tissue displacement could be significantly different between assessors, possibly making the method unreliable; especially when considering different soft tissue thicknesses at different facial regions. Therefore, the current study was conducted in order to measure the reliability of some anteroposterior facial anthropometric measurements using a specially designed ruler under soft tissue compression.

MATERIALS AND METHODS

Thirty-six consecutive adolescent patients enrolled for treatment in a single semester at the Department of Orthodontics of Tehran University of Medical Sciences were chosen for this study. None of the cases had received previous orthodontic treatment. Anthropometric measurements were performed with the aid of a custom designed sliding ruler (Fig 1).

The ruler was designed very similar to anthropometric sliding rulers; the main modification was incorporation of an ear guide at one end (Fig 1, A), which was placed in the external acoustic meatus, very similar to ear rods of cephalometric machines. The other end consisted of a metal rod also projecting perpendicular to the ruler (Fig 1, B).

The distance between these projections was easily determined by reading the measurement on the ruler.

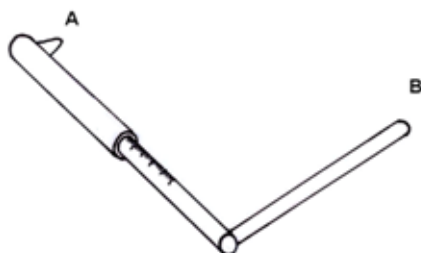


Fig 1. Schematic diagram of the ruler used in the study:
A) ear rod B) anterior rod

Three measurements were done in this study which consisted of:

- i) Distance between external auditory meatus to nasion (Ext – N)
- ii) Soft tissue maxillary length measured from the external auditory meatus to the subnasal point (Ext – Sn)
- iii) Soft tissue mandibular length that was considered as the distance between the external auditory meatus to the soft tissue pogonion (Ext – Pog')

It was decided that each assessor displaced or compressed the soft tissue in each area subjectively. Examiners applied only enough pressure to “feel” the underlying hard tissue resistance and not too much to cause any discomfort for the patient. Each measurement was independently performed twice by two assessors with a 14-day lag between the two measurements. The intraclass correlation coefficients (ICC) using a two-way random model and absolute agreement type and corresponding 95% confidence intervals (CI) were calculated with SPSS 16 for Windows (SPSS Inc., Chicago, Ill, USA) to measure the reliability of the repeated soft tissue measurements.

RESULT

The ICC for the reliability of soft tissue measurements along with the 95% confidence intervals are listed in Table 1.

As observed, all measurements had a reliability coefficient above 0.9, with only a few parameters having a lower bound confidence interval below 0.9, but more than 0.8.

DISCUSSION

The extensive work of Farkas in anthropometry of the head and face is well known and it is clear that anthropometric measurement in the craniofacial region is not a new topic [8]). But previous anthropometric measuring techniques which perform measurements on the soft tissue by merely “touching” soft tissues appear to be somehow inaccurate for “bony measurements” and specifically for orthodontic screening purposes. Therefore, it would be desirable to develop a simple yet reliable method to assess the craniofacial relationships in clinical orthodontic situations.

The results of the current study show that anthropometric anteroposterior measurements obtained with soft tissue displacement can achieve a reasonable level of reliability, even comparable to reproducible photographic measurements. In order to obtain such a level of agreement, there was no need for a calibrating session between examiners regarding the amount of soft tissue compression [6].

But at the same time, the different levels of reliability among three anthropometric measurements in our study supposedly could be explained by the difference in soft tissue thickness in each area: less variation is expected in the soft tissue thickness at nasion and more in other areas. Generally speaking, higher inter-and intra-rater reliability was observed in the external auditory meatus-nasion measurement and lower in other areas.

Profitt considers “poor man” cephalometric assessment a valuable tool for determining the underlying skeletal relationship, where others believe it to be an inappropriate method [1, 9]. If further-developed research designs confirm the findings of our study, using such measurements at the chairside eventually become

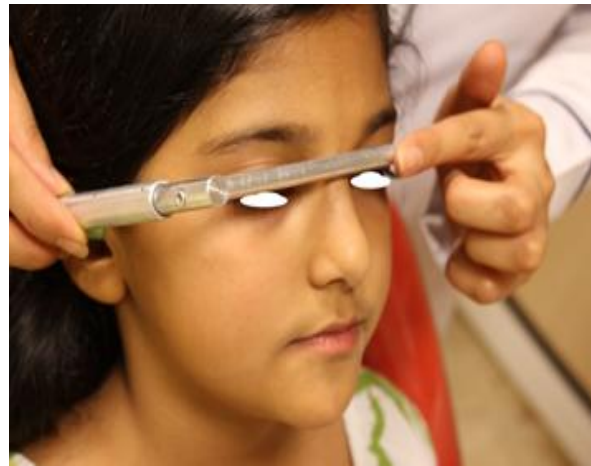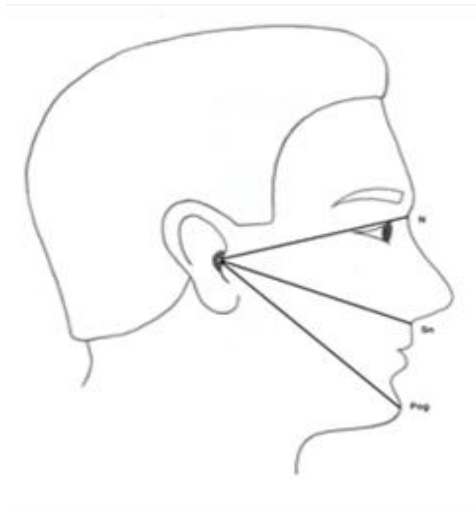


Fig 2a. Schematic measurements and landmarks of the study b) Measurement of Ext-N performed on the patient

a more practical method in orthodontic screening procedures for skeletal assessment.

As the current investigation basically intended to assess the effect of soft tissue displacement, the selection of cases as well as sample size was not based on specific sampling issues.

Examiners agreed that proper alignment of the ruler both sagittally and horizontally was a slight time consuming factor for the measurement process.

This inconvenience could also be an explanation for the small intra- and inter-rater disagreement between measurements.

Table 1. Intra and Inter-Examiner Correlation Coefficients of the Study Measurements

Parameter	ICC	Upper Bound	Lower Bound
Ext – N (Ex1)	0.974	0.987	0.951
Ext – N(Ex2)	0.967	0.983	0.937
Ext – N (Int –Ex)	0.963	0.981	0.929
Ext -Sn(Ex1)	0.957	0.986	0.917
Ext –Sn(Ex2)	0.941	0.973	0.873
Ext –Sn(Int –Ex)	0.907	0.957	0.805
Ext –Pog'(Ex1)	0.957	0.980	0.907
Ext –Pog'(Ex2)	0.960	0.982	0.913
Ext –Pog'(Int –Ex)	0.940	0.972	0.872

Ex 1 = Examiner 1, Ex 2= Examiner 2, Int – Ex = Inter Examiner

This called for a redevelopment of the ruler design which was considered in our subsequent studies. In comparison to studies dealing with photographic measurements, if such anthropometric measurements show a better correlation with cephalometric data, we may hope that such methods become a reliable screening tool for both clinical and epidemiologic purposes.

Investigating the correlation between anthropometric and radiographic measurements could not be conducted since the reliability of soft tissue measurements under soft tissue displacement using the new device was unknown. But with the results of the current study, this correlation has been taken into consideration for our future studies.

CONCLUSION

The results of this pilot study suggest that reliable anthropometric measurements could be obtained under soft tissue displacement. These measurements could eventually aid orthodontists in chairside craniofacial assessments.

ACKNOWLEDGMENTS

This article is based on a thesis submitted to the Department of Orthodontics, Tehran University of Medical Sciences, in partial fulfillment of the requirements for a D.D.S. degree.

REFERENCES

- 1- Profitt WR, Fields HW Jr. The biological basis of orthodontic therapy. In: Profitt WR, Fields HW Jr, editors. Contemporary orthodontics. 3rd ed. St. Louis: Mosby, Inc; 2000. p. 296-325.
- 2- Subtelny JD. A longitudinal study of soft tissue facial structures and their profile characteristics, defined in relation to underlying skeletal structures. Am J Orthod. 1959;45:481-507.
- 3- Reidel RA. An analysis of dentofacial relationships. Am J Orthod. 1957;43(2):103-19.
- 4- Stephan CN. Craniofacial identification: techniques of facial approximation and craniofacial superimposition. In: Blau S, Ubelaker DH, editors. Handbook of Forensic Anthropology and Archaeology. Walnut Creek: Left Coast Press; 2009. p. 304-21.
- 5- Birngruber CG, Kreutz K, Ramsthaler F, Krähhahn J, Verhoff MA. Superimposition technique for skull identification with Afloat® software. Int J Legal Med. 2010 Sep;124(5):471-5.
- 6- Zhang X, Hans MG, Graham G, Kirchner HL, Redline S. Correlations between cephalometric and facial photographic measurements of craniofacial form. Am J Orthod Dentofacial Orthop. 2007 Jan;131(1):67-71.
- 7- Fernandez-Riveiro P, Smyth-Chamosa E, Suarez-Quintanilla D, Suarez-Cunqueiro M. Angular photogrammetric analysis of the soft tissue facial profile. Eur J Orthod. 2003 Aug;25(4):393-9.
- 8- Farkas LG. Measuring tools and techniques. In: Farkas LG. Anthropometry of the head and face. 2nd ed. New York: Raven Press; 1994.
- 9- Ngan P. Treatment of class III malocclusion in the primary and mixed dentitions. Bishara SE. Textbook of orthodontics. 1st ed. Philadelphia: WB Saunders; 2001.p. 375-414.