

Histological evaluation of Accell Connexus[®] and Bio-Oss[®] on quality and rate of bone healing: a single blind experimental study on rabbit's calvarium

A. Khorsand¹, A. A. R. Rasouli Ghahroudi², P. Motahhari³, M. Rezaei Rad⁴, Y. Soleimani Shayesteh⁵

¹Associate Professor, Department of Periodontics, School of Dentistry, Tehran University of Medical Sciences, Tehran, Iran

²Assistant Professor, Dental implants research center and Department of Periodontics, School of Dentistry, Tehran University of Medical Sciences, Tehran, Iran

³Assistant Professor, Department of Oral Pathology, School of Dentistry, Tehran University of Medical Sciences, Tehran, Iran.

⁴Dentist, Private Practice, Tehran, Iran

⁵Professor, Dental Implant Research Center and Department of Periodontics, School of Dentistry, Tehran University of Medical Sciences, Tehran, Iran

Abstract

Objective: The objective of this study was to evaluate the effect of Accell Connexus[®] on the quality and rate of healing in experimental defects of rabbit calvarium compared to Bio-Oss[®].

Materials and Methods: Twelve 2.5-3.5 kg weighing New Zealand white rabbits were used. Three defects (3×6 mm) were created in the cranium of the animals subsequently filled with Accell Connexus[®], Bio-Oss[®] or served as controls. The animals were sacrificed four, six and eight weeks postoperatively and the histology blocks were studied in terms of inflammation, trabeculation thickness, bone type regeneration, foreign body and remained biomaterial by light microscope. The data were subject to Mann-Whitney U test.

Results: Increased inflammatory reaction, foreign body reaction, delayed bone formation and lower rate of ossification were observed in DBM-filled defects compared to Bio-Oss[®] or controls. However, no significant differences were observed in bone formation between Bio-Oss[®], Accell Connexus[®] and control specimens in the three time intervals. Furthermore, no significant differences were noted between Bio-Oss[®] and control groups.

Conclusion: Accell Connexus[®] showed a lower rate of ossification and bone healing compared to Bio-Oss[®] or control groups. Other studies in this field seem necessary.

Key Words: Accell Connexus[®]; Inorganic Bovine Bone Mineral; Animal Study; Osteoinductive; Osteoconductive

✉ Corresponding author:

A. A. R. Rasouli Ghahroudi,
Department of Periodontics,
School of Dentistry, Tehran
University of Medical
Sciences, Tehran, Iran
amirali_rasouli@yahoo.com

Received: 2 March 2012

Accepted: 30 May 2012

Journal of Dentistry, Tehran University of Medical Sciences, Tehran, Iran (2012; Vol. 9, No.2)

INTRODUCTION

Bone defects due to trauma, developmental anomalies, oncological resections, infections

or lesions necessitate reconstructive methods for substitution of lost supportive tissues for which different bone graft materials are avail-

able. These materials promote the bone-healing response through provision of osteogenic, osteoconductive and osteoinductive activities. Bone graft materials have been divided into autografts, allografts, xenografts, synthetic materials or a combination of them each with specific characteristics¹. Autograft is the gold standard for bone grafts, refers to the bone tissues harvested from an individual's iliac crest, femur or tibia and is implanted in the same person. Due to the limitations of autografts such as significant donor-site, morbidity, extended operating room time and limited quantity and quality of bone available for harvest, a variety of synthetic and bioimplants have been developed as bone substitutes. Allograft, an alternative to autograft, is a tissue harvested from an individual implanted into another one of the same species. Xenograft, is a bone tissue harvested and implanted into different species while synthetic materials are various extracted or synthesized protein growth factors, adhesion molecules or synthetic osteoconductive materials which are available for bone graft purposes [1]. Synthetic materials vary greatly in osteoconductivity, osteoinductivity, mechanical strength, handling properties or cost while newly developed materials are constantly made available with improved properties. Biologic acceptability, predictability, clinical feasibility, minimal operative sequel, postoperative sequel and patient acceptance are of the basic principles mentioned for bone graft materials [2]. Up to now, no ideal bone graft material has been developed owning all required properties. Therefore, assessment of different bone graft materials is of primary importance prior to their clinical usage. Based on the studies performed, animal studies on dog, rabbit, monkey, rat or horse may possibly clarify the tissue response to different graft materials.

Bio-Oss®, an osteoconductive bone substitute, has been introduced to promote bone growth in the periodontal and maxillofacial osseous

defects including mineral bovine bone (xenograft). Bio-Oss® has been claimed to promote formation of new cement, functional periodontal ligaments and alveolar bone preserving osteoconduction [3,4].

Bio-Oss® has been used in different areas such as periodontology and intrabony defects [5], peri-implant defects [6], sinus floor augmentation [7,8,9], ridge preservation [10,11], ridge augmentation [12,13] and ridge reconstruction [14]. The similar natural starting material together with the complex patented manufacturing procedures are the resemblances of Bio-Oss® to the human natural bone. Its higher porosity, as human natural bone increases blood vessel formation and bone cell migration through a coarse-meshed interconnecting pore system [15], which is a good meshwork for osteogenic cells and possibly will encourage osteoblastic differentiation and matrix synthesis [16]. Demineralized bone matrix (DBM), another potential alternative supplement for autogenous bone graft, possesses osteoconductive characteristics with a possible osteoinductive property. It has been widely used in different fields of orthopedics, neurosurgery, plastic surgery and dentistry and it has been extensively investigated as a material to induce new bone formation. The osteoinductive characteristics of DBM is possibly due to the existence of matrix-associated bone morphogenetic proteins (BMPs) such as BMP2, BMP4 or BMP7 and growth factors such as TGF- β available in the host environment during the demineralization process [17]. Demineralized bone matrix does not contain osteoprogenitor cells although it facilitates the recruitment of the progenitor cells from the bone marrow to the defects called as osteoinductive property [18]. Furthermore, demineralized bone matrix has been shown to possess high osteoinductive properties improving the integration of autogenous bone grafts in the skull [19].

In the recent years, different DBMs have been introduced for the clinical uses of bone healing

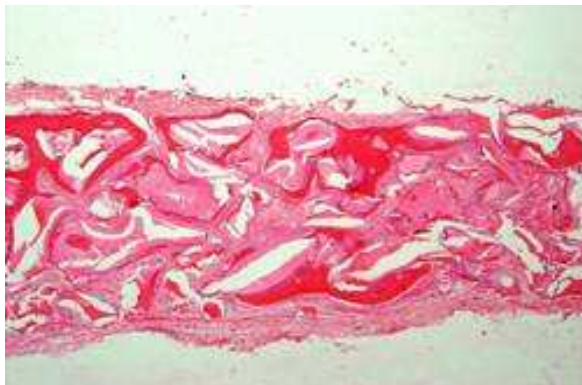

Fig1. Bio-Oss sample at 20×magnification

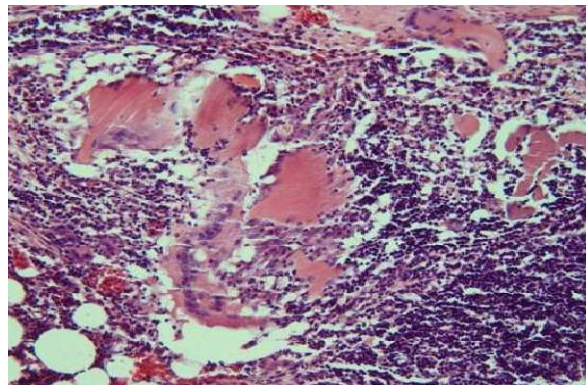


Fig2. DBM at 20× magnification

with different capabilities for the used processing or carrier media. Then, the materials' weaknesses and strengths must be taken into account in the clinical environment and the clinician should select the most effective DBM to gain access to the best outcomes [20]. Different processing and donor variability caused DBMs to show variable osteoinductive activity [21].

The factors possibly influencing DBM's osteoinductive activity are the matrix geometry (particle size) [22], the time to harvest and the age of the donor [23]. Due to the poor handling properties of DBM granules, most commercially available DBMs contain inert carriers such as glycerol, hyaluronic acid or reverse phase polymers, which reduce the DBM content. Accell Connexus® is a 2nd generation demineralized bone matrix (DBM) product. Accell Connexus combines DBM and poloxamer Reverse Phase Medium with Accell Bone Matrix (ABM). This patented, dispersed form of DBM offers significantly increased surface area, which provides access to natural bone proteins [24]. As Accell uses a processed form of DBM as its carrier, the carrier itself is expected to be osteoinductive, resulting in the implant being 100% DBM, which should increase bone repair outcome compared with DBM bioimplants containing DBM in an inert carrier [25]. The purpose of the present study was to histologically evaluate the efficacy of

Accell Connexus® and Bio-Oss® on the quality and bone healing rate in the experimental defects on rabbit calvarium. The main hypothesis of this study was that the osteoinductivity of Accell Connexus® would promote more bone formation than Bio-Oss®.

MATERIALS AND METHODS

In this interventional animal study, 12 healthy 2.5-3.5 kg weighing male New Zealand white rabbits were used.

The study was approved according to the protocol of the University of Tehran Animal Care Ethics Committee. The animals were obtained from Pasteur Institute, Iran while their healthiness was approved by a veterinary surgeon.

The animals were placed under general anesthesia with an intramuscular injection of 35 mg/kg ketamin 10% and 2 mg/kg xylazine 2%. The fur was shaved over the cranium region while the surgical site was prepped and draped with betadine scrub 7% for 5 minutes. An incision was made from the anterior to posterior with a number 15 blade cranio-caudally and the skin and periosteum were reflected with Glickman elevator. Three 3×6mm defects that could be like as a infra bony periodontal defects were made in each rabbit calvarium with a 3 mm bur while the surgical sites were irrigated with the sterile saline to prevent overheating during the surgical procedure. In addition, the periodontal

probe was carefully used to assess the created defects and to ensure each defect to be identical. Anatomical landmarks were also used for determining the ideal place of the defect (occipital process, cranio-caudal suture that transversally separate the frontal bone from parietal bone). The bone substitutes were placed directly into the defect equal to the volume of the bone removed, while 3 defects were randomly grafted in 3 different ways; one defect filled with Accel Connexus® (Gen Sci Ortho Biologics Inc, Irvine, USA), the second with small (0/2-1mm) particles of Bio-Oss® (Geistlich Pharma AG, Wolhusen; Switzerland) and the last one was left unfilled for spontaneous healing as a control group. To eliminate bias in defect location, the defect fill sequences were as follows: in the first rabbit the defects were treated randomly with the two previously mentioned materials and the third defect was left unfilled. Then these positions were changed rotationally (clockwise) for the other rabbits. All locations were recorded in charts. Then, the periosteum and skin were sutured with absorbable sutures 4-0 Vicryl (Ethicon, Johnson & Johnson, USA) and 3-0 monofil polyamide nylon (SINORGMED,

without any apparent complications. Shandong, China), respectively. The animals received endrofloxacin 5% intramuscularly for five days as analgesia with keto profen 10% for three days as an antibiotic. Each rabbit was individually caged and received standardized food (Baby Rabbit Pellets®, M-0662, Master feeds, Division, Maple Leaf Mills LTD, London, Ontario, Canada). The animals were divided into three identical groups and were sacrificed at the fourth, sixth and eighth week postoperatively with an intravenous overdose of 10% sodium thiopental in the auricular vein.

Histological Process

After sacrifice, the entire cranial vault was carefully removed from each animal leaving the pericranium intact.

The specimens were placed for fixation in 10% formalin for at least a week and stored in 10% formic acid for decalcification for 10 days afterwards. Following visual inspections, it was tried to select blocks of similar regions with 1mm margins of the surrounded native bone; then, the specimens were set in lithium carbonate for 10 minutes; subsequently set in formalin solution for 24 hours.

Table 1. Inflammations Observed in the Defects Filled with Bio-Oss®, DBM or Control

Weeks	Group	Negative	Mild	Severe
4	Bio-Oss®	4 (100%)	0	0
	Control	4 (100%)	0	0
	DBM	0	1 (25%)	3 (75%)
6	Bio-Oss®	3 (75%)	1 (25%)	0
	Control	4 (100%)	0	0
	DBM	0	1 (25%)	3 (75%)
8	Bio-Oss®	3 (75%)	1 (25%)	0
	Control	4 (100%)	0	0
	DBM	0	1 (25%)	3 (75%)

The blocks were coded and sent for histological analysis to the pathologist who was blind to the materials used in the defects.

The blocks were embedded in paraffin and sectioned. All sections were stained with hematoxylin-eosin (H&E) for light microscopy assessments. From each block, 5µm thick sections were obtained. Inflammation intensity, foreign body reaction, trabeculation thickness and Regenerated bone type (woven, woven + lamellar, lamellar) were examined by the light microscope (BX40, Olympuse, Japan).

Although foreign body reaction was only examined by the presence or absence of foreign body giant cells in a granulomatous response in the specimens, the inflammation intensity was classified into three grades according to lymphocytic infiltration around the bone graft materials in the examined defects, as mentioned below:

Negative (no inflammation):0-100 lymphocytes

Mild (mild inflammation):100-500 lymphocytes

Moderate to severe (moderate to severe inflammation): over 500 lymphocytes.

The polarized light microscope divided regenerated bone type in to three scores: 1-lamellar 2-lamellar- woven 3-woven.

Furthermore, trabeculation thickness analysis was completed using an eyepiece graticule with 40× magnification classifying it into three divisions of thin (less than 20 µm), moderate (20-60 µm) and thick (more than 60 µm).

The obtained data were subjected to Mann-Whitney U test.

RESULTS

Inflammation intensity and foreign body reaction

In the 4th week specimens, no inflammation was observed in Bio-Oss® defects while in 6- and 8th week specimens, three cases (75%) showed no inflammatory response and only one case (25%) demonstrated mild inflammation.

In DBM-filled defects, there was one mild inflammation (25%) and three severe inflammatory reactions (75%) in the three-time interval analyses.No inflammatory responses were noted in the control specimens (Table 1). Significant differences were observed between Bio-Oss® andDBM afterfour and eight weeks

Table 2.TrabeculationThicknessObserved in the Defects Filled with Bio-Oss®, DBM or Control

Weeks	Group	Negative	Mild	Severe
4	Bio-Oss®	4 (100%)	0	0
	Control	4 (100%)	0	0
	DBM	0	1 (25%)	3 (75%)
6	Bio-Oss®	3 (75%)	1 (25%)	0
	Control	4 (100%)	0	0
	DBM	0	1 (25%)	3 (75%)
8	Bio-Oss®	3 (75%)	1 (25%)	0
	Control	4 (100%)	0	0
	DBM	0	1 (25%)	3 (75%)

(both $p=0.029$). Furthermore, significant differences were noted between DBM and control defects in all time intervals (all $p=0.029$).

Bio-Oss® and control specimens showed no positive foreign body reactions while all DBM specimens were positive regarding this reaction in all three time intervals (Figures 1&2). Furthermore, all DBM and Bio-Oss® defects showed remained biomaterials and a few resorptions.

Trabeculation Thickness

The 4th week

Regarding Bio-Oss® specimens; one case (25%) showed trabeculation thickness of 20-60 μm , two cases (50%) had less than 20 μm thickness and one case (25%) had not initiated ossification. In the controls, two cases (50%) showed a thickness of more than 60 μm , one case (25%) showed 20-60 μm thickness and one case (25%) had already started ossification. In the DBM group, two cases (50%) had already started ossification and the others (2 cases; 50%) showed a thickness of less than 20 μm .

The 6th week

Bio-Oss® and control specimens showed similar trabeculation thicknesses-three cases (75%) with more than 60 μm thickness and one case (25%) with less than 20 μm thickness to the DBM-filled defects showing less than 20 μm and 20-60 μm thicknesses equally (50% for each).

In the 6th week specimens, the bone formed in the Bio-Oss® group was equally of lamellar or lamellar + woven type (two cases, 50%). There was similar frequency of lamellar + woven and woven b

One in the DBM specimens (two cases, 50%). Furthermore, the frequency of lamellar, lamellar + woven and woven bone types was 25% (one case), 50% (two cases) and 25% (one case) in the control specimens, respectively.

The 8th week

All control and three (75%) Bio-Oss® specimens showed thicknesses higher than 60 μm and one case (25%) showed 20-60 μm trabeculation thickness.

Table 3. Bone Regeneration Type Observed in the Defects Filled with Bio-Oss®, DBM or Control

Weeks	Group	Lamellar	Lamellar + Woven	Woven
4	Bio-Oss®	0	2 (66.7%)	1 (33.3%)
	Control	0	3 (100%)	0
	DBM	0	0	2 (100%)
6	Bio-Oss®	2 (50%)	2 (50%)	0
	Control	1 (25%)	2 (50%)	1 (25%)
	DBM	0	2 (50%)	2 (50%)
8	Bio-Oss®	3 (75%)	1 (25%)	0
	Control	4 (100%)	0	0
	DBM	0	3 (75%)	1 (25%)

DBM specimens showed an equal frequency of 20-60 μm and less than 20 μm thicknesses (two cases; 50%) (Table 2).

According to the Mann-Whitney test, significant differences only existed between DBM and control defects after the 8th week ($P=0.029$) with no other significant differences being noted performing paired comparisons in the three time intervals.

Regenerated Bone Type

Two experimental defects of (66.7%) Bio-Oss® specimens showed lamellar + woven bone with one case (33.3%) showing woven bone after the 4th week (one started ossification). All controls demonstrated lamellar + woven bone (three cases; 100%) while the bone formed in all DBM specimens were of woven type (three cases; 100%).

In the 8th week, 75% of Bio-Oss® (three cases) specimens showed lamellar and 25% of them (one case) showed lamellar + woven bone type. In the control, all the bone formed was of lamellar type while in the DBM defects, 75% (three cases) lamellar + woven and 25% woven (one case) bone types were observed (Table 3). Significant differences were observed between DBM and control specimens in the 8th week time interval ($P=0.029$) regarding bone regeneration type while no other significant differences were noted in the paired comparisons between the groups.

With respect to the amount of bone regeneration; the control, Bio-Oss® and DBM groups showed lamellar bone formation in a decreasing order; however, no significant difference was seen ($P>0.05$). There was significantly more regenerated lamellar bone at 8 weeks following surgery compared to 4 weeks in the Bio-Oss® group ($P<0.05$). This result was not significant for other groups ($P>0.05$).

DISCUSSION

The healing of craniofacial defects, as an important clinical challenge, received great atten-

tion, for which autograph remained as the material of choice because it contains three essential elements for bone regeneration (osteogenesis, osteoinductive and osteoconductive). DBM has been used as a bone graft substitute for over thirty years because of its biocompatibility, osteoconductive and osteoinductive properties. DBM bio implants contain DBM mixed with an inert carrier to ease handling of the material leading to a decrease in the amount of DBM to 40% or less of the total implant volume. It has been shown that the amount of induced new bone by DBM is proportional to the amount of DBM implanted; thus, dilution of DBM with an inert carrier will reduce the properties of the bio implant.

Accell Connexus® has been claimed to have osteoinductive besides osteoconductive properties; therefore, it is important to evaluate the material before using in the clinic. The present study demonstrated that inflammatory reaction and foreign body reaction significantly increased in DBM as compared to Bio-Oss® and control defects. The presence of slight inflammatory cells in the bio Oss® group could be indicative of a host reaction to this inert material [26]. Other studies observed no proliferation of inflammatory cells following the application of Bio-Oss® for maxillary sinus augmentation and the rehabilitation of other facial skeletal structures [27, 28]. Van Osch et al. [29] used bovine trabecular demineralized bone matrix in the rabbit ear with no problem or sign of increased inflammation or foreign body reactions, which is in consistency with our study which has shown the biocompatibility of BioOss®.

The present author speculated the severe inflammation in DBM group that remained constant during the study time could be a robust host reaction to a heterogeneous bone substitute material. In Agnol et al.'s study [30], the superiority of homologous demineralized bone matrix graft to heterogeneous xenograft was indicated. Although no significant differences

were noted in the bone properties between Bio-Oss®, DBM and control specimens in all 4, 6 and 8 weeks time intervals, we found less lamellar bone in DBM groups in comparison to control and bio -Oss between the study time intervals. These results are consistent with the study of Athanasiou et al. [31] in which more bone formation was found in the bovine xenograft group compared to the DBM group in experimental defects, which was created in the rabbit's lateral femoral condyle. Bigham et al. [32] declared the superior effect of xenograft to DBM group on bone formation based on radiological union. The less bone maturation in the DBM group in comparison to the control group might be the surprising part of this study. According to the authors' belief, the thick periosteal layer of rabbit calvaria, which was carefully sutured during wound closure, may have acted as a natural barrier membrane to induce guided tissue regeneration in the control experimental defects and enhance bone formation. However, the severe inflammation response which possibly concludes to delayed bone formation and/or lower rate of ossification, might be the main reason for less bone maturation in the DBM group. We found less lamellar bone in the DBM than the Bio-Oss® group. Its extrapolated from an in vitro study; the presence of macrophages in combination with blood could not enhance chondrogenesis [27]. According to the authors state, contrary to Bio-Oss, the applied DBM was in putty shape, so there was no spaces through this bone substitute material for vascular and osteogenic ingrowths that could have resulted in less bone formation and maturation. The presence of macrophage cells and severe inflammation due to host reaction could hamper bone maturation in the DBM group too. In the present study, thickness of the lamellar bone formed in the Bio-Oss-grafted sites was greater than the DBM group, although no statistically significant difference was found. These results are consistent with

the previous studies, which have shown Bio-Oss has a proper potential for bone formation [27, 28]. The porosity and particle shape of Bio-Oss could increase the surface area, which makes Bio-Oss a suitable scaffold for penetration of the cells mediating osteogenesis and angiogenesis [27]. However, the bone healing properties of Bio-Oss® were supported and superior when compared to the control or autogenous graft when examined in human maxillary sinusⁱⁱ. Perhaps the biomaterial bone grafts are more effective in the human especially when used in larger defect sizes or critical size defects. On the contrary to our study, DBM osteoinductive property has been confirmed by several studies while others showed it to have bone formation properties following extra-skeletal implantation [34-39]. Rabie et al [19] reported increased osteogenic properties of a composite of autogenous and DBM when compared to autogenous grafts using human DBM and rabbit DBM (allogeneic demineralized bone matrix). Marusic et al [40] concluded bone induction with DBM in thymectomized rats to be significantly more than non-thymectomized rats (95% vs. 25%). Furthermore, Wang and Glimcher [41] showed that bovine DBM-induced bone formation in the rat's cranial defects were less than allogeneic DBM. It has determined the true critical size defect in the rabbit model as 15mm; therefore, three critical size defects cannot be created in the rabbit cranium due to the small size of cranium [42]. Although lamellar bone regeneration will continue until four postoperative months or 12 weeks, others suggested 8 weeks in this regard as studied in the present study [43-46]. Callan et al. (2000) reported that the extensive new bone formation and minimal residual bone graft matrix would be observed at an average of 5 months postoperatively [44]. The authors' expectations regarding the higher bone maturation rate of DBM compared to Bio-Oss did not turn out to be correct; perhaps the study time intervals, the experimental de-

fect size, the number of the samples and different source and shape of the examined material (allograft putty versus xenograft granules) have been influential. However, the rabbit is a suitable animal for experimental studies and it is commonly used for medical research. Some of its advantages are that it is easily handled and the cranial defects provide a good first phase bone model for experiments related to bone grafting materials and evaluations of bone regeneration due to the sufficient amount of bone marrow facilitating bone formation [45-47]. Moreover, the rabbit has a larger cranium, which makes it feasible to create several defects in one cranium, which reduces operation time, cost and observational errors among individuals. The remodeling phase in the rabbit is about three times more rapid than in humans; therefore, a healing period of 2 to 4 weeks was considered appropriate to evaluate the stability of the material and the host reaction and 8 weeks or more may be used to assess late healing, such as bone incorporation, resorption of materials, bone remodeling or the amount of bone regeneration [48, 49].

CONCLUSION

As shown by the present study, Accell Connexus® has a lower rate of ossification and bone healing in comparison to the control and Bio-Oss®, although no significant differences were found.

ACKNOWLEDGMENTS

The authors would like to thank Dr. Mohammad Mehdi Dehghan, for animal testing and his contribution to the study.

REFERENCES

- 1- Bauer TW, Muschler GF. Bone graft materials. An overview of the basic science. *Clin Orthop Relat Res.* 2000 Feb;371:10-27.
- 2- Schallhorn R. Present status of osseous grafting procedures. *J Periodontol.* 1977 Sep;48(9):570-6.
- 3- Thaller SR, Hoyt J, Bonjeson K, Dart A, Tesluk H. Reconstruction of calvarial defects with anorganic bovine bone mineral (Bio-Oss) in a rabbit model. *J Craniofac Surg.* 1993 Apr;4(2):79-84.
- 4- Jensen SS, Aaboe M, Pinholt EM, Hjørting-Hansen E, Melsen F, Ruyter IE. Tissue reaction and material characteristics of four bone substitutes. *Int J Oral Maxillofac Implants.* 1996 Jan-Feb;11(1):55-66.
- 5- Sculean A, Chiantella GC, Arweiler NB, Becker J, Schwarz F, Stavropoulos A. Five-year clinical and histologic results following treatment of human intrabony defects with an enamel matrix derivative combined with a natural bone mineral. *Int J Periodontics Restorative Dent.* 2008 Apr;28(2):153-61.
- 6- Berglundh T, Linhe J. Healing around implants placed in bone defects treated with Bio-Oss. An experimental study in the Dog. *Clin Oral Implants Res.* 1997 Apr;8(2):117-24.
- 7- John HD, Wenz B. Histomorphometric analysis of natural bone mineral for maxillary sinus augmentation. *Int J Oral Maxillofac Implants.* 2004 Mar-Apr;19(2):199-207.
- 8- Tadjoedin ES, de Lange GL, Bronckers A, Lyaruu DM, Burger EH. Deproteinized cancellous bovine bone (Bio-Oss) as bone substitute for sinus floor elevation. A retrospective, histomorphometrical study of five cases. *J Clin Periodontol.* 2003 Mar;30(3):261-70.
- 9- Armand S, Kirsch A, Sergent C, Kemoun P, Brunel G. Radiographic and histologic evaluation of a sinus augmentation with composite bone graft: A clinical case report. *J Periodontol.* 2002 Sep;73(9):1082-8.
- 10- Carmagnola D, Adriaens P, Berglundh T. Healing of human extraction sockets filled with Bio-Oss®. *Clin Oral Implants Res.* 2003 Apr;14(2):137-43.
- 11- Sclar A. Ridge preservation for optimum esthetics and function: The Bio-Col technique. *Supplement to the Compendium* 1999;6:1.
- 12- Norton MR, Odell EW, Thompson ID, Cook RJ. Efficacy of bovine bone mineral for

- alveolar augmentation: a human histologic study. *Clin Oral Implants Res.* 2003 Dec;14(6):775-83.
- 13- Zitzmann NU, Scharer P, Marinello CP, Schupach P, Berglundh T. Alveolar ridge augmentation with Bio-Oss®: a histologic study in humans. *Int J Periodontics Restorative Dent.* 2001 Jun;21(3):289-94.
- 14- Perrott DH, Smith RA, Sharma AB, McArdle L. Maxillary and mandibular reconstruction in preparation for endosseous implants. *J Calif Dent Assoc.* 1993 May;21(5):39-43.
- 15- Rokn A, Ghahroudi AR, Hemati S, Soolari A. Comparison of peri-implant bone loss and survival of maxillary intrasinus and extrasinus implants after 2 years. *J Dent (Tehran).* 2011 Summer;8(3):130-7.
- 16- Tapety FI, Amizuka N, Uoshima K, Nomura S, Meada T. A histological evaluation of the involvement of Bio-Oss® in osteoblastic differentiation and matrix synthesis. *Clin Oral Implants Res.* 2004 Jun;15(3):315-24.
- 17- Dinopoulous HT, Giannoudis PV. Safety and efficacy of use of demineralised bone matrix in orthopaedic and trauma surgery. *Expert Opin Drug Saf.* 2006 Nov;5(6):847-66.
- 18- Gao J, Knaack D, Goldberg VM, Caplan AI. Osteochondral defect repair by demineralized cortical bone matrix. *Clin Orthop Relat Res.* 2004 Oct;(427Suppl):S62-66.
- 19- Rabie AB, Wong RW, Hagg U. Composite autogenous bone and demineralized bone matrices used to repair defects in the parietal bone of rabbits. *Br J Oral Maxillofac Surg.* 2000 Oct;38(5):565-70.
- 20- Lee YP, Jo M, Luna M, Chien B, Lieberman JR, Wang JC. The efficacy of different commercially available demineralized bone matrix substances in an athymic rat model. *J Spinal Disord Tech.* 2005 Oct;18(5):439-44.
- 21- Peterson B, Whang PG, Iglesias R, Wang JC, Lieberman JR. Osteoinductivity of commercially available demineralized bone matrix. Preparations in a spine fusion model. *J Bone Joint Surg Am.* 2004 Oct;86-A(10):2243-50.
- 22- Sampath TK, Reddi AH. Importance of geometry of the extracellular matrix in endochondral bone differentiation. *J Cell Biol.* 1984 Jun;98(6):2192-97.
- 23- Hollinger JO, Winn SR, Hu Y. Assembling a bone regeneration therapy. In: Davies JE, editor. *Bone engineering.* Toronto: em squared; 2000. p. 435-40.
- 24- <http://www.integralife.com/orthobiologics>
- 25- Urist MR, Strates BS. Bone formation in implants of partially and wholly demineralized bone matrix. Including observations on acetone-fixed intra and extra cellular proteins. *Clin Orthop Relat Res.* 1970;71:271-8.
- 26- Develioglu H, Saraydin SU, Dupoirieux L, Sahin ZD. Histological findings of long-term healing of the experimental defects by application of a synthetic biphasic ceramic in rats. *J Biomed Mater Res A.* 2007 Feb;80(2):505-8.
- 27- Fuerst G, Tangl S, Gruber R, Gahleitner A, Sanroman F, Watzek G. Bone formation following sinus grafting with autogenous bone derived bone derived cells and bovine bone mineral in minipigs: preliminary findings. *Clin Oral Implants Res.* 2004 Dec;15(6):733-40.
- 28- Iezzi G, Scarano A, Mangano C, Cirotti B, Piattelli A. Histologic results from a human implant retrieved due to fracture 5 years after insertion in a sinus augmented with anorganic bovine bone. *J Periodontol.* 2008 Jan;79(1):192-8.
- 29- van Osch GJ, Ten Koppel PG, van der Veen SW, Popper P, Burger EH, Verwoerd-Verhoef HL. The role of trabecular demineralized bone in combination with perichondrium in the generation of cartilage grafts. *Biomaterials.* 1999 Feb;20(3):233-40.
- 30- Agnol RD, Carvalho MB, Rapoport A, Galvao Silva MA. Induction of osteogenesis by demineralized homologous and xenograft bone matrix. *Acta Cir Bras.* 2003;18(3):124-7.
- 31- Athanasiou VT, Papachristou DJ, Panagopoulos A, Saridis A, Scopa CD, Megas

- P. Histological comparison of autograft, allograft-DBM, xenograft, and synthetic grafts in a trabecular bone defect: an experimental study in rabbits. *Med SciMonit.* 2010 Jan;16(1):BR24-31.
- 32- Bigham AS, Dehghani SN, Shafiei Z, Nezhad ST. Experimental bone defect healing with xenogenic demineralized bone matrix and bovine fetal growth plate as a new xenograft: radiological, histopathological and biomechanical evaluation. *Cell Tissue Bank.* 2009 Feb;10(1):33-41.
- 33- Yilidirim M, Spiekermann H, Handt S, Edelhoff D. Maxillary sinus augmentation with the xenograft Bio-Oss and autogenous intraoral bone for qualitative improvement of the implant site: a histologic and histomorphometric clinical study in humans. *Int J Oral Maxillofac Implants.* 2001 Jan-Feb;16:23-33.
- 34- Lu M, Rabie AB. The effect of demineralized intra-membranous bone matrix and basic fibroblastic growth factor on the healing of allogeneic intra-membranous bone graft in the rabbit. *Arch Oral Biol.* 2002 Dec;47(12):831-41.
- 35- Gao J, Knaack D, Goldberg VM, Caplan AI. Osteochondral defect repair by demineralized cortical bone matrix. *ClinOrthopRelat Res.* 2004 Oct;(427Suppl):S62-6.
- 36- Moghadam HG, Sándor GK, Holmes HH, Clokie CM. Histomorphometric evaluation of bone regeneration using allogeneic and alloplastic bone substitutes. *J Oral Maxillofac Surg.* 2004 Feb;62(2):202-13.
- 37- Bender SAB, Bender SA, Rogalski JB, Mills MP, Arnold RM, Cochran DL, Mellonig JT. Evaluation of demineralized bone matrix paste and putty in periodontal intra-osseous defects. *J Periodontol* 2005 May;76(5):768-77.
- 38- Urist MR. Bone: formation by autoinduction. *Science* 1965 Nov 12;150(3698):893-9.
- 39- Vandersteenhoven JJ, Spector M. Histological investigation of bone induction by demineralized allogeneic bone matrix: a natural biomaterial for osseous reconstruction. *J Biomed Mater Res.* 1983 Nov;17(6):1003-14.
- 40- Marusic A, Dikic J, Vukicevic S, Marusi M. New bone induction by demineralized bone matrix in immune-suppressed rats. *Experientia* 1992 Aug 15;48(8):783-85.
- 41- Wang J, Glimcher MJ. Characterization of matrix-induced osteogenesis in rat calvarial bone defects: I. Differences in the cellular response to demineralized bone matrix implanted in calvarial defects and in subcutaneous sites. *Calcif Tissue Int.* 1999 Aug;65(2):156-65.
- 42- Vikjaer D, Blom S, Hjorting-Hansen E, Pinholt EM. Effect of platelet-derived growth factor-BB on bone formation in calvarial defects: an experimental study in rabbits. *Eur J Oral Sci.* 1997 Feb;105(1):59-66.
- 43- Hansen A, Pruss A, Gollnick H, Bochentin B, Denner K, Von Versen R. Demineralized bone matrix-stimulated bone regeneration in rats enhanced by an angiogenic dipeptide derivative. *Cell Tissue Bank.* 2001;2(2):69-75.
- 44- Callan DP, Salkeld SL, Scarborough N. Histologic analysis of implant sites after grafting with demineralized bone matrix putty and sheets. *Implant Dent.* 2000;9(1):36-44.
- 45- Newman E, Turner AS, Wark JD. The potential of sheep for the study of osteopenia: current status and comparison with other animal models. *Bone.* 1995 Apr;16(4 Suppl):277S-284S.
- 46- Castaneda S, Largo R, Calvo E, Rodríguez-Salvanés F, Marcos ME, Díaz-Curiel Met al. Bone mineral measurements of subchondral and trabecular bone in healthy and osteoporotic rabbits. *Skeletal Radiol.* 2006 Jan;35(1):34-41.
- 47- Rokn AR, Khodadoostan MA, Reza Rasouli Ghahroudi AA, Motahary P, Kharrazi Fard MJ, Bruyn HD et al. Bone formation with two types of grafting materials: a histologic and histomorphometric study. *Open Dent J.* 2011; 5:96-104.

48- Torres J, Tamimi FM, Tresguerres IF, Alkhraisat MH, Khraisat A, Lopez-Cabarcos E et al. Effect of solely applied platelet-rich plasma on osseous regeneration compared to Bio-Oss: a morphometric and densitometric study on rabbit calvaria. *Clin Implant Dent*

Relat Res. 2008 May;10(2):106-12.

49- Sohn JY, Park JC, Um YJ, Jung UW, Kim CS, Cho KSet al. Spontaneous healing capacity of rabbit cranial defects of various sizes. *J Periodontal Implant Sci.* 2010 Aug;40(4):180-87.