

Evaluation of the Effect of Plasma Rich in Growth Factors (PRGF) on Bone Regeneration

M. Paknejad^{1,2}, Y. Soleymani Shayesteh³, S. Yaghobee^{4✉}, S. Shariat⁵, M. Dehghan⁶, P. Motahari⁷

¹Assistant Professor, Dental Research Center, Tehran University of Medical Sciences, Tehran, Iran

²Associated Professor, Department of Periodontics, Dental Faculty of Tehran University of Medical Sciences, Tehran, Iran

³Associated Professor, Department of Periodontics, Dental Faculty of Tehran University of Medical Sciences, Tehran, Iran

⁴Assistant Professor, Department of Periodontics, Dental Faculty of Tehran University of Medical Sciences, Tehran, Iran

⁵Periodontist

⁶Assistant Professor, Department of Veterinary, Tehran University of Medical Sciences, Tehran, Iran

⁷Assistant Professor, Department of Maxillofacial Pathology, Dental Faculty of Tehran University of Medical Sciences, Tehran, Iran

Abstract

Objective: Reconstruction methods are an essential prerequisite for functional rehabilitation of the stomatognathic system. Plasma rich in growth factors (PRGF) offers a new and potentially useful adjunct to bone substitute materials in bone reconstructive surgery. This study was carried out to investigate the influence of PRGF and fibrin membrane on regeneration of bony defects with and without deproteinized bovine bone mineral (DBBM) on rabbit calvaria.

Materials and Methods: Twelve New Zealand white rabbits were included in this randomized, blinded, prospective study. Four equal 3.3×6.6 mm cranial bone defects were created and immediately grafted with DBBM, PRGF+DBBM, PRGF+fibrin membrane and no treatment as control. The defects were evaluated with histologic and histomorphometric analysis performed 4 and 8 weeks later.

Results: Adding PRGF to DBBM led to increased bone formation as compared with the control group in 4- and 8-week intervals. In DBBM and PRGF+fibrin membrane samples, no significant increase was seen compared to the control group. There was also a significant increase in the rate of biodegradation of DBBM particles with the addition of PRGF in the 8-week interval. Neither noticeable foreign body reaction nor any severe inflammation was seen in each of the specimens evaluated.

Conclusion: Under the limitation of this study, adding PRGF to DBBM enhanced osteogenesis in rabbit calvarias. Applying autologous fibrin membrane in the defects was not helpful.

Key Words : Graft; Bone disease; Fibrin; Membrane

✉ Corresponding author:
S. Yaghobee, Department of Periodontics, Dental School of Tehran University of Medical Sciences, Tehran, Iran
s_yaghobee@yahoo.com

Received: 13 December 2011

Accepted: 21 January 2012

Journal of Dentistry, Tehran University of Medical Sciences, Tehran, Iran (2012; Vol. 9, No.1)

INTRODUCTION

Autogenous bone grafts from intra- and extra-oral donor sites, as a gold standard, are used to regenerate bony defects in craniofacial surgeries [1]. Donor morbidity and lack of available sources related to autogenous bone may lead

to use bone substitutes [2]. Applying platelet-rich plasma (PRP) suggested a potentially beneficial adjunct to autogenous, allogeneic and xenogeneic materials in bone and implant reconstructive surgery.

Some studies have indicated a capability of

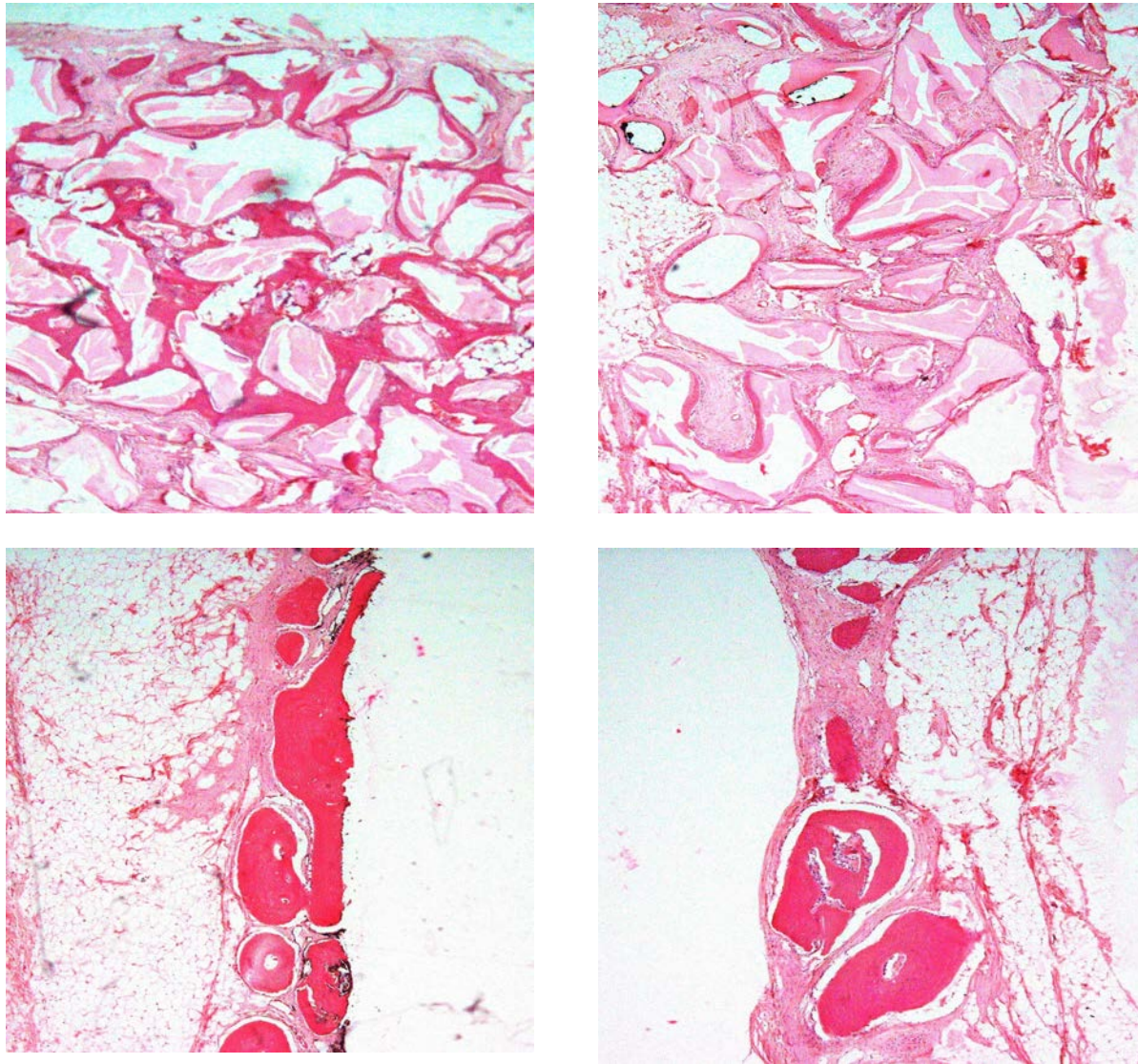


Fig 1. Hematoxylin and eosin stained photomicrographs of the experimental groups at 40× magnification at 4 weeks. DMMB (A), DMMB+PRGF (B), PRGF+fibrin membrane (C), Control group (D)

PRP to promote bone regeneration [3]. On the contrary, some investigators have demonstrated no benefit or even negative effect on bone regeneration with PRP [4].

A new technique to prepare platelet concentrate is Plasma Rich in Growth Factors (PRGF) System. Among the advantages of this system is the fact that it is less time consuming, does not require bovine thromboplastine for activation, needs less venous blood, the product is devoid of white blood cells and inflammatory interleukins and centrifugation

may be performed in one step. In addition, it prepares both PRGF and fibrin membrane at the same time [5].

Platelets release different wound healing growth factors and cytokines such as transforming growth factors (TGF- β), platelet-derived growth factor (PDGF), vascular endothelial growth factor (VEGF), epithelial cell growth factor (EGF), basic fibroblast growth factor (bFGF) and platelet activating factor-4 (PAF-4). The mentioned growth factors are considered to have a role in bone regeneration,

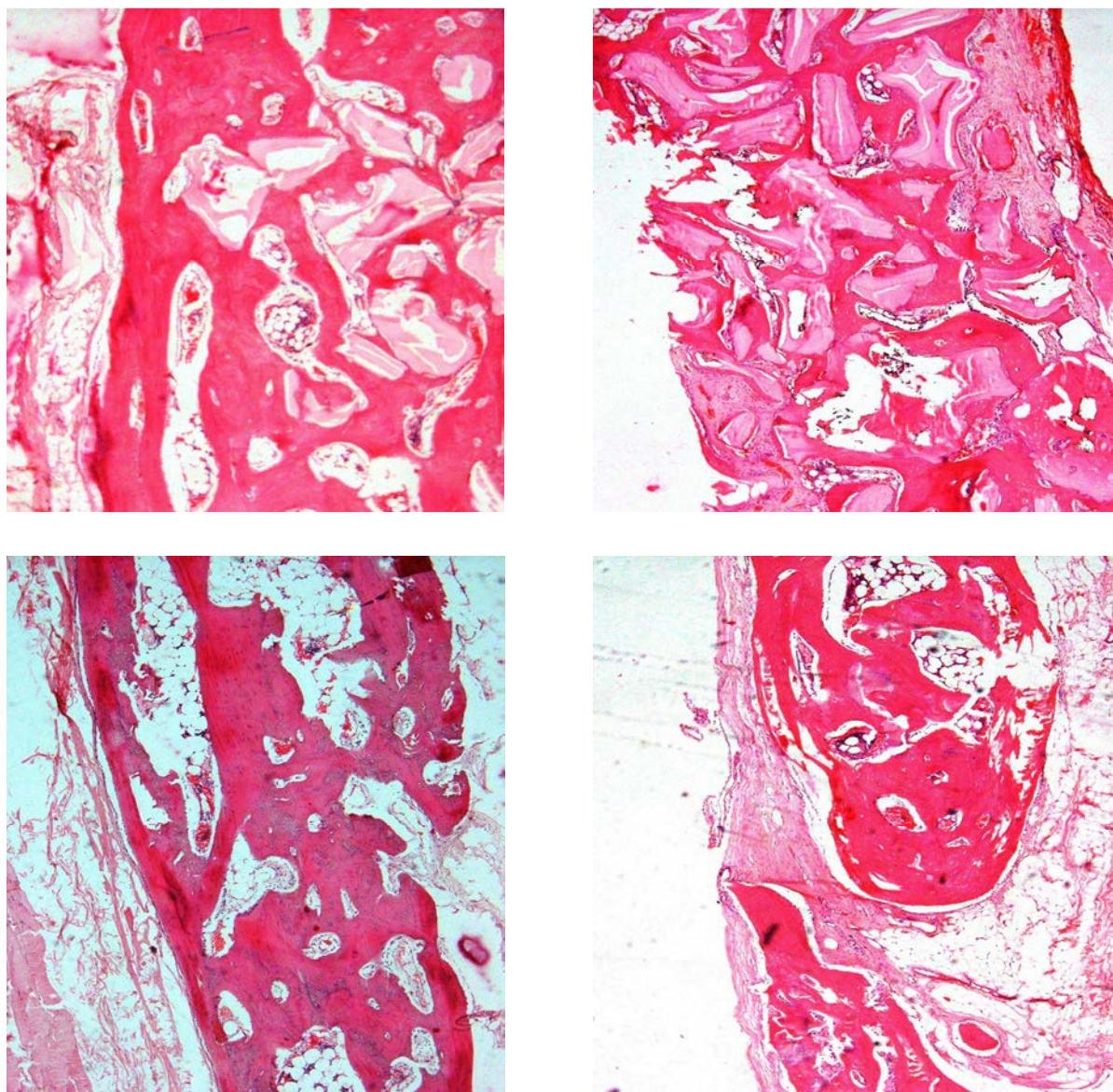


Fig 2. Hematoxylin and eosin stained photomicrographs of the experimental groups at 40× magnification at 8 weeks. DMMB (A), DMMB+PRGF (B), PRGF+fibrin membrane (C), Control group (D)

increased vascularity and the process of wound healing [6,7].

The objective of the present study was to investigate the effectiveness of PRGF as a new method of obtaining platelet concentrate and autologous fibrin membrane on bone healing with and without utilizing deproteinized bovine bone mineral (DBBM) in experimental calvarial defects in rabbits.

MATERIALS AND METHODS

Preparation of PRGF and Fibrin membrane

Twelve 2.5 to 3 kg weighted New Zealand white male rabbits were selected for this randomized, blinded prospective study.

The study protocol was first approved by Tehran university of Medical Science ethics committee.

Intramuscular injection of mixed ketamin 10 % (40 mg/kg) and Xylazin 2% (5mg/kg)

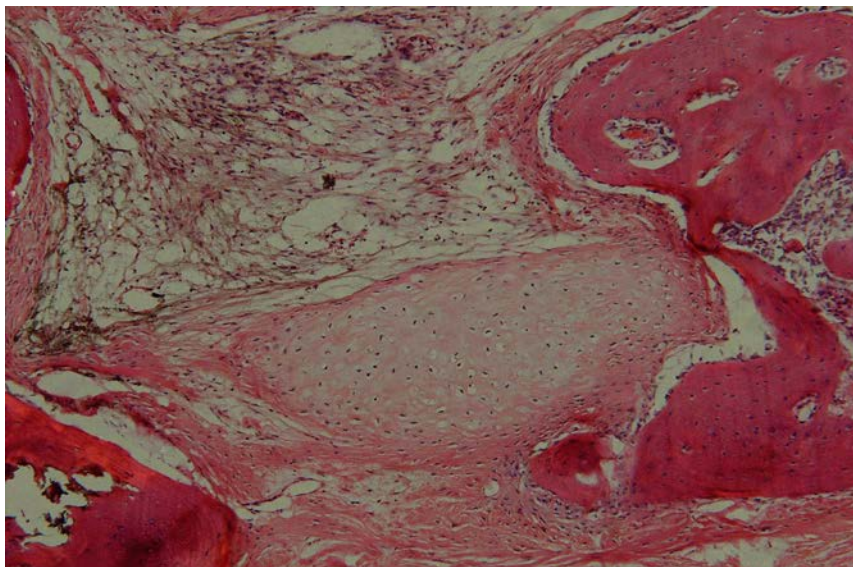


Fig 3. A photomicrograph showing chondroplasia in one sample of PRGF+fibrin group

(Alafason, Woden – Holland) were applied for anesthetizing each rabbit. 5ml of autologous blood drawn from each rabbit was combined with 0.5 ml of anticoagulant sodium citrate. The blood was centrifuged at 1400 rpm for 8 minutes by PRGF system (Biothecnology institute, San Antonio, Spain). The plasma that was drawn off the top, consists of 3 fractions. The topmost layer (fraction 1) was used to prepare fibrin membrane. The middle layer (fraction 2) was used as a carrier for DBBM. The bottom layer (fraction 3) was used in one of the defects in each rabbit along with the fibrin membrane.

Fraction 1 and fraction 3 were each poured with 500 ml pipettes into the test tube. Fraction 2 was poured with a 100 ml pipette into small plates containing 30 mg DBBM (Bio-Oss, Geistlich and sons, Wolhusen, Switzerland).

To jellify, 50 ml calcium chloride was added to each fraction which were then placed in plasma term device for 15 minutes.

Surgical procedure

For each animal, the cranium was shaved, scrubbed with 7.5 % povidine iodine and draped in a sterile fashion. Surgical procedure

Table 1. Mean and Standard Deviation of the Percentage of Newly Regenerated Bone and Remaining Biomaterial Particles in Each Study Group at Different Time Intervals

Time	Study Group	Regenerated Bone	Remaining DBBM Particles
4 weeks	PRGF+DBBM	19.12 ± 5.93	43.08 ± 11.08
	DBBM	13.38 ± 3.57	52.23 ± 6.62
	PRGF+fibrin membrane	10.45 ± 5.07	-
	Control	9.14 ± 4.12	-
8 weeks	PRGF+DBBM	27.27 ± 1.78	32.90 ± 3.16
	DBBM	24.36 ± 8.34	36.37 ± 6.17
	PRGF+fibrin membrane	18.95 ± 1.27	-
	Control	15.66 ± 6.18	-

followed a coronal-sagittal approach, the periosteum was dissected and four identical bone defects (3.3×6.6 mm) were created with a round bur in the frontal and parietal bones distanced 2mm from the sagittal and coronal sutures. The defects were randomly filled with DBBM, DBBM + PRGF, PRGF+ fibrin membrane and one defect was left unfilled to serve as the control defect. The wound was carefully closed with sutures and a postoperative antibiotic (enrofloxacin 0.6 mg/day) [Razak, Karaj- Iran] and a narcotic calmativ (ketoprofen 0.1 mg/day)[Alafason, Woden-Holland] was administered for 5 days subcutaneously.

Sample preparation

Rabbits were euthanized using sodium thiopental (SANDOZ, Kundl, Austria), 100 mg/kg intravenously at 4 and 8 weeks, 6 rabbits in each group. The entire cranium was removed and after fixation in formalin, specimens were treated with 10 % formic acid decalcifying solution. They were then dehydrated with alcohol and embedded in paraffin. Histologic sections (5 mm thickness) were prepared perpendicular to the long axis of each defect with an anterior to posterior direction. 20 sections of each defect were provided. The specimens were stained with hemotoxylin and eosin (H & E).

Sample evaluation

Magnified micrographs 400× (Olympus BX51, Olympus Co, Tokyo, Japan) were used for assessment of foreign body reaction as defined by giant cells and concomitant granulomatous reaction. The same magnification was also used to assess the interface between bone and biomaterial particles. Polarized light microscopy was used to determine the proportion of lamellar and woven trabeculae in each specimen. Concentrically aligned collagen bundles in the bony trabecules were interpreted as lamellar bone, whereas irregularly oriented collagen fibers in the trabeculae were documented as woven bone.

Magnified photomicrographs 40× (Olympus BX51, Olympus Co, Tokyo, Japan) were used (Figs 1 and 2) for computing the histomorphometric bone and biomaterial areas using graphics software (Photoshop 8 CS., Adobe Photoshop CS). Areas including newly regenerated bone were selected according to their similar color properties.

The pixel counts of these areas were calculated and divided by the total number of pixels of each photomicrographs. The same procedure was used for calculating the histomorphometric area of remaining biomaterials. Evaluations were blinded with regard to use of PRGF and also the time period for each sample.

Table 2. Comparison of the Amount of Newly Regenerated Bone and Remaining Biomaterial Particles Between Different Study Groups at 4 and 8 Weeks

Time	Variable	Bone Percentage	Biomaterial Percentage
4 weeks	PRGF+DBBM/DBBM	-	-
	PRGF+DBBM/PRGF+Fibrin	*	-
	PRGF+DBBM/Control	*	-
	DBBM/PRGF+Fibrin	-	-
	DBBM/Control	-	-
	PRGF+Fibrin/Control	-	-
8 Weeks	PRGF+DBBM/DBBM	-	*
	PRGF+DBBM/PRGF+Fibrin	-	-
	PRGF+DBBM/Control	*	-
	DBBM/PRGF+Fibrin	-	-
	DBBM/Control	-	-
	PRGF+Fibrin/Control	-	-

*Statistical significance in % 95 confidence interval

Statistical analysis

Statistical analysis included Kruskal-Wallis and Dunn procedure for qualitative variables and ANOVA with Post-Hoc for quantitative variables using SPSS software.

RESULTS

Histologic evaluation

Foreign body reaction was seen in five samples. It was limited around resorbable sutures in the periosteum. In addition, direct bone biomaterial contact without intervening connective tissue was seen whenever new bone formation occurred in DBBM (+PRGF) groups. Polarized light microscopy showed no statistically significant differences between the groups. The samples without any inflammation were significantly more common in PRGF+fibrin and control group at 4 weeks ($p=0.023$). One interesting finding was chondrogenesis in one sample of PRGF+fibrin group considered as metaplasia (Fig 3).

Histomorphometric evaluation

The descriptive statistics of histomorphometric data from all the four evaluated groups are shown in Table 1. Figure 3 shows the histomorphometric bone area as a function of time for each of the study groups. DBBM+PRGF showed statistically significant increase in the amount of regenerated bone over PRGF+fibrin ($p=0.024$) and the control groups ($p=0.008$) at 4 weeks and over the control group ($p=0.011$) at 8 weeks. DBBM+PRGF showed a greater rate of biomaterial degradation in comparison with DBBM alone at 8 weeks ($p=0.047$) (Table 1). Table 2 shows the data which were significant.

DISCUSSION

Many studies in oral and maxillofacial surgery consecutively attempt to improve the existing bone-grafting techniques in order to yield a faster, denser bone regeneration. Growth factors are an accurate way to improve bone and

soft tissue healing. Platelets have a physiologic supply of vascular endothelial growth factor (VEGF), which may be released when platelets are stimulated, secreted or aggregated by collagen. It has been demonstrated that TGF- β 2 and TGF- β 1 stop bone resorption as well as trigger rapid maturation of collagen in the early wound [8]. PDGF increases the population of wound healing cells and recruits other angiogenic growth factors to the wound site [2]. PRGF is a new system used for obtaining platelets and plasma proteins and has unique advantages such as saving time, needing less venous blood, the fact that centrifugation may be carried in a single step and it does not need bovine thromboplastine for activation [5]. In addition, this system prepares fibrin membrane that may be used as an autologous membrane for guided tissue regeneration (GTR) [9]. The investigations on PRGF and fibrin membrane are limited and further studies are necessary in this field. In the fields of skin wound healing, repair of damaged tendon and cartilage, satisfactory results have been obtained [10,11].

In the present study, the combined effects of using PRGF and a xenograft (DBBM) in treating non-critical sized rabbit cranial defects were evaluated. Histological assessment revealed that adding PRGF to DBBM did not affect its biocompatibility. These results are similar to the studies previously performed on PRP [12,13].

A slight inflammation was seen in groups having DBBM at 4 weeks. This may be explained by the presence of particulate material, although bio-compatible in the site.

Microscopic assessment with polarized light showed that by increasing time, trabecular bone maturation (from woven bone to lamellar bone) occurs in all experimental groups, but the difference between groups was not significant. In contrast, Marx et al. reported a significant increase in the proportion of mature bony trabeculae 4 months after using autogenous bone graft with PRP [3]. Fundamental differ-

ences between autogenous bone and xenografts and also different study periods could be the reason for such a discrepancy between the results.

Histomorphometric evaluation of the amount of the newly regenerated bone showed that adding PRGF to DBBM caused a significant increase in bone formation at 4 weeks in comparison to PRGF+fibrin membrane and control groups. At 8 weeks the difference was still significant compared to the control group. These findings are in accordance with other studies performed on PRP [4,14]. Nonetheless, in this study placing DBBM alone in the defects could not increase bone formation significantly in comparison to the control group ($p=0.054$). It seems this difference could be significant with a larger sample size.

Histomorphometric evaluation showed that PRGF significantly increased the rate of degradation of the biomaterial at 8 weeks. Replacement of bovine bone mineral with natural bone appeared to be a slow process [13]; therefore, later findings could be important.

In this study, application of fibrin membrane had no additional effect on bone formation compared to the control group. This may be as a result of premature degradation of the fibrin membrane which consequently results in collapse of the periosteum into the defects. So fibrin membrane does not have the potential to preserve space for bone regeneration as opposed to collagen membrane which was considered effective in some animal studies [15].

The growth factors secreted by platelets bind to the external surface of cell membranes of the cells in the graft, flap, or wound via transmembrane receptors. Mesenchymal stem cells and osteoblasts are major brands of cells that express these receptors. Using platelet concentrates in conjunction with various grafting materials accelerates recruitment of osteoblasts and mesenchymal cells to the grafted area which leads to accelerated cellular proliferation, matrix formation, osteoid and collagen

production. Additionally, it can be postulated that platelet concentrates such as PRGF cause an accelerated remodeling process, in which osteoclasts arrive at the grafted area more quickly and invade DBBM particles more effectively [3]. This phenomenon could be expressed as continuous and accelerated reduction in the histomorphometric area of remaining biomaterial particles, which was seen in the present study (Table 1).

It seems that the results of this study on PRGF are comparable to another study that was previously carried out on PRP in Tehran university [16]. In the present study, there were just 12 specimens and six rabbits were sacrificed in time periods of 4 and 8 weeks, so osteogenesis in long term could not be evaluated. On the other hand, a true critical-sized cranial defect in the rabbit model is 15 mm [17]. Therefore, four critical-sized defects could not be created in the rabbit cranium due to the small size of the cranium.

A non-critical sized defect was chosen to evaluate the early healing and the potential ability of PRGF to improve early healing when it was added to DBBM particles and the efficacy of autologous fibrin membrane. In another animal study which was performed on dog, PRGF was applied on implants before insertion and after 4 weeks a histomorphometric evaluation was done on the specimens.

There was no statistically significant differences between the test and control group regarding the type of newly formed bone [18]. These results were not in accordance to our study, maybe because the PRGF has been used directly on the implants and there was not any media as carrier and of course the time of sampling was not similar.

CONCLUSION

Within the limitation of this study, it can be concluded that PRGF provides additional benefits when used along with xenogeneic bone substitute (DBBM with the trade name of Bio-

Oss) for bone regeneration in rabbit cranial defects, increasing the speed of bone regeneration (until the eighth week of healing) and the rate of biomaterial degradation at 8 weeks. No additional benefits were found in applying autologous fibrin membrane plus PRGF without biomaterial as compared to the control group.

ACKNOWLEDGMENTS

This research was supported by Dental Research Center of Tehran University of Medical Sciences. The authors report no conflicts of interest related to this study.

REFERENCES

- 1-Nkenke E, Schultze-Mosgau S, Radespiel-Trager M, Kloss F, Neukam FW. Morbidity of harvesting of chin grafts: a prospective study. *Clin Oral Implants Res* 2001 Oct;12(5):495-502.
- 2-Lynch SE, Genco RJ, Max RE. Tissue engineering: application in maxillofacial surgery and periodontics. Surrey: Quintessence publishing Co; 1999.
- 3-Marx RE. Platelet-rich plasma: evidence to support its use. *J Oral Maxillofac Surg* 2004 Apr;62(4):489-96.
- 4-Aghaloo TL, Moy PK, Freymiller EG. Investigation of platelet rich plasma in rabbit cranial defects: A pilot study. *J Oral Maxillofac Surg* 2002 Oct;60(10):1176-81.
- 5-Anitua E, Andia I, Sanchez M. Plasma rich in growth factor. *Dental Dialogue* 2004: 3.
- 6-Weibrich G, Kleis WK, Hafner G, Hitzler WE, Wagner W. Comparison of platelet, leucocyte, and growth factor levels in point-of-care platelet-enriched plasma, prepared a modified Curasan kit, with preparation received from a local blood bank. *Clin Oral Implants Res* 2003 Jun;14(3):357-62.
- 7-Sanchez AR, Sheridan PJ, Kupp LI. Is platelet-rich plasma the perfect enhancement factor? A current review. *Int J Oral Maxillofac Implants* 2003 Jan-Feb;18(1):93-103.
- 8-Maloney JP, Silliman CC, Ambruso DR, Wang J, Tuder RM, Voelkel NF. In vitro release of vascular endothelial growth factor during platelet aggregation. *Am J Physiol* 1998 Sep;275(3 Pt 2):H1054-61.
- 9-Anitua E, Olive G, Andia I. use of PRGF to accelerate bone and soft tissue regeneration in post extraction sites. *Dental Dialogue* 2006; 1.
- 10-Sanchez M, Azorfa J, Anitua E, Andía I, Padilla S, Santisteban J, Mujika I. Plasma rich in growth factors to treat an articular cartilage avulsion: a case report. *Med Sci Sports Exerc* 2003 Oct;35(10):1648-52.
- 11-Sanchez M, Anitua E, Azorfa J, Andia I, Padilla S, Mujika I. Comparision of surgically repair achillus tendon tears using platelet-rich matrices. *J Am J Sports Med* 2007 Feb;35(2):245-51.
- 12-Donos N, Bosshardt D, Lang N, Graziani F, Tonetti M, Karring T, Kostopoulos L. Bone formation by enamel matrix proteins and xenografts: an experimental study in the rat ramus. *Clin Oral Implants Res* 2005 Apr;16(2):140-6.
- 13-Berglundh T, Lindhe J. Healing around implants placed in bone defects treating with Bio-Oss. An experimental study in the dog. *Clin Oral Implants Res* 1997 Apr;8(2):117-24.
- 14-Wiltfang J, Schlegel KA, Schutze- Mosgau S, Nkenke E, Zimmermann R, Kessler P. Sinus floor augmentation with beta-tricalcium phosphate: does platelet-rich plasma promote its osseous integration and degradation? *Clin Oral Implant Res* 2003 Apr;14(2):213-8.
- 15-Hammerle CH, Chintella GC, Karring T, Lang NP. The effects of a deproteinized bovine bone mineral on bone regeneration around titanium dental implants. *Clin Oral Implants Res* 1998 Jun;9(3):151-62.
- 16-Shayesteh YS, Shafiee MA, Khorsand A, Dehghan M. Evaluation of platelet-rich plasma in combination with deproteinized bovine bone mineral in the rabbit cranium. *Perio* 2006;4(3):1-9.

17-Vikjaer D, Blom S, Hgorting-Hansen E, Pinholt EM. Effect of platelet-derived growth factor-BB on bone formation in calvarial defects: an experimental study in rabbits. *Eur J Oral Sci* 1997 Feb;105(1):59-66.

18-Birang R, Torabi A, Shahabooei M, Rismanchian M. Effect of plasma-rich in platelet-derived growth factors on peri-implant bone healing: An experimental study in canines. *Dent Res J (Isfahan)* 2012 Jan;9(1):93-9.