

# Effect of Dietary Vitamin C on Orthodontic Tooth Movement in Rats

Amirfarhang Miresmaeili<sup>1</sup>, Najmeh Mollaei<sup>2</sup>, Ramin Azar<sup>3</sup>, Nasrin Farhadian<sup>4✉</sup>, Khosrou Mani Kashani<sup>5</sup>

<sup>1</sup>Associate Professor, Department of Orthodontics, Dental Research Center, Faculty of Dentistry, Hamadan University of Medical Sciences, Hamadan, Iran

<sup>2</sup>Postgraduate Student, Department of Orthodontics, Faculty of Dentistry, Hamadan University of Medical Sciences, Hamadan, Iran

<sup>3</sup>Orthodontist, Private Practice, Tehran, Iran

<sup>4</sup>Professor, Department of Orthodontics, Faculty of Dentistry, Hamadan University of Medical Sciences, Hamadan, Iran

<sup>5</sup>Biostatistician, Hamadan, Iran

## Abstract

**Objectives:** Bone remodeling occurs during orthodontic treatment; this process enables tooth movement. Many factors can affect bone remodeling at the cellular level, such as nutritional supplements that can affect tooth movement. The present study was designed to evaluate the effect of dietary vitamin C on orthodontic tooth movement in rats.

**Materials and Methods:** This study was carried out on 36 six-week male Wistar rats with a mean weight of  $225 \pm 32$  g, which were randomly allocated to two equal groups. Rats in the case group received 1wt% vitamin C in their daily water. Opening springs were placed on the incisor teeth of both case and control groups. After 17 days, rats were sacrificed; the distance between the mesio-incisal angles of these teeth was measured with a digital caliper. Histological sections were made containing incisor teeth and alveolar bone and stained by hematoxylin-eosin. The number of resorption lacunae was evaluated using light microscopy.

**Results:** Our findings showed that the amount of tooth movement in the vitamin C group was significantly higher than that in the control group ( $P < 0.001$ ). The osteoclast counts were significantly higher in vitamin C group ( $P = 0.036$ ).

**Conclusion:** Oral vitamin C can increase orthodontic tooth movement in rats with more osteoclast lacunae around root in the pressure area.

**Key words:** Ascorbic Acid; Orthodontics; Tooth Movement; Osteoclasts; Bone Remodeling

*Journal of Dentistry, Tehran University of Medical Sciences, Tehran, Iran (2015; Vol. 12, No. 6)*

✉ Corresponding author:

N. Farhadian, Department of Orthodontics, Faculty of Dentistry, Hamadan University of Medical Sciences, Hamadan, Iran

Nasrinne@yahoo.com

Received: 16 January 2015

Accepted: 7 April 2015

## INTRODUCTION

Bone remodeling occurring during orthodontic treatment is a process that enables movement of teeth with their surrounding supporting tis-

sue. Factors affecting the cellular process of bone resorption and remodeling may increase or decrease tooth movement [1]. Orthodontic forces can increase secondary messengers in-

side the cells, which are critical for osteoblastic differentiation [2,3] and tooth movement [4,5]. The critical role of ascorbic acid (vitamin C) in osteoclast stimulation in cell culture media has been confirmed in several investigations [6,7]. Lack of vitamin C halts osteogenesis and periodontal ligament organization [8,9]. It has been shown that vitamin C deficiency during orthodontic treatment reduces the tooth movement because of its effect on tissue healing. Its main effect is on the periodontal ligament (PDL). Ascorbic acid deficiency inhibits degradation and regeneration of collagen fibers, which are important in orthodontic tooth movement [9,10]. Ascorbic acid increases the longevity and proliferation of osteoclasts and their progenitor cells [11]. Human body cannot synthesize vitamin C [12]. Normal plasma concentration of vitamin C varies from 36.1 to 79.4  $\mu\text{mol/L}$  [13]. Vitamin C blood level in orthodontic patients is 17% to 75% lower than the desired level [14,15]. Vitamin C supplements are available over the counter. The present study was designed to evaluate the effect of vitamin C dietary supplementation on orthodontic tooth movement in rats.

## MATERIALS AND METHODS

Sample size was determined based on the following formula. A minimum of 32 subjects was found to be adequate. Because of possible dropouts during the study, 36 rats were included.

$$n = \frac{(Z_{1-\alpha/2} + Z_{1-\beta})^2 \times (\sigma_1^2 + \sigma_2^2)}{(\mu_1 - \mu_2)^2}, \sigma_1^2 = 4.13, \sigma_2^2 = 69.36, \mu_1 =$$

$$1.85, \mu_2 = 10.56$$

The data for  $\mu$  and  $\sigma$  were derived from Litton's study [9]. This study was carried out on 36 six-week old male Wistar rats weighting 200-250 g, which were randomly allocated to two equal groups. All rats had intact incisors with normal interproximal contact and were kept in cages at a temperature of 25°C and humidity of 55% in alternating 12-hour peri-

ods of light and dark for seven days to accommodate with the new conditions. Rats with a diastema between their incisor teeth were excluded. The control group did not receive any supplemental vitamin C.

The diet of the case group contained 1wt% vitamin C [L(+)-Ascorbic acid, Acros Organics, Geel, Belgium] which was added to their water supply seven days before spring placement to provide the desired blood level at the onset of tooth movement and this level was maintained until the end of the study. The study was designed and performed according to the international guiding principles for biomedical research involving animals [16] and approved by the Research Center of Hamadan University of Medical Sciences (code #16/35/2785). Rats were anesthetized with an intra-peritoneal injection of ketamine (50mg/Kg) on the seventh day and pre-activated open springs were bonded on the maxillary incisor teeth (3 mm far from the incisal edge) using a self-etch bonding system (Transbond Plus, 3M Unitek, Monrovia, CA, USA) and flowable light-cure composite resin (Heliomolar Flow, Ivoclar Vivadent, Liechtenstein) in both the case and control groups to produce 30 g of opening force calibrated by a gauge (Fig. 1). Springs were made of 0.35 mm stainless steel wire and consisted of two 8 mm arms and a 1.5 turn helix in the middle. Rats were sacrificed by ether overdose on day 17 after bonding the spring. The distance from the mesio-incisal angle of the right incisor to that of the left incisor at the time of spring removal was measured by an expert orthodontist using Boley digital gauge (Digital caliper, Mitutoyo, Aurora, USA). Then the premaxilla was dissected, placed in fixative solution for 10 days (FineFix, Milestone, Fatebenefratelli, Italy) and then in %10 nitric acid for two days. Transverse sections with 3-5 $\mu$  thickness were made using a microtome (RM 2135, Leica, Nussloch, Germany) at the coronal level of alveolar bone. The best section in each sample was stained with hematoxylin-eosin.

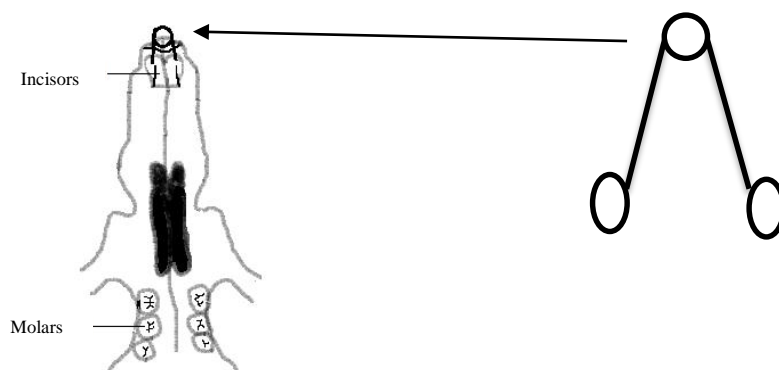


Fig. 1. Opening spring and its adjustment on rat's incisor teeth

Number of resorption lacunae in a standard field ( $1 \times 2$  mm) at the distal aspect of the incisor root (pressure side) was counted by an expert pathologist using light microscopy at  $\times 100$  magnification. Histological sections were re-measured one week later. Bland-Altman plot was applied to assess the reproducibility, and no significant differences were found between the first and second measurements. The Kolmogorov-Smirnov test was used to assess the normal distribution of data, and homogeneity of variance was evaluated using Levene's test. T-test was also used for data analysis.  $P < 0.05$  was considered statistically significant.

## RESULTS

None of the samples were excluded from the study. Table 1 shows that the amount of movement in vitamin C group was significantly higher than that in the control group ( $P < 0.001$ ).

Osteoclast count in each group is summarized in Table 2 and it was also significantly higher in the case group ( $P < 0.04$ ).

## DISCUSSION

A variety of factors may affect orthodontic tooth movement such as prostaglandins, progesterone, cAMP, IL- $\beta$ 1 (mediators), calcium, nitric oxide and other neurotransmitters that have been evaluated by many studies [1,4,5,17,18].

Vitamin C, commercially available in the form of a dietary supplement, is known as an important factor in bone remodeling and collagen synthesis [19] and its deficiency can cause complete arrest of osteogenesis, impair the organization of periodontal ligament and increase bone resorption [9,20].

Others have shown that vitamin C deficiency may result in lower orthodontic tooth movement via inhibition of collagen turn over [9,10,20].

Table 1. Space between the incisors in the case and control groups (mm)

Group	Number	Mean	Standard Deviation	Standard Error	P value
Control	18	2.96	0.34	0.07	0.001
Vitamin C	18	3.61	0.54	0.08	

Table 2. The number of resorption lacunae in the case and control groups

Group	Number	Mean	Standard deviation	P
Control	18	26.5	11.10	0.036
Vitamin C	18	36.68	14.91	

Our study demonstrated greater tooth movement and osteoclast lacunae in the experimental group who received oral vitamin C for 17 days. Litton performed a study on orthodontic tooth movement in animals with ascorbic acid deficiency and concluded that the most significant changes were observed in animals with ascorbic acid deficiency [9].

Mc Canlies et al. [20] evaluated the effect of vitamin C on the mobility and stability of incisors under the influence of orthodontic force in guinea pigs and found that the rate and the amount of separation were approximately the same in the three groups with orthodontic appliances (1 mg daily vitamin C / 0.25 mg daily vitamin C / 0 mg daily vitamin C). But after appliance removal, relapse in the latter two groups was more than in the former group.

The cellular process of osteoclast proliferation has been used as an important indicator to evaluate the extent of tooth movement [21,22]. Maximum osteoclast recruitment occurs 5-14 days after orthodontic force application [23]. On the other hand, tooth movement is a process involving bone resorption and apposition, and vitamin C can induce stem cells to differentiate into osteoblasts via the synthesis of type I collagen, interaction with integrins, activation of protein kinase pathway and phosphorylation of osteoblast-specific transcription factor [19]. Thus, it is expected that tension sites simultaneously experience osteoblastic activity. "Does this process lead to more stable tooth movement in presence of vitamin C?" Further studies are required to answer this question.

De Laurenzi et al, [24] in their study on cultured neuroectodermal cells found that ascorbic acid, in its physiological concentration, acts as a pro-oxidant and causes apoptosis of cells. Some studies reported decreased osteogenesis due to copper deficiency attributed to vitamin C intake [25,26]. According to the above-mentioned findings, it seems that more studies are warranted to better elucidate the long-term effects of vitamin C supplementa-

tion. Long-term efficacy of vitamin C supplementation to enhance orthodontic tooth movement and also the stability of tooth movement in this situation must be further investigated as well.

## CONCLUSION

Vitamin C supplementation increases orthodontic tooth movement in rats.

## REFERENCES

- 1- Davidovich Z, Shanfeld JL. Cyclic AMP in alveolar bone of orthodontically treated cats. *Arch Oral Biol.* 1975 Sep;20(9):567-74.
- 2- King GJ, Keeling SD, McCoy EA, Ward TH. Measuring dental drift and orthodontic tooth movement in response to various initial forces in adult rats. *Am J Orthod Dentofacial Orthop.* 1991 May;99(5):456-65.
- 3- Yamasaki. The role of cyclic AMP, calcium and prostaglandins in induction of Osteoclastic bone resorption in associated with experimental tooth movement. *J Dent Res.* 1983 Aug;62(8): 877-81.
- 4- Shirazi M, Nilforoushan D, Alghasi H, Dehpour AR. The role of nitric oxide in orthodontic tooth movement in rats. *Angle Orthod.* 2002 Jun;72(3):211-5.
- 5- Akin E, Gurton AU, Olmez H. Effect of nitric oxide in orthodontic tooth movement in rats. *Am J Orthod Dentofacial Orthop.* 2004 Nov;126(5):608-14.
- 6- Otsuka E, Kato Y, Hirose S, Hagiwara H. Role of ascorbic acid in the osteoclast formation: induction of osteoclast differentiation factor with formation of the extracellular collagen matrix. *Endocrinology.* 2000 Aug;141(8):3006-11.
- 7- Tsuneto M, Yamazaki H, Yoshino M, Yamada T, Hayashi S. Ascorbic acid promotes osteoclastogenesis from embryonic stem cells. *Biochem Biophys Res Commun.* 2005 Oct 7; 335(4):1239-46.
- 8- Iwami-Morimoto Y, Yamaguchi K, Tanne K. Influence of dietary n-3 polyunsaturated fatty acid on experimental tooth movement in

- rats. *Angle Orthod.* 1999 Aug;69(4):365-71.
- 9- Litton SF. Orthodontic tooth movement during an ascorbic acid deficiency. *Am J Orthod.* 1974 Mar;65(3):290-302.
- 10- Hickory W, Nanda R. Nutritional considerations in orthodontics. *Dent Clin North Am.* 1981 Jan;25(1):195-201.
- 11- Ragab AA, Lavish SA, Banks MA, Goldberg VM, Greenfield EM. Osteoclast differentiation requires ascorbic acid. *J Bone Miner Res.* 1998 Jun;13(6):970-7.
- 12- Cui J, Pan YH, Zhang Y, Jones G, Zhang S. Progressive pseudogenization: vitamin C synthesis and its loss in bats. *Mol Biol Evol.* 2011 Feb;28(2):1025-31.
13. Rutkowski M, Grzegorzczak K. Vitamin C in medicine: "normal concentration" in serum. *Pol Merkur Lekarski.* 1999 Jan;6(31):57-60.
- 14- Cheraskin E, Ringsdorf WM Jr. Biology of the orthodontic patient: II, lingual vitamin C test scores. *Angle Orthod.* 1969 Oct;39(4):324-5.
- 15- Cheraskin E, Ringsdorf WM Jr. Biology of the orthodontic patient: I, plasma ascorbic acid levels. *Angle Orthod.* 1969 Apr;39(2):137-8.
- 16- Bankowski Z. International guiding principles for biomedical research involving animals. 1985.
- 17- Poosti M, Basafa M, Eslami N. Progesterone effects on experimental tooth movement in rabbits. *J Calif Dent Assoc.* 2009 Jul;37(7):483-6.
- 18- Kale S, Kocaderli I, Atilla P, Asan E. Comparison of the effects of 1, 25 dihydroxycholecalciferol and Prostaglandin E2 on orthodontic tooth movement. *Am J Orthod Dentofacial Orthop.* 2004 May;125(5):607-14.
- 19- Ishikawa S, Iwasaki K, Komaki M, Ishikawa I. Role of ascorbic acid in periodontal ligament cell differentiation. *J Periodontol.* 2004 May;75(5):709-16.
- 20- McCanlies JM, Alexander CM, Robnett JH, Magness WB. Effect of vitamin C on the mobility and stability of guinea pig incisors under the influence of orthodontic force. *Angle Orthod.* 1961 Oct;31(4):257-263.
- 21- Bakdash MB, Zaki HA. The impact of diet and nutrition on periodontal health. *Northwest Dent.* 1978 Jan-Feb;57(1):5-14.
- 22- Mavragani M, Brudvik P, Selvig KA. Orthodontically Induced root and alveolar bone resorption: inhibitory effect of systemic doxycycline administration in rats. *Eur J Orthod.* 2005 Jun;27(3):215-25.
- 23- Kaku M, Kohno S, Kawata T, Fujita I, Tokimasa C, Tsutsui K, et al. Effects of vascular endothelial growth factor on osteoclast induction during tooth movement in mice. *J Dent Res.* 2001 Oct;80(10):1880-3.
- 24- De Laurenzi V, Melino G, Savini I, Annicchiarico-Petruzzelli M, Finazzi-Agrò A, Avigliano L. Cell death by oxidative stress and ascorbic acid regeneration in human neuroectodermal cell lines. *Eur J Cancer.* 1995; 31A(4):463-6.
- 25- Van den Berg GJ, Yu S, Lemmens AG, Beynen AC. Dietary ascorbic acid lowers the concentration of soluble copper in the small intestinal lumen of rats. *Br J Nutr.* 1994 May; 71(5):701-7.
- 26- Strause L, Saltman P, Glowacki J. The effect of deficiencies of manganese and copper on osteoinduction and on resorption of bone particles in rats. *Calcif Tissue Int.* 1987 Sep; 41(3):145-50.