

# Treatment of Symptomatic Geographic Tongue with Triamcinolone Acetonide Alone and in Combination with Retinoic Acid: A Randomized Clinical Trial

Shamsoulmolouk Najafi<sup>1,2</sup>, Narges Gholizadeh<sup>2✉</sup>, Elahe Akhavan Rezayat<sup>3</sup>, Mohammad Javad Kharrazifard<sup>4</sup>

<sup>1</sup>Assistant Professor, Dental Research Center, Dentistry Research Institute, Tehran University of Medical Sciences, Tehran, Iran; Department of Oral Medicine, School of Dentistry, International Campus, Tehran University of Medical Sciences, Tehran, Iran

<sup>2</sup>Assistant Professor, Dental Research Center, Dentistry Research Institute, Tehran University of Medical Sciences, Tehran, Iran; Department of Oral and Maxillofacial Disease, School of Dentistry, Tehran University of Medical Sciences, Tehran, Iran

<sup>3</sup>Dentist, Private practice

<sup>4</sup>Statistical Consultant, Dental Research Center, Dentistry Research Institute, Tehran University of Medical Sciences, Tehran, Iran

## Abstract

**Objectives:** Geographic tongue or migratory glossitis is an inflammatory disorder with unknown etiology. Considering the accompanied burning pain, taste dysfunction, and lack of definite cure, it is important to treat this condition symptomatically. The objective of the current study was to compare the efficacy of a combination of 0.05% retinoic acid and 0.1% triamcinolone acetonide with that of triamcinolone acetonide alone for treatment of symptomatic geographic tongue.

**Materials and Methods:** This randomized controlled double-blind clinical trial was performed on 28 patients with symptomatic geographic tongue, who were referred to two dental clinics. Participants were randomly divided into two groups and treated with triamcinolone alone or retinoic acid plus triamcinolone for 10 days. Patients were assessed for the level of pain, burning sensation and size of lesion at the beginning and at the end of the study. Participants were followed up for two months after cessation of treatment (at the end of each month). SPSS 11 was applied to compare the two therapeutic modalities.

**Results:** Twenty-eight participants with a mean age of 40 years were evaluated including Seven (25%) males and 21 (75%) females. There was a positive family history of geographic tongue in 21 patients. Despite the diminished pain and burning sensation as well as smaller size of lesions following treatment ( $P < 0.05$ ), no statistically significant differences were found between the two groups ( $P > 0.05$ ). No side effect was reported.

**Conclusions:** The combination of triamcinolone and retinoic acid was not more effective than triamcinolone alone for symptomatic treatment of geographic tongue.

**Keywords:** Geographic Tongue and Fissured Tongue; Triamcinolone Acetonide; Retinoic acid

*Journal of Dentistry, Tehran University of Medical Sciences, Tehran, Iran (2016; Vol. 13, No. 1)*

✉ Corresponding author:  
N. Gholizadeh, Department of Oral and Maxillofacial Disease, Dental Research Center, Faculty of Dentistry, Tehran University of Medical Sciences, Tehran, Iran

n.gholizadeh88@gmail.com

Received: 17 July 2015

Accepted: 18 November 2015

## INTRODUCTION

Geographic tongue or benign migratory glossitis is defined as an inflammatory disorder with unknown etiology, characterized with a decrease in the number of papillae in the dorsum and lateral border of the tongue circumfusing with the formation of red, round patches with white distinct borders that give the tongue a map-like appearance. Changes in lesions almost occur on a daily basis. Its prevalence has been reported to be 2-3%. It seems that its distribution is equal in both males and females. Remission and relapse

are also seen over time [1].

Although the main etiology of geographic tongue remains unknown, some factors including emotional stress, vitamin deficiency, allergy, genetic factors, immune disorders, bacterial or fungal infection and systemic diseases are known to play a causative role. The lesions need to be treated in case of presence of pain, burning sensation, taste diminution, cancer phobia or aesthetic concerns [2]. There is not a definite cure for this condition. Topical steroids, retinoic acid, cyclosporine, antihistamine, tacrolimus and

immune system regulators have been used in proposed treatment plans, yet they are neither specific nor curative. They actually modulate inflammatory and immunological responses, which is their chief mechanism of action [3]. In a study by Abe et al, [4] a 54 year-old woman with painful geographic tongue failed to respond to therapy with 20mg of oral prednisolone and topical dexamethasone ointment on a daily basis. She was subsequently suspected for psoriasis, for which she received cyclosporine with favorable outcome [4]. Tacrolimus, a macrolide immune-suppressant with anti-inflammatory effects similar to cyclosporine with a mechanism of action of 1L2 inhibition, was proven successful in treating two patients with geographic tongue, who failed to respond to non-steroidal anti-inflammatory drugs and vitamin B12 [5]. Anita et al, [6] pointed to a number of symptomatic treatment options in their study in 2011, including oral hygiene maintenance, hydration, acetaminophen, local anesthetic mouthwash solution, anti-histamines, anxiolytics, corticosteroids, retinoic acids and cyclosporine. Helfman [7] supported retinoic acid solution and its efficacy for treating three cases of geographic tongue. Sigal and Mock [8] reported successful symptomatic treatment with local as well as systemic anti-histamines. Vahedi et al, [2] showed beneficial effects of topical zinc sulfate ointment for treatment of geographic tongue.

There is still no definitive cure for geographic tongue. Corticosteroids are considered effective among the available options. Triamcinolone acetonide is preferred over other corticosteroids since it contains sodium along with features similar to those of other corticosteroids [9,10]. Retinoic acid can stimulate immune response including macrophages' activity and cellular immune mechanisms [11]. Since both retinoic acid and topical corticosteroids have therapeutic and ameliorating effects on geographic tongue, the combination of the two may probably have a greater impact. We intended to assess the

efficacy of the combination of the two on geographic tongue. This can be a step forward towards the inclusion of this compound in the National Generic Pharma List, for a breakthrough in providing health and minimizing harm in affected patients.

## **MATERIALS AND METHODS**

This randomized controlled double blind clinical trial was conducted on 28 patients referred to Oral Disease Department of the Faculty of Dentistry, the International Campus of Tehran University of Medical Sciences and Razi Dermatology Hospital.

Twenty eight patients with symptomatic geographic tongue (confirmed by an oral disease specialist) who met the inclusion criteria and signed written informed consent form were included in this study. This study was approved by the Ethics Committee of Tehran University of Medical Sciences (130/2356/91) and registered in [www.irct.ir](http://www.irct.ir) (#201211062464n6). The patients were selected using the block randomization method and were divided into two groups of A and B with 14 patients in each group. The inclusion criteria were patients above 18 years old with symptomatic geographic tongue. Patients with a history of systemic or topical corticosteroid use for at least one month before treatment, smokers, pregnant women, those with any serious systemic disease that may interfere with the drugs such as diabetes mellitus, hypertension, heart disease, neurological problems, hepatitis, renal disease, chemotherapy and radiotherapy were excluded. The lesion was photographed before drug administration. Then, one modality was randomly prescribed for the participants. Patients were requested to apply 0.1% topical triamcinolone acetonide in an oral base or a combination of 0.05% retinoic acid and 0.1% triamcinolone acetonide in an oral base on their lesions.

Patients were also instructed to wash their mouth before the application of drugs and avoid eating

and drinking for at least 15 minutes. This therapy was done twice daily for 10 days. On day 10, patients were evaluated with regard to the lesion size, pain and burning and the lesions were then photographed again. Medications used in this study including 0.1% triamcinolone acetonide and the combined drugs (0.05% retinoic acid and 0.1% triamcinolone acetonide in an oral base) were prepared in the Medicinal Chemistry Department of Pharmacy School of Tehran University of Medical Sciences, Iran. Varying percentages of components were tested to achieve proper viscosity and maximum adhesion to oral mucosal lesions and the following proportions were favorable: pectin (16.5%), gelatin (16.5%), carboxymethyl cellulose (16.7%) and plasticized hydrocarbon gel (50.3%). Proper amounts of the afore-mentioned active substances were mixed and placed in tubes, labeled and kept at room temperature. Symptoms (pain and burning sensation) were assessed and recorded using the visual analog scale in a range of 0-100 [6]. Follow-up for detection of possible recurrence was done for two months after cessation of treatment (at the end of each month). The satisfactory outcomes were positive response to treatment and lesion's resolution with regard to size, level of pain and burning sensation. The healing process was

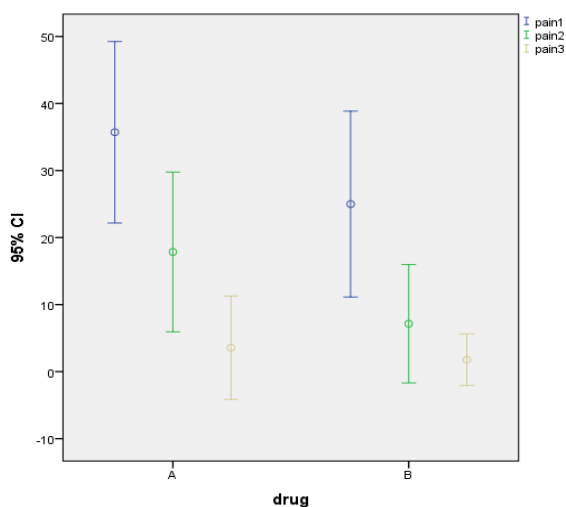
recorded as lesions shrank or disappeared within the shortest duration of time.

The resolution of pain and burning sensation was defined as reduction in their severity. Following complete response to treatment, the patients were followed up for two months for possible recurrence. The SPSS version 11 software was applied to compare the two therapeutic modalities. Qualitative variables were reported as relative frequency (in percentage) while quantitative variables were reported as mean and standard deviation. Fisher's exact test was used to compare the responses to treatment between the two groups and in order to compare the response time between the groups the Kaplan-Meier curve and log-rank test were used. Level of significance was set at  $P < 0.05$ .

## RESULTS

The study participants were 28 patients referred to Department of Oral Disease, Faculty of Dentistry, International Campus of Tehran University of Medical Sciences and Razi Dermatology Hospital including seven (25%) males and 21(75%) females.

There were 10 females (10.17%) and four males (4.71%) in the triamcinolone group and 11 females and three males (6.78%) in the combined drug group. With regard to their employment status, there were 11 (39.3%) housewives, 16 (1.57%) employees and one (3.6%) worker. With regard to the duration of the disease, 21 (75%) patients had the disease for less than six months and seven (25%) had the disease for more than six months. In terms of family history for the disease, 21(75%) had positive and seven (25%) had negative family history. The mean age was 40 years. At the beginning of the study, the severity of pain was not significantly different between the two groups ( $P=0.22$ ). Similarly, after 10 days of drug application, there was no significant difference in the severity of pain between the two groups ( $P=0.07$ ). One month after cessation, there was no statistically signifi-



**Fig. 1:** Comparison of changes in pain severity

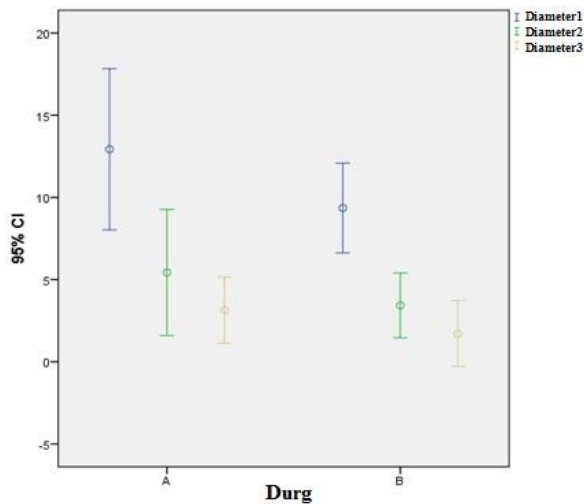


Fig. 2: Comparison of changes in the lesion's extension

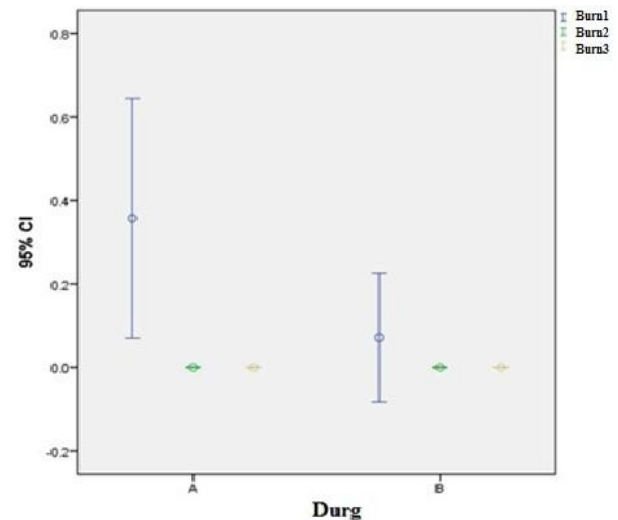


Fig. 3: Comparison of changes in burning sensation

cant difference in the severity of pain between the two groups ( $P=0.98$ ) (Fig.1). The comparison of pain severity throughout all three stages of the study revealed that pain decreased during the experiment.

At the beginning of the study, the extension of lesions was not significantly different between the groups ( $P=0.28$ ). Similarly, after 10 days of drug application there was no significant difference in this regard between the two groups ( $P=0.48$ ). One month after drug discontinuation, there was no statistically significant difference in the lesions' extension between the two groups (Fig. 2). Although differences in the severity of burning sensation were observed at different stages of the study indicative of a reduction in burning sensation during the experiment, there was no significant difference at different stages between the two groups (Fig. 3).

**DISCUSSION**

Geographic tongue, also known as benign migratory glossitis or benign transient plaque, usually starts with a decrease in the number of papillae on the lateral border and tip of the tongue, which are also redder and smoother than those in the other parts. These areas spread peripherally with the formation of red patches and well-circumscribed annuli that are delineated

with whitish-yellow borders, giving the tongue a map-like appearance.

It is not exclusive to a specific gender or race, and has an unknown etiology. The prevalence has been reported in a range of 1 to 2.5%, occurring in males and females equally [1]. In the current study, in which the efficacy of triamcinolone was compared with that of a combined regimen (triamcinolone acetonide and retinoic acid) in 28 patients with symptomatic geographic tongue, 75% of the participants were women and 25% were men while 75% of the patients had a positive family history for the disease.

The prevalence of geographic tongue was reported to be 7.8% in Zahedan by Honarmand et al, [12] in 2013, with a propensity towards female sex (4.1%) as opposed to male gender (3.7%). According to Miloglu et al, [13] hormonal factors may be involved in this gender predilection. In a study by Jahanbani et al, [14] in 2009 conducted in the School of Dentistry of Islamic Azad University of Tehran, geographic tongue was reported to occur more in the elderly (74.3%), in contrast to young patients (25.8%) with a higher prevalence in males (62.4%) than females (37.6%). The same findings were reported by Jankittivong and Langlais [15], in Thailand, with a ratio of 5:1 while Avcu and Kanli [16] reported an equal prevalence in both

genders. In the study by Vahedi et al, [2] in which the effect of zinc sulfate was investigated on patients with geographic tongue, 70% of participants were females versus 30% males, with a positive family history of the disease reported in 32% of the participants, which was lower than our obtained value. Regarding the role of genetic factors in the occurrence of geographic tongue Redman et al, [17] reported a high incidence of geographic tongue in first-degree relatives of the patients. In the study by Eidelman et al, [18] geographic tongue was described as a hereditary disease with a polygenetic nature, which was in line with our findings.

Difference in the severity of pain was observed in both groups in different stages of the experiment, representing pain reduction and recovery. A comparison between the stages revealed a significant pain reduction between stages one and two and also one and three while no difference was recorded between stages two and three.

Lesion size varied throughout the study at different stages, yet there was no statistically significant difference as to this variable between the two groups at the end of the study. Although difference in the severity of burning sensation was observed at different stages of the study (a reduction throughout the specified period), there was no significant difference at the various stages between the two groups. No adverse effects were reported, without any substantial statistical disparity in this respect. The two groups were not different regarding patient satisfaction either ( $P=0.75$ ). Recurrence of symptoms was not observed in any group. It can be concluded that the efficacy of the combination of retinoic acid and triamcinolone acetonide for symptomatic treatment of geographic tongue was similar to that of triamcinolone acetonide alone.

One of the advantages of the current study was the use of a combination of two drugs. Retinoic acid is a synthetic type of vitamin A with anti-inflammatory, anti-keratotic and immune-

regulatory features. Its anti-inflammatory components can inhibit macrophage and neutrophil infiltration through the blood vessels to the adjacent tissues (chemotaxis), can accelerate the healing process and decrease the risk of malignancy in epithelial cells. Retinoic acid plays a role in prevention of oral cancer and can cause regression of premalignant leukoplakia [1,11].

The combination of these two drugs can reduce inflammation via two different mechanisms: corticosteroids prevent the initiation of inflammatory cascade by inhibiting the enzyme release while retinoic acids interfere with arachidonic acid cascade, resulting in wound healing, angiogenesis stimulation and an increase in local blood flow [19,20]. On the other hand, the dose of corticosteroids is lower in drug combinations, and resultantly, their related complications decrease.

## CONCLUSION

The combination of triamcinolone and retinoic acid was not shown more effective than triamcinolone alone in treating geographic tongue symptomatically.

## ACKNOWLEDGEMENT

This article was financially supported by a grant from the International Campus of the Faculty of Dentistry, Tehran University of Medical Sciences.

## REFERENCES

- 1- Greenberg MS, Glick M, Ship JA. *Burkett's Oral Medicine: Diagnosis and Treatment*, 11<sup>th</sup> ed. Ontario, BC Decker Inc., 2008:107-112.
- 2- Vahedi M, Abdolsamadi HR, Mortazavi H, Abdollahzadeh SH. Evaluation of the Therapeutic Effects of Zinc Sulfate in Patients with Geographic Tongue. *Avicenna J Dent Res*. 2009;1(1):11-4.
- 3- Boorghani M, Gholizadeh N, Taghavi Zenouz A, Vatankhah M, Mehdipour M. Oral lichen planus: clinical features, etiology, treatment and management; a review of literature. *J Dent Res Dent Clin*

- Dent Prospects. 2010 Winter;4(1):3-9.
- 4- Abe M, Sogabe Y, Syuto T, Ishibuchi H, Yokoyama Y, Ishikawa O. Successful treatment with cyclosporin administration for persistent benign migratory glossitis. *J Dermatol*. 2007 May;34(5):340-3.
- 5- Ishibashi M, Tojo G, Watanabe M, Tamabuchi T, Masu T, Aiba S. Geographic tongue treated with topical tacrolimus. *J Dermatol Case Rep*. 2010 Dec 31;4(4):57-9.
- 6- Hooda A, Rathee M, Gulia J, Yadav S. Benign migratory glossitis: A review. *Internet J. Fam. Prac*. 2011;9(2):1
- 7-Helfman RJ. The treatment of geographic tongue with topical Retin- A solution. *Cutis*. 1979 Aug;24(2):179-80.
- 8- Sigal MJ, Mock D. Symptomatic benign migratory glossitis: report of two cases and literature review. *Pediatr Dent*. 1992 Nov-Dec;14(6):392-6.
- 9- Ferreira AO, Marinho RT, Velosa J, Costa JB. Geographic tongue and tenofovir. *BMJ Case Rep*. 2013 Apr17;2013.
- 10- Bertram G, Katzung, Susan B. Masters. Basic and clinical pharmacology. 12th Edition, Mc Graw Hill Co., 2012:655-57.
- 11- Sahebamee M, Amanlou M, Bakhshi M. Efficacy of topical retinoic acid compared with topical triamcinolone acetonide in the treatment of oral lichen planus. *Acta Med. Iran*. 2004;42:108-13.
- 12- Honarmand M1, Farhad Mollashahi L, Shirzaiy M, Sehatpour M. Geographic Tongue and Associated Risk Factors among Iranian Dental Patients. *Iran J Public Health*. 2013;42(2):215-9.
- 13- Miloğlu O, Göregen M, Akgül HM, Acemoğlu H. The prevalence and risk factors in 7619 Turkish dental out patients. *Oral Surg Oral Med Oral Pathol Oral Radiol Endod*. 2009 Feb;107(2):e29-33.
- 14- Jahanbani J, Sandvik L, Lyberg T, Ahlfors E. Evaluation of oral mucosal lesions in 598 referred Iranian patients. *Open Dent J*. 2009 Mar27;3:42-7.
- 15- Jainkittivong A, Langlais RP. Geographic tongue: clinical characteristics of 188 cases. *J Contemp Dent Pract*. 2005 Feb15;6(1):123-35.
- 16- Avcu N, Kanli A. The prevalence of tongue lesions in 5150 Turkish dental outpatients. *Oral Dis*. 2003 Jul;9(4):188-95.
- 17- Redman RS, Shapiro BL, Gorlin RJ. Hereditary component in the etiology of benign migratory glossitis. *Am J Hum Genet*. 1972 Mar;24(2):124-33.
- 18- Eidelman E, Chosack A, Cohen T. Scrotal tongue and geographic tongue: polygenic and associated traits. *Oral Surg Oral Med Oral Pathol*. 1976 Nov;42(5):591-6.
- 19- Samuelsson B. An elucidation of the arachidonic acid cascade. Discovery of prostaglandins, thromboxane and leukotrienes. *Drugs*. 1987;33 Suppl 1:2-9.
- 20- Tsala DE, Amadou D, Habtemariam S. Natural wound healing and bioactive natural products. *Phytopharmacology*. 2013;4(3):532-60.